

9-1-2021

## The feasibility and image quality of using soft embalming cadaver dogs and cats for radiographic and ultrasonographic training

Chutimon Thanaboonnipat

Nan Choisunirachon

Chalika Wangdee

Srireepong Kiertkrittikhoon

Voraphan Na Songkhla

*See next page for additional authors*

Follow this and additional works at: <https://digital.car.chula.ac.th/tjvm>



Part of the [Veterinary Medicine Commons](#)

---

### Recommended Citation

Thanaboonnipat, Chutimon; Choisunirachon, Nan; Wangdee, Chalika; Kiertkrittikhoon, Srireepong; Songkhla, Voraphan Na; Dhitavat, Sirakarnt; Chaichareonchon, Chanyaratt; Vimuktalop, Lampetch; and Komin, Kiatpichet (2021) "The feasibility and image quality of using soft embalming cadaver dogs and cats for radiographic and ultrasonographic training," *The Thai Journal of Veterinary Medicine*: Vol. 51: Iss. 3, Article 15.

Available at: <https://digital.car.chula.ac.th/tjvm/vol51/iss3/15>

This Article is brought to you for free and open access by the Chulalongkorn Journal Online (CUJO) at Chula Digital Collections. It has been accepted for inclusion in The Thai Journal of Veterinary Medicine by an authorized editor of Chula Digital Collections. For more information, please contact [ChulaDC@car.chula.ac.th](mailto:ChulaDC@car.chula.ac.th).

---

## The feasibility and image quality of using soft embalming cadaver dogs and cats for radiographic and ultrasonographic training

### Authors

Chutimon Thanaboonnipat, Nan Choisunirachon, Chalika Wangdee, Srireepong Kiertkritikhon, Voraphan Na Songkhla, Sirakarnt Dhitavat, Chanyaratt Chaichareonchon, Lampetch Vimuktalop, and Kiatpichet Komin

# The feasibility and image quality of using soft embalming cadaver dogs and cats for radiographic and ultrasonographic training

Chutimon Thanaboonipat<sup>1</sup> Nan Choisunirachon<sup>1</sup> Chalika Wangdee<sup>1</sup>

Srireepong Kiertkrittikhon<sup>1</sup> Voraphan Na Songkhla<sup>1</sup> Sirakarnt Dhitavat<sup>2</sup>

Chanyaratt Chaichareonchon<sup>1</sup> Lampetch Vimuktalop<sup>1</sup> Kiatpichet Komin<sup>1\*</sup>

## *Abstract*

Diagnostic imaging techniques, especially radiography and ultrasonography, have been applied as routine diagnostic tools in clinical practice of both human and veterinary medicine. Soft embalmed cadavers by Thiel's method is a new method for preserving dead bodies that has been increasingly used in medical education especially in diagnostic imaging fields. The aims of this study were, first, to examine the feasibility of using canine and feline soft cadavers in radiographic and ultrasonographic study and training. Second, to evaluate the procedure score and image quality score of radiography and ultrasonography using the soft cadaver dogs and cats as the model. All results were evaluated using questionnaires answered by veterinary graduate students in the major of diagnostic imaging. Six of each canine and feline soft embalming cadavers were used. Our results demonstrated that all students gave a highly satisfied score in all procedures of radiographic positioning. For the radiographic image quality, the thorax part in both canine and feline soft embalming cadavers was lowest compared to those of other parts. Moreover, all students gave a highly satisfied in all procedures of radiographic positioning. For abdominal ultrasound, all students preferred the image quality because the image quality was similar to live animals in almost all abdominal organs. However, vessels and lymph nodes were lowest scored in both species. In conclusion, soft embalming cadavers of dogs and cats by Thiel's embalming method is an efficient modality for teaching, learning and training in radiography and ultrasonography. This preserved method is very useful in veterinary anatomical education.

---

**Keywords:** Cadaver, Cat, Dog, Imaging training, Soft embalming

<sup>1</sup>Department of Veterinary Surgery, Faculty of Veterinary Science, Chulalongkorn University, Bangkok, Thailand

<sup>2</sup>Biochemistry Unit, Department of Veterinary Physiology, Faculty of Veterinary Science, Chulalongkorn University, Bangkok, Thailand

\*Correspondence: [kiatpichet.k@chula.ac.th](mailto:kiatpichet.k@chula.ac.th) (K. Komin)

Received March 6, 2021.

Accepted May 11, 2021.

doi: <https://doi.org/10.14456/tjvm.2021.65>

## Introduction

Diagnostic imaging techniques, especially radiography and ultrasonography, have been applied as routine diagnostic tools in clinical practice of both human and veterinary medicine. To increase the radiographic and ultrasonographic interpretation skills and operator confidence, the operators, trainee radiologists and veterinary students need more practice to build up their experience. Currently, the major issue of using live animals in study and research has been of high interest in public acceptance (Clark, 2017). The 3Rs of Replacement, Reduction and Refinement have been highly concerned and are involved as the fundamental concepts of using animals and alternatives in science study and research (Mandal and Parija, 2013; Clemence and Leaman, 2016). One of the Replacement methods which is using soft embalming animal cadavers instead of live animals in research has accomplished greater consistency and accuracy outcomes. Additionally, it is less costly than using live animals (Munirama *et al.*, 2016<sup>a</sup>; Clark, 2017).

Many human medical fields such as diagnostic imaging, forensic diagnostic imaging, surgery and anesthesia have studied the feasibility of using the soft embalmed Thiel cadaver model instead of fresh cadavers or live animals (Schnabl *et al.*, 2012; Baglivo *et al.*, 2013; Munirama *et al.*, 2016<sup>a</sup>; Clark, 2017; Portela *et al.*, 2017; Held *et al.*, 2019; Viscasillas *et al.*, 2019; Moon *et al.*, 2020). For example, the soft embalmed Thiel's human cadavers in training the intraneural injection (Munirama *et al.*, 2016<sup>a</sup>), sheep cadavers as a large animal model for experimental studies with middle and inner ear implantable hearing devices (Schnabl *et al.*, 2012), dog cadavers for training the ultrasound-guided posterior extraconal block (Viscasillas *et al.*, 2019) and paravertebral injection (Portela *et al.*, 2017). Several human studies using the soft embalmed Thiel cadaver model in training radiologists, practitioners and veterinary students have reported that this replacement method can enhance learning outcomes and also increase confidence in diagnostic imaging interpretation (Schnabl *et al.*, 2012; Portela *et al.*, 2017; Viscasillas *et al.*, 2019).

In veterinary medicine, the study of the feasibility of using soft embalming cadavers of dogs and cats in diagnostic imaging practice and learning is limited. Moreover, the radiographic and ultrasonographic image quality of soft cadaver models has not been previously reported. A few studies of serial postmortem thoracic and abdomen radiography in canine cadavers have been reported (Heng *et al.*, 2009<sup>a</sup>; Heng *et al.*, 2009<sup>b</sup>). Therefore, the aim of this study was to evaluate the procedure score, image quality score and feasibility of radiography and ultrasonography by using soft cadaver dogs and cats as the model in radiographic and ultrasonographic study and training.

## Materials and Methods

**Experimental design and animals:** This preliminary study was performed using dog and cat cadavers which were received from the clients/owners who donate their animal bodies for the purpose of veterinary studies and education to the Animal Cadaver Donation Center (ACDC), Faculty of

Veterinary Science, Chulalongkorn University during January 2019 to December 2020.

A total of 6 canine soft embalming cadavers and 6 feline soft embalming cadavers were included in this preliminary study. None of the included dogs and cats died from infectious diseases. The canine cadavers consisted of Poodle (2), Mixed breed (3), Pug (1) and the cat cadavers were Domestic shorthair (5) and Persia (1). The average ages of the dogs and cats were 10.33 and 5.33 years old, respectively.

**Embalming procedures:** The embalming solutions were prepared using soft embalmed Thiel's human cadavers as the model. The main ingredients of the soft embalmed solutions were sodium sulphite potassium nitrate, boric acid and water. All donated dog and cat cadavers were prepared by perfusing intravenously with approximately 1.5 L of soft embalming solution. After completing the embalming procedures, all dog and cat cadavers were sealed in a plastic bag and stored in a refrigerator at -20°C for a month. Before use in all procedures, all cadaveric dogs and cats were thawed at room temperature.

**Radiography:** All canine and feline soft cadavers had performed the standard radiography of whole-body radiograph including thorax, abdomen, skull, forelimb, hindlimb, pelvis and vertebrae. Positionings for each region were described as follows; thorax and abdomen radiographs, right lateral and ventrodorsal views; skull and vertebrae radiographs, lateral and dorsoventral views; forelimb and hindlimb parts, lateral and cranio-caudal views; pelvis, extended hip position of both lateral and ventrodorsal views. All radiographic images were obtained by direct digital radiography (ETL®, GE healthcare, Chicago, USA). The field of view (FOV) covered the area of interest of each part. Radiographic images were collected as the Digital Imaging and Communications in Medicine (DICOM) format. All radiographic images were positioned and interpreted by four graduate students in the major of diagnostic imaging with at least a year of diagnostic imaging experience and also performed under the supervision of experienced radiologists.

**B-Mode ultrasonography:** The ultrasonographic examinations were performed on manually restrained and positioned in ventrodorsal position during examination. Hair was clipped and acoustic gel was applied to the skin in preparation for the ultrasound procedure. B-mode ultrasonographic images were acquired using an ultrasonographic instrument (Logiq P6, GE healthcare, Chicago, USA) to examine all abdominal organs using the liner transducer with 9 MHz. All ultrasonographic images were performed by the graduate students that positioned and interpreted the radiographs under the supervision of experienced radiologists. All the ultrasonographic images were evaluated immediately at the scan time and then all graduate students performed the questionnaire. The abdominal ultrasonographic image among abdominal organs which are the liver, spleen, urinary organs (kidneys and urinary bladder), adrenal gland, pancreas, gastrointestinal organs (stomach, small intestine and large intestine), vessels and lymph nodes

of soft embalming cadaver dogs and cats were evaluated.

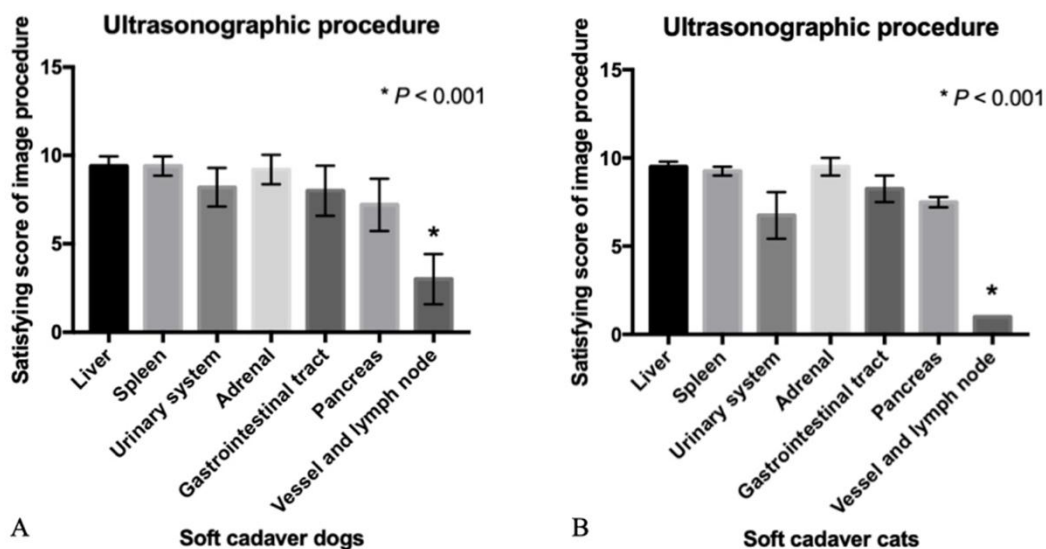
**Assessment of student response by questionnaire:** All evaluation results were obtained by a questionnaire. The questionnaire was prepared and distributed to graduate students after the completion of each procedure. The feasibility of radiographic and ultrasonographic procedure using soft embalming cadavers of dogs and cats was scored. Moreover, the quality of radiographic and ultrasonographic images acquired from soft embalming cadavers of dogs and cats was also evaluated by scoring the convenience in identifying each anatomical structure. The questions were regarding the satisfying degree of image quality of radiography and ultrasonography and overall satisfying degree of using the soft embalming cadavers of dogs and cats in radiographic positioning and ultrasonographic practice such as odor of the cadavers, ease in performing the radiographic positioning and ease in identifying the anatomical structures and overall preference for embalming solutions.

**Statistical analysis:** All data is presented as descriptive data. Data was expressed as mean ± standard errors of the mean (SEM) for each group. All statistical analyses were analyzed using Prism7 (GraphPad, USA). Prior to the statistical comparisons,

the normality of each data set was screened by Shapiro-Wilk test. The significance of the differences between the mean values of satisfy score was determined using Mann Whitney test and the difference among the mean values was determined by Kruskal-Wallis tests, followed by Dunn’s multiple comparison post hoc test for multiple comparisons. Statistical significance was considered if the P-value was less than 0.05.

### Results

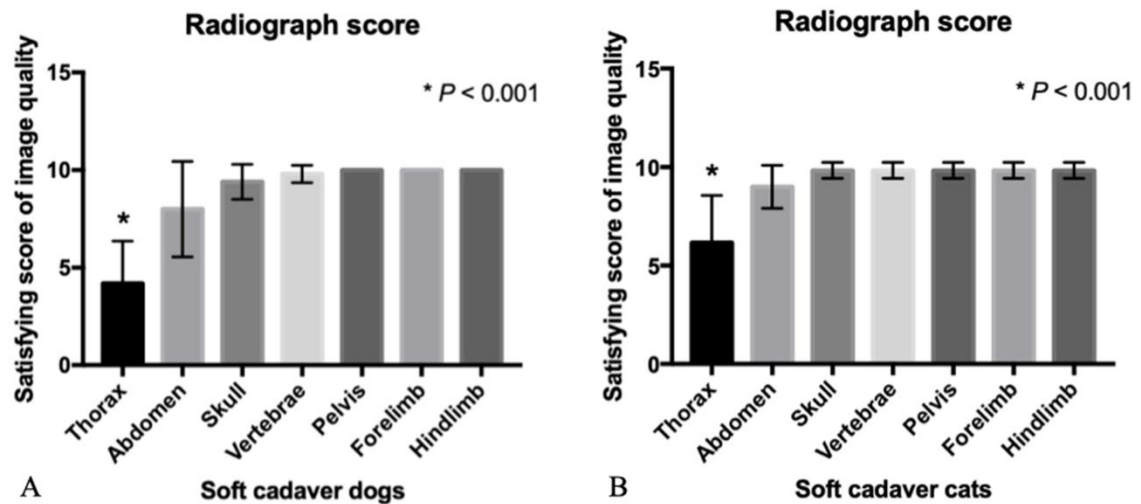
**The degree of satisfaction in using the soft embalming cadaver dogs and cats in radiographic positioning and ultrasonographic practice:** The results showed that the procedure score of radiography compared among body parts of embalming cadaver dogs and cats had no significant difference ( $P = 0.9876$ ; dogs and  $P = 0.1896$ ; cats). Ultrasonographically, the procedure comparing the abdominal organs which are liver, spleen, urinary organs (kidneys and urinary bladder), adrenal gland, pancreas, gastrointestinal organs (stomach, small intestine and large intestine), vessels and lymph nodes were significantly different ( $P < 0.001$ ). Both dog and cat soft embalming cadavers had significantly higher ultrasonographic procedure scores of liver, spleen, urinary organs, adrenal gland, pancreas and gastrointestinal organs than those of vessels and lymph nodes ( $P < 0.001$ ) (Fig. 1A and 1B).



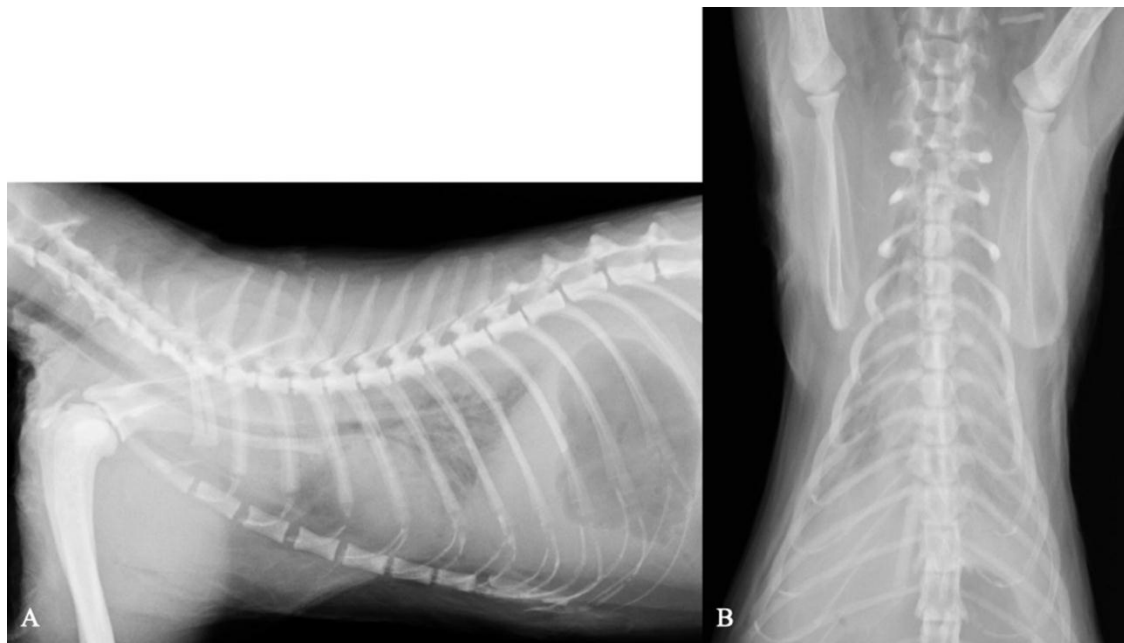**Figure 1** The satisfaction score of the ultrasonographic procedure acquired from soft embalming cadaver dogs (A) and cats (B).

**The degree of satisfaction in radiographic and ultrasonographic image quality using the soft embalming cadaver dogs and cats:** The results demonstrated that the radiographic image qualities comparing body parts which are thorax, abdomen, skull, forelimb, hindlimb, pelvis and vertebrae of both soft embalming cadaver dogs and cats were significantly different ( $P < 0.001$ ) in that, canine soft embalming cadavers and thorax radiographic quality

had a significantly lower score than those of other parts ( $P < 0.01$ ; thorax radiograph vs abdominal radiograph and  $P < 0.001$ ; thorax radiograph vs skull, forelimb, hindlimb, pelvis and vertebrae) (Fig. 2A). Similarly, the quality score of thoracic radiographs in feline embalming cadavers was also significantly less than those of other parts ( $P < 0.001$ ; thorax radiograph vs abdomen, skull, forelimb, hindlimb, pelvis and vertebrae) (Fig. 2B and Fig. 3).



**Figure 2** The satisfaction score of radiographic images acquired from soft embalming cadaver dogs (A) and cats (B).



**Figure 3** Thoracic radiographs of a soft embalming cadaver cat. Lateral view (A) and ventrodorsal view (B).

The results suggested that the ultrasonographic image qualities compared among locations of both soft embalming cadaver dogs and cats were significantly different ( $P < 0.001$ ). For the soft embalming cadaver dogs, almost all abdominal ultrasonographic image qualities including the liver, spleen, urinary organs, adrenal gland, pancreas, gastrointestinal organs had a significantly greater score than those of vessels and lymph nodes ( $P < 0.001$ ) (Fig. 4). The ultrasonographic

image qualities of liver, spleen, urinary organs, adrenal gland, gastrointestinal organs were also significantly higher score than those of the pancreas ( $P < 0.05$ ) (Fig. 5A). Similar to dogs, the quality scores of the liver, spleen, urinary organs, adrenal gland, pancreas and gastrointestinal organs in feline embalming cadavers were also significantly higher than those of vessels and lymph nodes ( $P < 0.001$ ) (Fig. 5B).

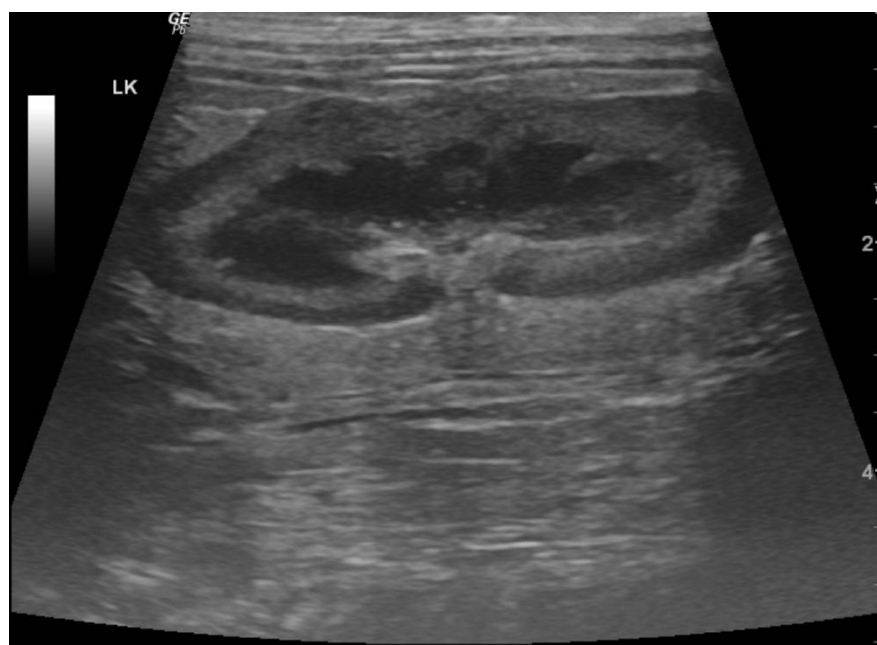

Figure 4 Renal ultrasonographic image of a soft embalming cadaver dog showing the unidentified renal vessel at renal hilus.

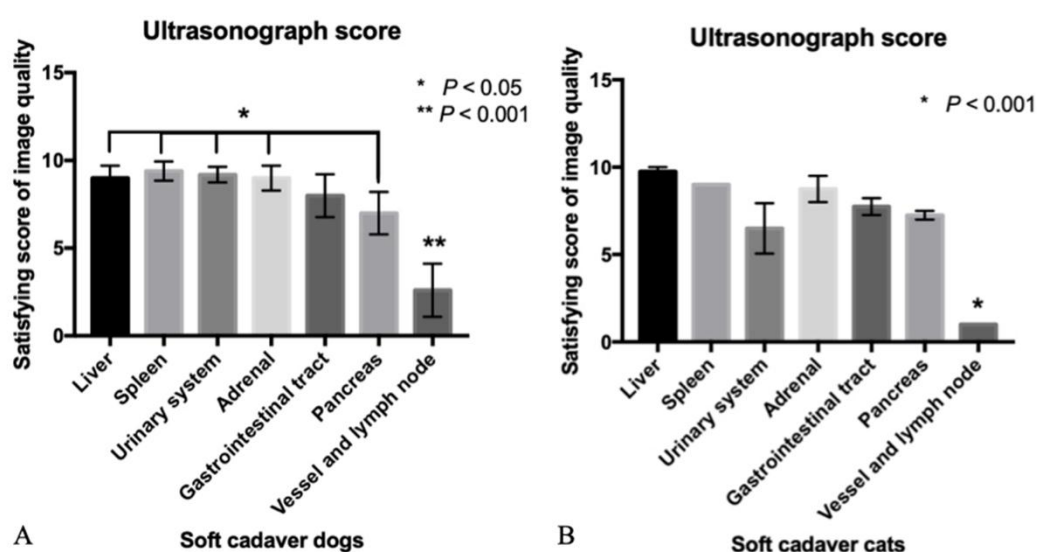


Figure 5 The satisfaction score of ultrasonographic images acquired from soft embalming cadaver dogs (A) and cats (B).

### Discussion

The soft embalmed Thiel’s human cadaver is a new development method for improving medical learning and creating a research model that has been increasingly used in human medical education (Thiel, 1992; Munirama *et al.*, 2016<sup>a</sup>). In humans, it has been reported that soft embalmed Thiel’s human cadaver has the full ability of joint movement as living people and may be used for 3 years (Benkhadra *et al.*, 2009; Eisma and Wilkinson, 2014). In diagnostic imaging fields, several studies have also demonstrated that skin and tissue of soft embalmed Thiel’s human cadaver are moist and soft and can be used as a good model in ultrasound practice. Additionally, the fascial integrity is still maintained that is beneficial in cytology and needle insertion training (McLeod *et al.*, 2010; Munirama *et al.*, 2012; Munirama *et al.*, 2016<sup>b</sup>).

Many human studies especially in diagnostic imaging fields have applied the soft embalmed Thiel’s method in preparing specimens to replace the use of live specimens or live animals as the 3Rs of Replacement, Reduction and Refinement guideline (Mandal and Parija, 2013; Clemence and Leaman, 2016; Clark, 2017). Replacement techniques usually enable the researchers to study and perform experiments which would not be performed in animal models (Clark, 2017). It has been reported that using soft embalming animal cadavers instead of live animals in research can accomplish greater consistency and accuracy outcomes. Moreover, this replacement method can reduce expense in preserving the specimens than live animals (Munirama *et al.*, 2016<sup>a</sup>; Clark, 2017).

In veterinary medicine, the use of soft embalming animal cadavers in research is limited. A recent study has reported the feasibility of using canine cadaver embalming methods for veterinary anatomy education (Nam *et al.*, 2020) by comparing three methods of dead body preservation which are the formalin-fixed method, the saturated salt solution method and Thiel's embalming method. The results of this previous study reported that students preferred the saturated salt solution method and Thiel's embalming method to the formalin-fixed method because these methods can preserve the texture and internal organs similar to those of live animals. Additionally, these methods also have superior usefulness in anatomical structure identification which can facilitate veterinary anatomical learning (Nam *et al.*, 2020). Our preliminary study is the first study using canine and feline soft cadavers preserved by Thiel's embalming method as the model in radiographic and ultrasonographic training and learning.

We found a satisfying degree of approval in using the soft embalming cadaver dogs and cats in radiographic positioning and ultrasonographic practice, all graduated students gave high scores in all procedures of radiographic positioning. While, in ultrasound practice procedure, vessels and lymph nodes also scored lowest in both soft cadaver dogs and cats in abdominal ultrasonographic image quality because vessels and lymph nodes were very small and merged into the peritoneal fat in cadavers and also no blood circulation as in live animals resulted in it being hard to identify and differentiate these structures in our study. The soft embalming cadaver dogs and cats provide more advantages in leaning and training the radiography and ultrasonography than the dog phantom. The soft embalming cadaver animals can represent the anatomical location and structure similar to live animals which is very useful in diagnostic imaging and anatomical education.

For the image quality score, the radiographic image quality of the thorax part in both canine and feline soft embalming cadavers was lowest compared to those of other parts because the lung is one of the main organs in the thoracic cavity that normally contains gas to process of gas exchange in living animals (George *et al.*, 2014). When the animal dies decomposition occurs continuously and causes body autolysis and putrefaction (Saukko and Knight *et al.*, 2004; Heng *et al.*, 2009). In our study, we preserved the dog and cat cadavers by the Thiel's embalming method to delay decomposition. However, non-functional lung will not contain the gas and expand as normal but lung parenchyma will collapse and cause increased radiopacity in the thoracic radiograph. Accordingly, the image quality of thoracic radiograph in cadaveric dogs and cats is poor compared to other parts.

For the abdominal ultrasonographic image qualities, all MS students preferred the image quality that resembled live animals. They gave a highly satisfied score in almost all abdominal organs including the liver, spleen, urinary organs (kidneys and urinary bladder), adrenal gland, pancreas and gastrointestinal organs (stomach, small intestine and large intestine), while vessels and lymph nodes were scored lowest in both canine and feline soft cadavers.

As mentioned above, vessels and lymph nodes were hard to identify and differentiate in cadaveric animals. Therefore, the soft embalming cadaver animal is not suitable for training vessels and lymph node identification. Our results correspond with the findings of a previous study using canine cadaver embalming methods for veterinary anatomy education (Nam *et al.*, 2020) that soft cadaveric dog and cat preserved by Thiel's embalming method is a good model in the identification the anatomical structures and very useful in veterinary anatomical education.

The limitation of this study is the small number of included cadaveric dogs and cats in the study. Moreover, we did not compare the results with live dogs and cats. Therefore, further studies should be investigated and compared with live animals to provide more information.

In conclusion, the present study suggested that soft embalming cadaveric dogs and cats by Thiel's embalming method is an efficient modality for the teaching, learning and training of radiography and ultrasonography. This preserved method is very useful in veterinary anatomical education.

**Authors' contributions:** Study conception and design: CT, NC, CW, SK, VN, SD, CC, LV and KK; Acquisition of data: CT and NC; Analysis and interpretation of data: CT and NC; Drafting of manuscript: CT and NC; Critical revision: CT, NC, CW, SK, VN, SD and KK; All authors read and approved the final manuscript.

### Acknowledgements

We would like to thank the client-owned animals that donated their animal bodies for the purpose of veterinary studies and education to the Animal Cadaver Donation Center (ACDC), Faculty of Veterinary Science, Chulalongkorn University. The funding support is from Chulalongkorn Academic Advancement Into Its 2<sup>nd</sup> Century Project.

### References

- Baglivo M, Winklhofer S, Hatch GM, Ampanozi G, Thali MJ and Ruder TD 2013. The rise of forensic and post-mortem radiology – analysis of the literature between the year 2000 and 2011. *J Forensic Radiol Imaging*. 1: 3-9.
- Benkhadra M, Faust A, Ladoire S, Trost O, Trouilloud P, Girard C, Anderhuber F, Feigl G 2009. Comparison of fresh and Thiel's embalmed cadavers according to the suitability for ultrasound-guided regional anesthesia of the cervical region. *Surg Radiol Anat*. 31: 531-535.
- Clark LM 2017. The 3Rs in research: a contemporary approach to replacement, reduction and refinement. *Br J Nutr*. 120: S1-S7.
- Clemence M and Leaman J 2016. Public attitudes to animal research in 2016. [Online]. Available: <https://www.ipsosmori.com/research>. Accessed December 10, 2020.
- Eisma R and Wilkinson T 2014. From 'silent teachers' to models. *PLoS Biol*. 12: e100197.
- George BM, Nayak SB and Marpalli S 2014. Morphological variations of the lungs: a study



- conducted on Indian cadavers. *Anat Cell Biol.* 47: 253.
- Held JM, McLendon RB, McEvoy CS and Polk TM 2019. A reusable perfused human cadaver model for surgical training: an initial proof of concept study. *Mil Med.* 184: 43-47.
- <sup>a</sup>Heng HG, Selvarajah GT, Lim HT, Ong JS, Lim J and Ooi JT 2009. Serial postmortem abdominal radiographic findings in canine cadavers. *Forensic Sci Int.* 192: 43-47.
- <sup>b</sup>Heng HG, Selvarajah GT, Lim HT, Ong JS, Lim J and Ooi JT 2009. Serial postmortem thoracic radiographic findings in canine cadavers. *Forensic Sci Int.* 188: 119-124.
- Mandal J and Parija SC 2013. Ethics of involving animals in research. *Trop Parasitol.* 3: 4.
- McLeod G, Eisma R, Schwab A, Corner G, Soames R and Cochran S 2010. An evaluation of Thiel-embalmed cadavers for ultrasound-based regional anaesthesia training and research. *Ultrasound.* 18: 125-129.
- Moon JS, Nam SM, Nahm SS and Yoon HY 2020. Usefulness of cadaver embalming solutions as alternatives to formalin in veterinary surgical training. *Thai J Vet Med.* 50: 519-528.
- Munirama S, McLeod GA, Eisma R, Schwab A, Corner G, Soames R, and Cochran S 2012. Application of sonoelastography to regional anaesthesia: a descriptive study with the Thiel embalmed cadaver model. *Ultrasound.* 20: 41-48.
- <sup>a</sup>Munirama S, Zealley K, Schwab A, Columb M, Corner GA, Eisma R and McLeod GA 2016. Trainee anaesthetist diagnosis of intraneural injection—a study comparing B-mode ultrasound with the fusion of B-mode and elastography in the soft embalmed Thiel cadaver model. *Br J Anaesth.* 117: 792-800.
- <sup>b</sup>Munirama S, Eisma R, Columb M, Corner GA, and McLeod GA 2016. Physical properties and functional alignment of soft-embalmed Thiel human cadaver when used as a simulator for ultrasound-guided regional anaesthesia. *Br J Anaesth.* 116: 699-707.
- Nam SM, Moon JS, Yoon HY, Chang BJ and Nahm SS 2020. Comparative evaluation of canine cadaver embalming methods for veterinary anatomy education. *Anat Sci Int.* 95: 498-507.
- Portela DA, Campoy L, Otero PE, Martin-Flores M and Glead RD 2017. Ultrasound-guided thoracic paravertebral injection in dogs: a cadaveric study. *Vet Anaesth Analg.* 44: 636-645.
- Saukko P and Knight B 2004. The pathophysiology of death. In: *Knight's Forensic Pathology.* Saukko P and Knight B (ed.). New York: Arnold. 52-97.
- Schnabl J, Glueckert R, Feuchtner G, Recheis W, Potrusil T, Kuhn V, Wolf-Magele A, Riechelmann H and Sprinzl GM 2012. Sheep as a large animal model for middle and inner ear implantable hearing devices: a feasibility study in cadavers. *Otol Neurotol.* 33:481-489.
- Thiel W 1992. The preservation of the whole corpse with natural color. *Ann Anat.* 174: 185-195.
- Viscasillas J, Everson R, Mapletoft EK and Dawson C 2019. Ultrasound-guided posterior extraconal block in the dog: anatomical study in cadavers. *Vet Anaesth Analg.* 46: 246-250.