

6-1-2021

Case report: Peripheral iridectomy and sclerectomy for uveitic Glaucoma in a labrador retriever

Natthanet Sritrakoon

Aree Thayananuphat

Follow this and additional works at: <https://digital.car.chula.ac.th/tjvm>



Part of the [Veterinary Medicine Commons](#)

Recommended Citation

Sritrakoon, Natthanet and Thayananuphat, Aree (2021) "Case report: Peripheral iridectomy and sclerectomy for uveitic Glaucoma in a labrador retriever," *The Thai Journal of Veterinary Medicine*: Vol. 51: Iss. 2, Article 25.

Available at: <https://digital.car.chula.ac.th/tjvm/vol51/iss2/25>

This Report is brought to you for free and open access by the Chulalongkorn Journal Online (CUJO) at Chula Digital Collections. It has been accepted for inclusion in The Thai Journal of Veterinary Medicine by an authorized editor of Chula Digital Collections. For more information, please contact ChulaDC@car.chula.ac.th.

Case report: Peripheral iridectomy and sclerectomy for uveitic Glaucoma in a labrador retriever

Natthanet Sritrakoon^{1*} Aree Thayananuphat²

Abstract

A 4-year-old male Labrador retriever dog presented with a history of conjunctivitis OU and mild buphthalmos OS for one week. Ophthalmic examination revealed corneal edema, conjunctivitis, iritis, aqueous flare, posterior synechia, fibrin on the anterior lens capsule, increased intraocular pressure (IOP =30 mmHg OD; IOP = 48 mmHg OS), weak positive menace response, brisk positive dazzle reflex and negative pupillary light reflex OU. The iridocorneal angle could not be visualized due to corneal edema. Physical examination, hematology and blood chemistry results were normal. Both eyes were diagnosed as having glaucoma and uveitis. Topical prednisolone acetate, atropine sulfate, brinzolamide and timolol including oral doxycyclin and prednisolone were prescribed. The IOP readings in the right eye were initially controlled with medication for only 3-4 weeks whereas the IOPs in the left eye were refractory to treatment. Glaucoma in the left eye became chronic while vision remained in the right eye. One-eighth iridectomy at 10-11 o'clock and 2x6 mm sclerectomy at 10-11 o'clock were performed in the right eye to create aqueous humor passage drainage. Cyclocryotherapy was performed in the left eye. Topical prednisolone acetate, brinzolamide and timolol were applied OU. Seven months postoperatively, the IOPs were maintained within normal OU limits at all examinations. Menace response and dazzle reflex were positive in the right eye. An obstacle course was positive when the left eye was covered.

Keywords: cyclocryotherapy, dog, eye surgery, glaucoma, iridectomy, uveitis

¹Ophthalmology Center, Kasetsart University Veterinary Teaching Hospital, Bang Khen, Bangkok, Thailand, 10900

²Department of Companion Animal Clinical Sciences, Faculty of Veterinary Medicine, Kasetsart University, Bangkok, Thailand, 10900

*Correspondence: foetnnsk@ku.ac.th (N. Sritrakoon)

Received: January 7, 2021.

Accepted: February 19, 2021.

doi: <https://doi.org/10.14456/tjvm.2021.50>

Introduction

Uveitis is a cause of blindness in dogs and can lead to a cataract and glaucoma. Glaucoma from uveitis can be induced by the blockage of aqueous humor flow at the iridocorneal angle by inflammatory cells, debris or neovascular membrane (Pumphrey, 2015) and pupillary block from posterior synechia (Lew and Lew, 2009). Treatments of uveitis are composed of specific and non-specific treatments, where the specific treatment is to manage the causes of uveitis and the non-specific treatment is to decrease inflammation within the eye and prevent iris synechia (Massa *et al.*, 2002). The main aim of glaucoma treatment is to control intraocular pressure (IOP) through medical or surgical treatment or a combination of both. Most medical treatments cannot successfully control IOP in the long term and surgical treatment is usually eventually suggested. Pupillary block glaucoma occurs when the aqueous humor is blocked from the posterior chamber into the anterior chamber by for example, an iris bombe from chronic uveitis (Lew and Lew, 2009). In cases of pupillary block glaucoma, aqueous humor cannot drain through the conventional pathway; therefore, a new pathway must be created to allow

drainage of aqueous humor (Strubbe, 2002). This report discusses the successful surgery for pupillary block uveitic glaucoma in a Labrador retriever dog by performing peripheral iridectomy and sclerectomy in combination with medical treatment.

Case history

A 4-year-old male Labrador retriever dog presented with a history of conjunctivitis OU and mild buphthalmos OS for one week. Ophthalmic examination revealed corneal edema, conjunctivitis, iritis, aqueous flare, posterior synechia, fibrin on the anterior lens capsule, increase IOPs (IOP = 30 mmHg OD; IOP = 48 mmHg OS), weak positive menace response, brisk positive dazzle reflex and negative pupillary light reflex OU (Fig. 1a and 1b). The results from physical examination, hematology and blood chemistry (creatinine, BUN, SGPT, ALP) were normal. The results of the snap 4Dx test were negative. Ultrasonography revealed posterior synechia OU. No intraocular mass or retinal lesion was observed. Diagnosis was secondary glaucoma from anterior uveitis OU.

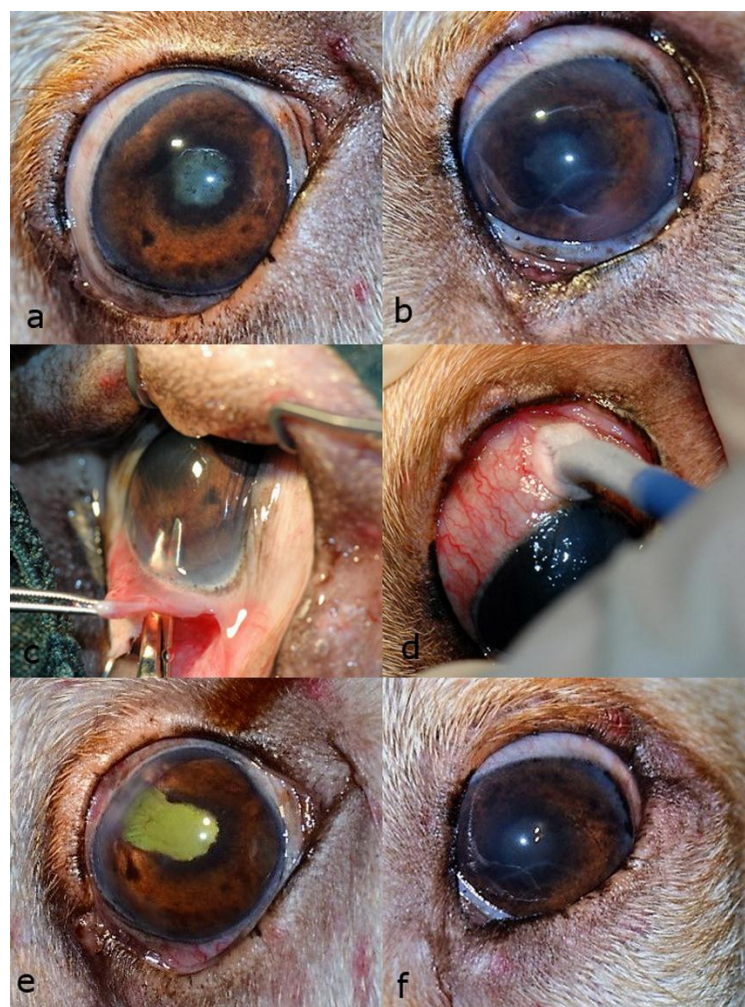


Figure 1 Uveitic glaucoma in a Labrador Retriever: (a) Before surgery, conjunctivitis, mild generalized corneal edema and partial posterior synechia were observed OD. (b) Before surgery, generalized corneal edema, Descemet's streak, complete posterior synechia and iris bombe were observed OS. (c) Peripheral iridectomy was performed OD. (d) Cyclocryotherapy was performed OS. (e) Three weeks postoperatively, the cornea was clear and the corneal wound had healed OD. (f) Three weeks postoperatively, complete posterior synechia, iris bombe, Descemet's streak and moderate corneal edema were observed OS.

Treatment: Topical 1% prednisolone acetate (Inf-oph®, Seng Thai Company Limited, Thailand) four times a day, 1% atropine sulfate (Isopto®, Alcon, Belgium) twice a day, 1% brinzolamide (Azopt®, Alcon-couvreur, Belgium) three times a day were prescribed OU. Oral 5 mg/kg doxycyclin (Siadocin®, Siam Pharmaceutical Co., Ltd., Thailand) and 0.5 mg/kg prednisolone (Prednisolone Olan®, Olan-Kemed Co., Ltd., Thailand) were administered q12h. One week later, the IOPs were 45 mmHg OU. A combination of brinzolamide and timolol (Azarga®, Alcon-couvreur, Belgium) four times a day was substituted for the brinzolamide. IOPs of both eyes were constantly above normal limits (28-37 mmHg OD and 38-73 mmHg OS). Ocular examination before surgery revealed positive menace response, dazzle reflex and negative pupillary light reflex, partial posterior synechia OD and negative menace response, dazzle reflex and pupillary light reflex, complete posterior synechia, iris bombe, Descemet's streak and corneal edema OS. Ultrasonography revealed posterior synechia OU. The planned surgery involved peripheral iridectomy and sclerectomy to create drainage of aqueous humor and sclerectomy OD and cyclocryotherapy to reduce aqueous humor production OS.

The premedication administered consisted of topical 0.5% moxifloxacin HCl (Vigamox®, Alcon Laboratories INC., USA), 25 mg/kg cefazolin (Cefaben®, L.B.S. Laboratory Ltd., Thailand) IV, 4 mg/kg tolfedine (Tolfedine®, Vetoquinol, France) SC, and 10 mg/kg xylazineHCl (Xylavet®, Thai-Meiji Pharmaceutical, Thailand) IM. Anesthesia was induced with 2.5 mg/kg propofol (Anesvan, Chi Sheng Chemical Corporation, Taiwan) IV. Three percent isoflurane (Terrell®, Minrad Inc., USA) was used for anesthetic maintenance. After standard preparation, conjunctival and scleral incisions were made at 2.0 mm behind the limbus OD with a 3.0 mm knife (Sharpoin, Surgical Specialties Corporation, USA). Sodium hyaluronate (1.2% AcrivetBiovisc, S&V Technologies AG, Germany) was injected intraocularly to protect the endothelium and maintain the anterior chamber. The attached iris was gently separated from the anterior lens capsule with an iris spatula. Then a one-eighth iridectomy (Fig.1c) and a 2x6 mm sclerectomy at the 11 o'clock position were performed. Balanced salt solution was irrigated and aspirated in the anterior chamber to remove sodium hyaluronate. The conjunctiva and limbus were sutured with PGA 8/0. Cyclocryotherapy with cryosurgery unit (Cryoline, Optikon 2000 S.p.A., Italy) setting temperature at -80°F was performed OS by placing a glaucoma cryosurgical probe on the sclera at 4-5 mm posterior to limbus for 8 spots, 2 min each (Fig.1d). Postoperatively, topical atropine sulfate was continued and moxifloxacin four times a day was applied OD. Topical 1% prednisolone acetate and brinzolamide together with timolol four times a day were continued OU. Oral 5 mg/kg doxycyclin q12h was continued for one week. Oral 0.5 mg/kg prednisolone q12h was administered for one week and gradually tapered to withdrawal at two months.

Results and Discussion

IOPs at one week, three weeks (Fig.1e), two months and seven months were 15, 10, 11 and 12 mmHg OD, respectively. Menace response and dazzle reflex were positive OD. Topical atropine, prednisolone acetate and brinzolamide together with timolol were continued OD for 2 months postoperatively and topical prednisolone was continued OS for 3 weeks postoperatively. Menace response and dazzle reflex were negative OS. IOPs were less than 25 mmHg (24, 23, 19, 24) OS for all measurements. Uveitis was well controlled OU throughout postoperative examination (Fig.1f).

This Labrador retriever dog was diagnosed as having secondary glaucoma from anterior uveitis with posterior synechia so that aqueous humor could not pass through the normal pathway. The impaired vision was caused by uncontrolled IOPs. The surgical procedures (peripheral iridectomy and sclerectomy) successfully preserved vision OD through the creation of an alternative path for aqueous humor outflow. The irreversible blind eye OS was under cyclocryotherapy to destroy the secretory epithelium of the ciliary body leading to decreased aqueous humor production. The IOPs were well controlled without any anti-glaucoma medication for 7 months follow-up OS.

The cause of uveitis in this Labrador retriever dog was presumed to be idiopathic or immune-mediated (Massa *et al.*, 2002) due to the normal results from the laboratory analysis and physical examination. Fifty-eight percent of uveitis has been reported to be idiopathic or immune-mediated (Massa *et al.*, 2002). Idiopathic or immune-mediated uveitis may occur from failure in memory autoantigen causing the development of auto-antibodies (Esson *et al.*, 2009). Another cause of uveitis is infection or tumor (Massa *et al.*, 2002). However, the owner declined to approve removal of the eye or to take a biopsy from the left eye; thus, the definitive causes of the glaucoma and anterior uveitis were not further investigated. Although Labrador retrievers are predisposed to primary glaucoma (Komaromy and Petersen-Jones, 2015), based on the findings from ophthalmic examination of this dog, uveitis was suspected to be the cause of the glaucoma. The prevalence of secondary glaucoma and uveitis of an unknown cause in Labrador retrievers has been reported to be 12% (Gelatt and MacKay, 2004).

Glaucoma is a condition of imbalance in aqueous humor outflow resulting in increased IOP and induced physiological change to the optic nerve, loss of optic cell function and loss of vision (Esson *et al.*, 2009). A high IOP for 24 to 72 hours would result in permanent blindness (Miller, 2008). The aim of treatment was to control the IOP to within normal limits to preserve or regain vision and relieve pain (Reinstein *et al.*, 2009). The treatment of uveitic glaucoma is challenging due to the many different mechanisms that affect the IOP (Moorthy *et al.*, 1997). Generally, medical treatment is considered to be the primary treatment; however, some anti-glaucoma drugs such as prostaglandin agonists are not suitable to use in uveitic glaucoma because they may exacerbate the inflammatory reaction in the eye (Vuori, 2010). Surgical treatment is the alternative method for glaucoma patients when

medical treatment would not be effective (Reinstein *et al.*, 2009). Appropriate surgery depends on several criteria, with the main purpose of surgery being to preserve or regain vision (Maggio and Bras, 2015). Methods for surgical treatment have been described as filtering procedures and cyclodestructive procedures (Maggio and Bras, 2015; Morgan and Yu, 2012). Filtering procedures such as peripheral iridectomy, sclerectomy, trabeculectomy, iridencleisis, gonioimplantation (Morgan and Yu, 2012) and cyclodestructive procedures such as transscleral cyclophotocoagulation and endoscopic cyclophotocoagulation have been described to control IOP in dogs where vision is still evident (Maggio and Bras, 2015). The objective of filtering procedures is to increase aqueous humor outflow (Morgan and Yu, 2012). Peripheral iridectomy is one method of making a new pathway for aqueous drainage resulting from pupil block. Sclerectomy was additionally performed to maintain the potency of aqueous drainage. Filtering surgery may worsen the inflammation due to stimulating fibroblast proliferation leading to surgical failure (Mansuri and Bhagat, 2011). Other complications of the filtration procedure are hyphema, posterior synechia, cataract and filtration bleb (Cook, 1997; Lew and Lew, 2009). In the current study, those complications did not occur during the 7 months follow up, resulting in maintained vision OD for 7 months before the dog died from an unrelated cause.

Cyclodestructive procedures such as cyclocryotherapy are one form of surgical management for glaucoma. This technique aims to reduce the production of aqueous humor. Possible complications from this procedure are IOP spike, uveitis, exposure keratoconjunctivitis, hyphema, retinal detachment, recurrence glaucoma and phthisis bulbi. Generally, this procedure is not recommended where vision is still evident (Reinstein *et al.*, 2009). In the case of blindness, cyclocryotherapy has a 90% success rate for IOP control (Miller, 2008).

In dogs, the success rate of uveitic glaucoma treatment is lower than for other types of glaucoma because of inflammation and protein-rich aqueous humor (Mansuri and Bhagat, 2011). Secondary glaucoma from posterior synechia in an active uveitis dog with an unknown etiology is a frustrating situation. Surgery is an option when the glaucoma is refractory to medication treatment. Peripheral iridectomy and sclerectomy OD in the dog in the current study successfully created a pathway for aqueous humor drainage and controlled the IOP within normal limits. These techniques preserved vision for at least 7 months. Long term success needs further investigation. Cyclocryotherapy was performed OS for permanent control IOP. This report presents an alternative treatment for glaucoma and uveitis with posterior synechia where the IOP could not be controlled with medical treatment.

References

- Cook CS 1997. Surgery for glaucoma. *Vet Clin North Am Small Anim Pract.* 27: 1109-1129.
- Esson D, Armour M, Mundy P, Schobert CS and Dubielzig RR 2009. The histopathological and immunohistochemical characteristics of pigmentary and cystic glaucoma in the Golden Retriever. *Vet Ophthalmol.* 12: 361-368.
- Gelatt KN and MacKay EO 2004. Secondary glaucomas in the dog in North America. *Vet Ophthalmol.* 7: 245-259.
- Komaromy AM and Petersen-Jones SM 2015. Genetics of canine primary glaucomas. *Vet Clin North Am Small Anim Pract.* 45: 1159-1182.
- Lew M and Lew S 2009. Combined iridencleisis and posterior sclerectomy in surgical treatment of glaucoma secondary to uveitis in a dog: a case report. *Vet Med (Praha).* 54: 142-148.
- Maggio F and Bras D 2015. Surgical treatment of canine glaucoma: filtering and end-stage glaucoma procedures. *Vet Clin North Am Small Anim Pract.* 45: 1261-1282.
- Mansuri M and Bhagat P 2011. Glaucoma in uveitis. *J Curr Glaucoma Pract.* 5: 8-14.
- Massa KL, Gilger BC, Miller TL and Davidson MG 2002. Causes of uveitis in the dogs: 102 cases (1989-2000). *Vet Ophthalmol.* 5: 93-98.
- Miller PE 2013. The glaucoma. In: *Slatter's Fundamentals of Veterinary Ophthalmology.* 5th ed. DJ Maggs, PE Miller and R Ofri (eds). St. Louis: Elsevier. 247-271.
- Moorthy R, Mermoud A, Baerveldt G, Minckler D, Lee P and Rao N 1997. Glaucoma associated with uveitis. *Surv Ophthalmol.* 41:361-394.
- Morgan WH and Yu D 2012. Surgical management of glaucoma: a review. *Clin Exp Ophthalmol.* 40: 388-399.
- Pumphrey S 2015. Canine secondary glaucomas. *Vet Clin North Am Small Anim Pract.* 45: 1335-1364.
- Reinstein SL, Rankin A and Allbaugh R 2009. Canine glaucoma: Medical and surgical treatment options. *Compend Contin Educ Vet.* 31: 454-458.
- Strubbe T 2002. Uveitis and pupillary block glaucoma in an aphakic dog. *Vet Ophthalmol.* 5: 3-7.
- Vuori M 2010. Molteno aqueous shunt as a primary surgical intervention for uveitic glaucoma: long term results. *Acta Ophthalmol.* 88: 33-36.