

6-1-2021

Administration of the α -tocopherol for repairing testicle histological damage in rats exposed to dioxin

Wurlina Wurlina

Imam Mustofa

Dewa Ketut Meles

Sri Mulyati

Desak Ketut Sekar Cempaka Putri

See next page for additional authors

Follow this and additional works at: <https://digital.car.chula.ac.th/tjvm>



Part of the [Veterinary Medicine Commons](#)

Recommended Citation

Wurlina, Wurlina; Mustofa, Imam; Meles, Dewa Ketut; Mulyati, Sri; Cempaka Putri, Desak Ketut Sekar; and Suwasanti, Niluh (2021) "Administration of the α -tocopherol for repairing testicle histological damage in rats exposed to dioxin," *The Thai Journal of Veterinary Medicine*: Vol. 51: Iss. 2, Article 12.

Available at: <https://digital.car.chula.ac.th/tjvm/vol51/iss2/12>

This Article is brought to you for free and open access by the Chulalongkorn Journal Online (CUJO) at Chula Digital Collections. It has been accepted for inclusion in The Thai Journal of Veterinary Medicine by an authorized editor of Chula Digital Collections. For more information, please contact ChulaDC@car.chula.ac.th.

Administration of the α -tocopherol for repairing testicle histological damage in rats exposed to dioxin

Authors

Wurlina Wurlina, Imam Mustofa, Dewa Ketut Meles, Sri Mulyati, Desak Ketut Sekar Cempaka Putri, and Niluh Suwasanti

Administration of the α -tocopherol for repairing testicle histological damage in rats exposed to dioxin

Wurlina Wurlina¹ Imam Mustofa^{1*} Dewa Ketut Meles² Sri Mulyati¹

Desak Ketut Sekar Cempaka Putri³ Niluh Suwasanti⁴

Abstract

This study aims to determine the α -tocopherol effect on repairing histological damage to the testicles of rats exposed to 2,3,7,8-tetrachlorodibenzo-p-dioxin. The testicle histological damage and repairs were evaluated based on spermatogenic staging changes, seminiferous tubule diameter and the thickness of the epithelium. A total of 100 rats were divided into five groups. The control group (CG) rats only received a placebo. Meanwhile, in treatment groups, rats were exposed to dioxin 700 ng/kg/BW/day and four hours later they received a 0, 77, 140 and 259 α -tocopherol mg/kg/BW/day in the T0, T1, T2 and T3 groups, respectively. Dioxin exposure and α -tocopherol administration were conducted orally through a stomach tube in 45 days. Dioxin administration resulted in a reduction ($p < 0.05$) in the spermatogenic staging based on the number of spermatogenic cells and Leydig cells, diameter and thickness of the seminiferous tubule epithelium compared to those of normal rats (CG). The administration of 140 (T2) and 259 (T3) α -tocopherol mg/kg/BW/day alleviated the spermatogenesis depletion caused by dioxin, which was indicated by the higher ($P < 0.05$) number of spermatogenic cells and Leydig cells and the diameter and thickness of the seminiferous tubule epithelium compared to the T0 group. A dose of 259 α -tocopherol mg/kg/BW/day (T3) raised the spermatogenic staging closer to that of the normal rats, although it was still lower ($p < 0.05$). It can be concluded that α -tocopherol antagonized the toxicity of dioxin on the testis.

Keywords: Dioxin, epithelial diameter, rats, seminiferous tubules, spermatogenic staging, α -tocopherol

¹Department of Veterinary Reproduction, Faculty of Medicine Universitas Airlangga

²Department of Veterinary Pharmacology, Faculty of Medicine Universitas Airlangga

³Department of Cardiology and Vascular Medicine, Faculty of Medicine Universitas Airlangga

⁴Department of Clinical Pathology, Faculty of Medicine Widya Mandala Catholic University

*Correspondence: imam.mustofa@fkh.unair.ac.id, imam.mustofa@ymail.com (I. Mustofa)

Received: October 21, 2020.

Accepted: February 24, 2021.

doi: <https://doi.org/10.14456/tjvm.2021.37>

Introduction

Dioxin (2,3,7,8-tetrachlorodibenzo-p-dioxin) is the most hazardous chemical known to humankind. (Lali, 2018) Dioxin is affected by intracellular reactive oxygen species (ROS) production, followed by oxidative stress (Zhou *et al.*, 2017). Oxidative stress results in the increased production of free radicals or reactive oxygen species (Bartosikova *et al.*, 2003), which tends to attract electrons from important molecules around it, such as proteins, lipids, and DNA (Yang *et al.*, 2002). Increased ROS production causes lipid peroxidation reaction, which is harmful to the lipid membrane and is followed by cell damage (Jeyabalan and Caritis, 2006). Dioxin has a toxic effect on the reproductive system (Yonemoto, 2000) because the testicular tissue is susceptible to oxidative stress (Asadi *et al.*, 2017). The ROS inhibits the process of steroidogenesis in Leydig cells, decreases the testosterone hormone level, followed by disturbance of the spermatogenic cells (Walker *et al.*, 2009).

ROS can be neutralized physiologically by an endogenous antioxidant; unfortunately, environmental factors, such as pollutants, can decrease this capacity. Therefore, antioxidant treatment is expected to fight free radical-induced oxidative stress and, consequently, improve spermatogenesis (Asadi *et al.*, 2017). α -tocopherol is an exogenous antioxidant that can break radical chain reactions to inhibit ROS and oxidative stress (Valko *et al.*, 2007). Administration of α -tocopherol to rats under oxidative stress can significantly reduce MDA levels, normalize seminiferous tubular epithelium (Walker, 2009) and increase the reproductive endocrine function (Yin *et al.*, 2012).

The world produces more than 380 million tons of plastic every year, which ends up as pollutants (Our world in data.org, 2020). Dioxin, due to incomplete incineration, of plastic waste is a significant source of air pollution. Dioxin has a harmful effect on testicular tissue. Furthermore, a recent study aimed to determine the effect of α -tocopherol administration in an animal model on repairing the testicle histological damage to rats exposed to dioxin.

Materials and Methods

Ethical Approval: The experimental procedure was approved by The Animal Care and Use Committee, Airlangga University, Surabaya, Indonesia, No 267/HRECC.FODM/VI/2020.

Dosage determination: Determination of dioxin (the 2,3,7,8 - tetrachlorodibenzo-p-dioxin, Sigma Aldrich Singapore) and α -tocopherol (α -tocopherol Sigma Aldrich Singapore) doses were based on a study of mice. The conversion of the dose for mice to the dose for rats used the Allometric approach (Ritschel *et al.*, 1992), in which the dose in rats was the dose in mice multiplied by a factor of 7. The toxic dose of dioxin in mice was 100 ng/kg BW (Yoon *et al.*, 2006). Accordingly, in rats, it was 700 ng/kg BW / day. The average body weight of the rats in this study was 200 grams so that the dioxin dose was 140 ng/head/day. Meanwhile, the α -tocopherol dose was converted from the dose of 11, 20 and 37 mg/kg BW mice/day (Yin *et*

al., 2012), so that the doses in rats were 77, 140 and 259 mg/kg BW / day. In rats weighing 200 grams, the α -tocopherol doses were 15.5, 28 and 51.8 mg/head/day. Dioxin and α -tocopherol were dissolved in corn oil (Mazola® - Codaa Switzerland AG) for administration to the rats.

Treatment of experimental animals: Rats were reared in polypropylene boxes as like cat litters 60 x 40 and 12.5 cm in height and covered with a wire mesh 10x10 mm. Each box was divided into four parts equally for the housing of individual rats and equipped with feed and drink containers. The cage floor was filled with sawdust 3 cm thick, which was replaced once a week. A total of 100 male rats (Wistar strain of *Rattus norvegicus*) aged 12 weeks, weighing approximately 200 grams and in a healthy condition, were randomly divided equally into five treatment groups. The control group (CG) rats received 0.5 ml of corn oil twice daily at four h intervals simultaneously with the treatment group. The rats in the treatment groups received a dose of 700 ng dioxin/kg BW/day at 09.00 AM, followed by administration of the α -tocopherol 0, 77, 140 and 259 mg/kg BW/day, four h later for the T0, T1, T2 and T3 groups, respectively. Dioxin exposure and α -tocopherol administration were conducted orally through a stomach tube for 45 consecutive days. The rats' health was observed daily, along with cleaning of cages, feeding, and changing of drinking water. Healthy rats were indicated by their agility of movement in the cage, standing or walking with their bodies elevated and with a horizontal back. The fur was white and glossy, the tail clean, free of fecal accumulation around the perineum, inflammation or discoloration, with clear eyes and standing erect ears. Throughout the study, all the mice appeared healthy and there were no deaths before termination. On the 46th day, all rats were sacrificed to harvest their testicular organs to prepare histological slides with hematoxylin-eosin staining.

Observation of cell count: Five seminiferous tubules were randomly selected for the average spermatogenic cell number. Meanwhile, the number of Leydig cells was counted between the five seminiferous tubules. Observations were made with a 400x magnification light microscope (Nikon E200) equipped with Optilab Viewer Software Version 2.2.

The measurement of seminiferous tubule diameter: The diameter (μ m) was measured on five tubules at 100x magnification with a light microscope equipped with the Image Raster Software Version 3.7. The diameter was defined as the farthest distance from the two points opposite the center point. In one seminiferous tubule, four diameters were measured with an angular distance of 45 degrees from each other for the average.

Epithelium thickness measurement: The seminiferous tubules' epithelial thickness (μ m) was measured in five tubules at 100x magnification using a light microscope (Nikon E200) equipped with Image Raster Software Version 3.7. The epithelial thickness was defined as the distance from the basement membrane to the spermatogonia cell layer's surface. Each seminiferous

tubule was measured in four of the epithelial thicknesses for an average.

Data analysis: The number of spermatogenic cells (spermatogonia, primary spermatocytes and secondary spermatocytes, spermatids and spermatozoa), Leydig cells and the diameter of seminiferous tubule and the thickness of epithelium cells were analyzed using One Way ANOVA followed by Tukey's Honestly Significant Difference test (SPSS Version 23).

Results

Spermatogenic staging: The features of the spermatogonia, primary spermatocytes, secondary spermatocytes, spermatids and spermatozoa were used to determine the spermatogenic staging (Figure 1). Chronic exposure of dioxin over 45 days (T0) decreased the spermatogonia, primary spermatocytes,

secondary spermatocytes, spermatids and spermatozoa to 59.41, 37.63, 34.66, 27.23 and 77.66% compared to the CG. The most severe reduction in amount was in spermatozoa, followed by spermatids, secondary spermatocytes, primary spermatocytes, spermatogonia and the lightest reduction was in the Leydig cell. The administration of α -tocopherol 4 h after dioxin exposure for 45 consecutive days showed that a dose of 77 mg/kg BW/day α -tocopherol had not yet covered ($p>0.05$) the negative effect of dioxin. A higher dose of α -tocopherol (140 and 259 mg/kg BW/day) was followed by an improvement of spermatogenic staging marked by increases ($p<0.05$) of spermatogonia, primary spermatocytes and secondary spermatocytes, spermatids and spermatozoa numbers. A dose of 259 mg/kg BW/day α -tocopherol (T3) revealed the closest numbers of testicles to normal rats (CG), even though still significantly lower ($p<0.05$) (Table 1).

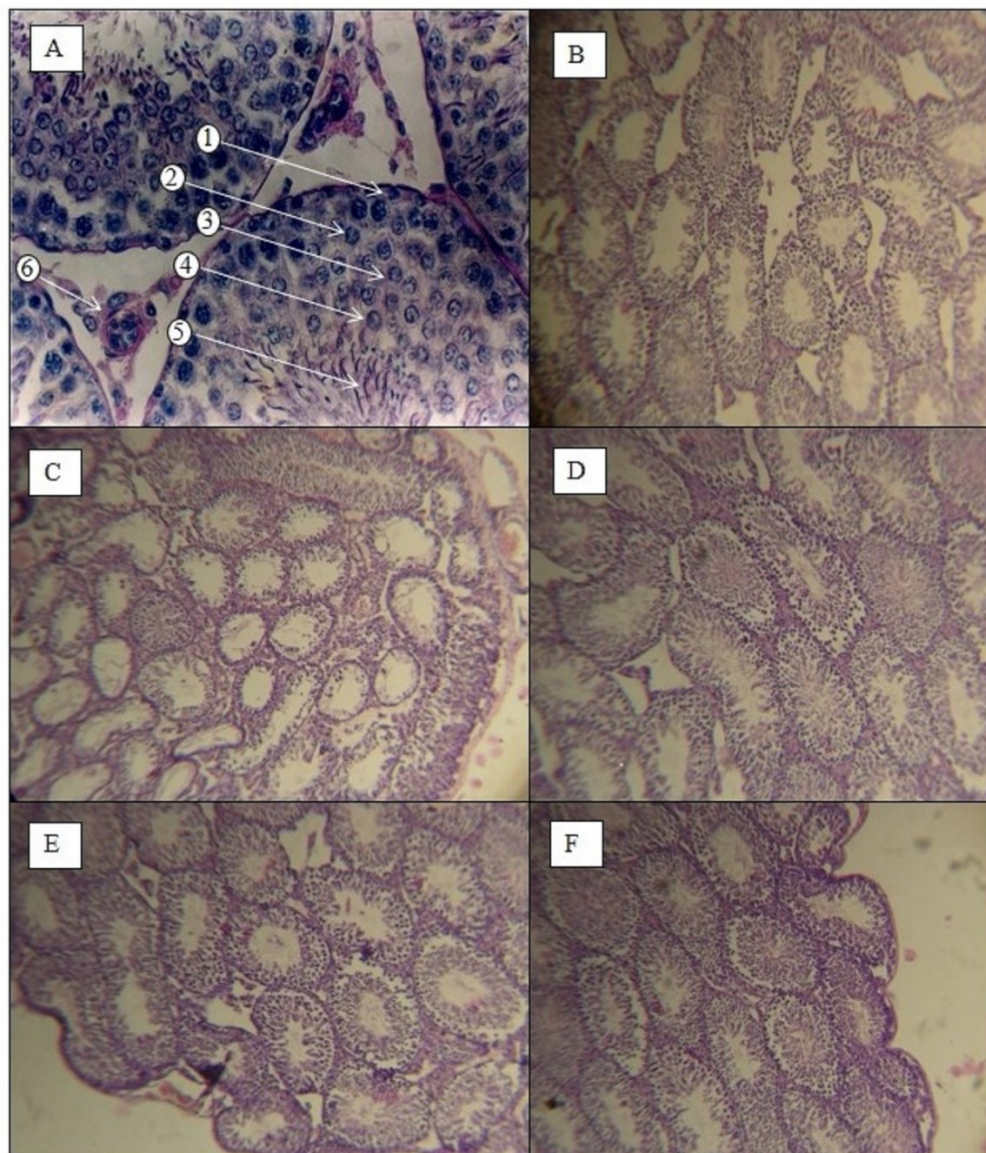


Figure 1 Histologic of seminiferous tubules: A. CG showed the spermatogonia (1), primary spermatocytes (2) and secondary spermatocytes (3), spermatids (4), spermatozoa (5) and Leydig cell (6) (HE staining, 400x magnification). B. CG, C. treatment group rats, which received 700 ng dioxin/kg BW/day for 45 days, followed by administration of the α -tocopherol 0 (T0), D. 77 (T1), E. 140 (T2), and F. 259 (T3) mg/kg BW/day four h later for 45 days (HE staining, 400x magnification).

Table 1 The average of spermatogenic cells and Leydig cells of rats exposed to dioxin and treated with α -tocopherol

Treatment	Number of spermatogonia	Number of spermatocytes I and secondary spermatocytes	Number of spermatids	Number of spermatozoa	Number of Leydig cell
CG	25.25±2.31 ^a	34.55±3.03 ^a	28.85±2.73 ^a	38.75 ±2.57 ^a	18.98±1.06 ^a
T0	15.25±2.55 ^d	13.45±2.56 ^d	10.75±2.14 ^d	10.55±1.95 ^d	14.74±1.19 ^c
T1	15.85±2.23 ^d	13.75±2.26 ^d	11.05 ±1.95 ^d	11.75±2.57 ^d	15.11±1.68 ^c
T2	18.15±2.45 ^c	24.25±2.53 ^c	24.15±3.03 ^c	28.35±2.39 ^c	16.63±1.32 ^b
T3	23.55±2.60 ^b	32.35±1.75 ^b	26.25±1.33 ^b	35.75±2.80 ^b	18.01±1.77 ^a

Note: CG= the control group rats, which received 0.5 ml of corn oil twice daily and at four h intervals simultaneously with the treatment group, T0= treatment groups rats, which received 700 ng dioxin/kg BW/day for 45 days, followed by the administration of corn oil; T1= treatment groups rats which received 700 ng dioxin/kg BW/day for 45 days, followed by the administration of the α -tocopherol 77 mg/kg BW/day four h later for 45 days. T2= treatment groups rats, which received 700 ng dioxin/kg BW/day for 45 days, followed by administration of the α -tocopherol 140 mg/kg BW/day four h later for 45 days., T3= treatment groups rats, which received 700 ng dioxin/kg BW/day for 45 days, followed by administration of the α -tocopherol 259 mg/kg BW/day four h later for 45 days. Different superscripts in the same column showed significant differences ($p < 0.05$).

The cross-section of the seminiferous tubules of the CG showed a number of spermatogenic cells fulfilled the seminiferous tubules. The spermatogenic cells were neatly arranged with a high cell density. The spermatogonia consisted of a layer; meanwhile, primary and secondary spermatocytes were composed of 1-2 layers and spermatids were composed of 2-3 layers. In contrast, the dioxin exposure (T0 group) effect showed that the spermatogenic cells' location was irregular with a low cell density. In the group with α -tocopherol administration, the T1 group (dose of α -tocopherol 77 mg/kg BW/day) had not been able to repair testicular tissue damage. Meanwhile, the T2 and T3, the dose of α -tocopherol 140 and 259 mg/kg BW/day showed increased spermatogonia cell density that resembled the control group.

Leydig cell count: The number of Leydig cells in the control group was highest compared to the other groups. The dioxin (T0) decreased the Leydig cell number to lower than the other groups. The administration of 77 mg/kg BW/day α -tocopherol had not yet covered ($p > 0.05$) the negative effect of dioxin.

A higher dose of α -tocopherol (140 and 259 mg/kg BW/day) was followed by increases in Leydig cells ($p < 0.05$). A dose of 259 mg/kg BW/day α -tocopherol (T3) revealed that the number of Leydig cells was similar ($p > 0.05$) to that of normal rats (Table 1).

Seminiferous tubule epithelium diameter and thickness: The exposure of dioxin over 45 days (T0) decreased the seminiferous tubule diameter and epithelium thickness to 73.26 and 67.35% compared to the CG. The dose of α -tocopherol 77 mg/kg BW/day that was administered 4 h after exposure of dioxin in the 45 consecutive days of study had not yet covered ($p > 0.05$) the negative effect of dioxin. A higher dose of α -tocopherol (140 and 259 mg/kg BW/day) was followed by an increasing ($p < 0.05$) of Seminiferous tubule diameter and epithelium thickness. A dose of 259 mg/kg BW/day α -tocopherol (T3) revealed the closest diameter of seminiferous tubule epithelium of normal rats (CG), even though still significantly lower ($p < 0.05$) (Table 2), meanwhile the epithelium thickness was similar ($p > 0.05$) with that of the control group.

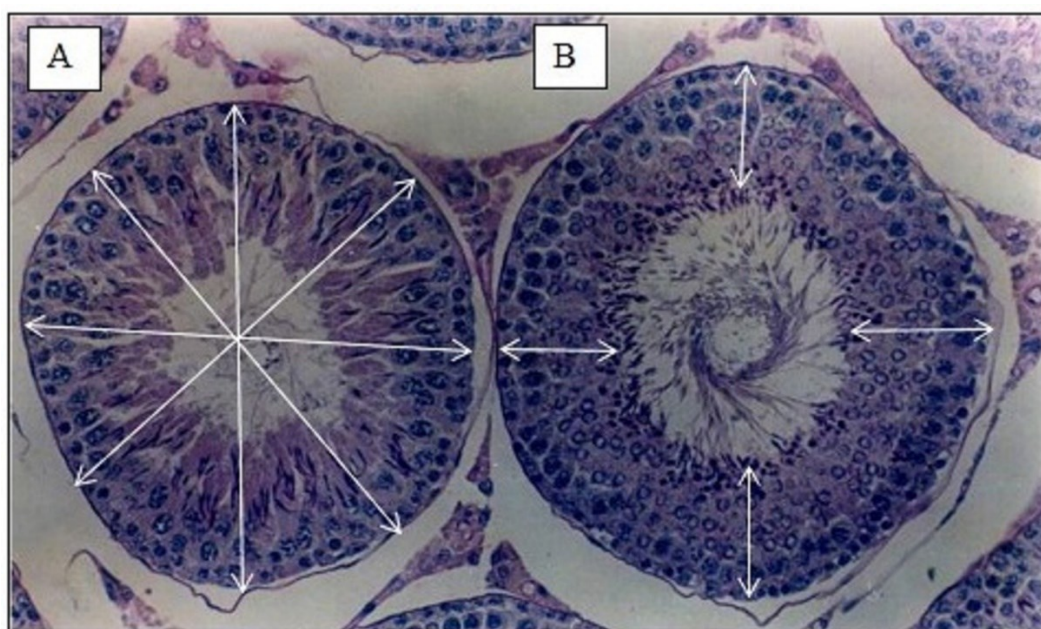


Figure 2 The measurement of seminiferous tubule diameter (A) and epithelium thickness (B) on the control group rats (HE staining, 400x magnification).

Table 2 Diameter Seminiferous tubule and epithelium thickness (μm) of rats exposed dioxin and treated with α -tocopherol.

Treatment	The diameter of the seminiferous tubules	The thickness of seminiferous tubule epithelium
CG	869.90 \pm 15.40 ^a	248.44 \pm 15.67 ^a
T0	637.28 \pm 46.04 ^c	167.33 \pm 10.14 ^c
T1	670.81 \pm 55.90 ^c	178.84 \pm 6.46 ^c
T2	743.35 \pm 44.44 ^b	205.46 \pm 11.92 ^b
T3	799.06 \pm 24.39 ^{ab}	249.42 \pm 18.87 ^a

Note: CG= the control group rats, which received 0.5 ml of corn oil twice daily and at four h intervals simultaneously with the treatment group, T0= treatment groups rats, which received 700 ng dioxin/kg BW/day for 45 days, followed by the administration of corn oil; T1= treatment groups rats which received 700 ng dioxin/kg BW/day for 45 days, followed by the administration of the α -tocopherol 77 mg/kg BW/day four h later for 45 days. T2= treatment groups rats, which received 700 ng dioxin/kg BW/day for 45 days, followed by administration of the α -tocopherol 140 mg/kg BW/day four h later for 45 days. T3= treatment groups rats, which received 700 ng dioxin/kg BW/day for 45 days, followed by administration of the α -tocopherol 259 mg/kg BW/day four h later for 45 days. Different superscripts in the same column showed significant differences ($p < 0.05$).

Discussion

The rats were observed in a healthy condition; neither illness, clinical signs nor death were found along with the study.

Spermatogenic staging: The spermatogenesis abnormalities can be seen from the number of spermatogenic cells that fulfilled the seminiferous tubules. The change could have been caused by the decrease, the stopping of the development stage or the releasing of germ cell attachments on the basal membrane. Dioxin exposure causes disruption of the spermatogenesis process, which will decrease the number of spermatogenic cells and seminiferous tubular diameter (Aitken and Roman, 2008). Dioxin is a lipophilic substance, slowly metabolized and excreted, so it tends to accumulate in adipose tissue (Yin *et al.*, 2012). Dioxins can suppress spermatozoa's growth and maturation, reduce testosterone levels, GnRH, FSH and LH, damage the chromosomes and cytomicrosomes system's antioxidant defenses (Latchoumycandane *et al.*, 2002) and finally cause oxidative stress. Dioxin's disruption of spermatogenesis at the spermatocytogenesis and spermiogenesis stages results in decreased spermatogenic cells (Dirican and Calendar, 2012).

The testis has been reported to be among the most sensitive organs to dioxin exposure. Dioxins use the aryl hydrocarbon receptor (AhR) and aryl hydrocarbon receptor nuclear translocator (ARNT) receptor complex to mediate their harmful actions in rat and human testis. The AhR and ARNT play a role in regulating spermatocytes' apoptosis (Schultz *et al.*, 2003). The hazardous effects of dioxins are disruption of cell-to-cell interactions in the testes, impaired development of germ cells, impaired spermatogenesis, reduced antioxidant enzymes and increased lipid peroxidation (Mathur and D'Cruz, 2011). Dioxin is known to inhibit steroidogenesis in the testis through Leydig cell disturbance, following testosterone level instability (Oda and Maddawy, 2012). The mechanism of oxidative stress caused by dioxins can be explained by the products formed during normal steroidogenesis acting as pseudosubstrates and interacting with P450. The pseudosubstrate-P450-O₂ complex is formed, which is a source of damage due to the pseudosubstrates' inability to ward off free radicals (Mathur and D'Cruz, 2011). In this study, spermatogenic cell decrease was caused by

spermatozoa, spermatocytes and spermatogonia experiencing attachment release caused by the occurrence of necrosis in spermatocytes and spermatogonia (Yin *et al.*, 2012). Additionally, dioxins interfere with endocrine activity mediated by aromatic hydrocarbon nuclear translocator receptors (AhR). Furthermore, AhR activates dioxins to induce CYP1A1 expression and can interact with androgen receptors (AR). In addition to interacting with AR, dioxins can also bind ABP and then dioxins will bind AhR in the cytoplasm. The AhR and dioxin bond complex undergoes a conformational change and is translocated to the nucleus (Ebtakar, 2004). This bond forms a heterodimer with another transcription factor, namely ARNT, which will interact with dioxin-responsive enhancer elements (DRE) located on the target gene's surface and activates various transcription factors' cell nuclei (Yonemato, 2000). The AhR-ARNT heterodimer results in the cytochrome P450 gene's stimulation and leads to increased production of cytochrome. Cytochrome P450 is an enzyme generated by oxidative species reactions (ROS) due to the toxic agent (Kaur *et al.*, 2006). These cytochromes are formed and participate in dioxin metabolic processes (Dobrzyński *et al.*, 2009). The AhR and ARNT in the male reproductive tract were detected in the testes, epididymis, vas deferens, ventral prostate, dorsolateral prostate and seminal vesicles and expressed on spermatocytes (Schultz *et al.*, 2000).

The antioxidant effect of α -tocopherol is to reduce dioxin-induced CYP1A1 expression and this has an inhibitory effect on CYP1A1 promoter activity. There was a decrease in the activation induced by dioxin, CYP1A1 activity and Ecto-ATPase activity. This suggests the dioxin-induced CYP1A1 transcription suppressant was via suppression of functional AhR activation. Ecto-ATPase inhibition can reduce the production of the ATP required for the translocation of AhR electrons. Ecto-ATPase is the primary enzyme responsible for releasing ATP energy, which is used in the translocation of AhR to electron ligands. The α -tocopherol can decrease dioxin-induced AhR activation so that it can be used to prevent and treat acute and chronic dioxin intoxication (Chang *et al.*, 2009).

Dioxin can reduce the number of spermatogenic cells in the seminiferous tubules due to the disruption of endocrine activity mediated by aryl hydrocarbon receptors (AhR). The AhR system can bind the

androgen receptor (AR) and androgen binding protein (ABP) (Kakeyama and Tohyama, 2003). Binding to AR and ABP will interfere with the transport mechanism of testosterone produced by Leydig cells in the seminiferous tubules; this, in turn, interferes with the spermatogenesis process by reducing the number of spermatogenic cells. Intratubular testosterone concentration greatly influences the early stages of germ cell development. Emphasis on testosterone biosynthesis can inhibit spermatogenesis. Dioxin exposure is extreme in more mature epithelial germ cells, namely, spermatids and spermatozoa (Dirican and Calendar, 2011). Testosterone in the seminiferous intratubular significantly affects the blood-testis barrier; moreover, testosterone is required for Sertoli-spermatid adhesion and mature spermatozoa release into the lumen of the seminiferous tubules (Walker, 2009). Testosterone controls developing germ cells, especially spermatids, and acts as an adhesive between spermatids and Sertoli cells. A disruption in testosterone will cause spermatids to be released from the epithelium (Lui and Lee, 2009).

α -tocopherol is a fat-soluble antioxidant that protects against oxidative stress. It prevents lipid peroxide production by scavenging toxic radicals, a byproduct of the metabolic processes of the testes' cell membranes. In addition, α -tocopherol is essential in maintaining the testes' physiological integrity, epididymis and glandular accessories, which have a critical role in spermatozoa's maturation (Oda and El Baddawy, 2012). The function of α -tocopherol is as a chain-breaker of nonspecific antioxidants that prevent the spread of free radicals. It has a protective effect that plays a role in preventing oxidative damage to the testes through its ability to rapidly and effectively scavenge peroxy lipid radicals before damage to testicular lipid membranes and spermatogenic cells occurs. Also, α -tocopherol is a non-enzymatic testicular defense systems in mitochondria, spermatozoa and can inhibit peroxidation of testicular damage. α -tocopherol has an essential role in the maintenance and survival of spermatids (Chandra *et al.*, 2010).

The mechanism of the action of α -tocopherol is antagonistic on dioxins. First, α -tocopherol suppresses the target aryl hydrocarbon receptor (AhR) that mediates dioxin-induced gene expression. It is known that dioxins can have a toxic effect during activation of AhR and cytochrome-P450 (CYP450). The α -tocopherol can inhibit the transcription and expression of CYP450 and steroid dehydrogenase genes by inhibiting dioxin induction against AhR activation; besides that, α -tocopherol can reduce the competitive binding of dioxins against AR and ABP; thus, α -tocopherol has an antagonist effect on dioxin toxicity. In addition, α -tocopherol can reduce the increase in CYP450 levels of mRNA, 3 β -hydroxysteroid dehydrogenase and 17 β -hydroxysteroid dehydrogenase (Murugesan *et al.*, 2007). Second, α -tocopherol inhibits oxidative stress caused by dioxins. α -tocopherol has the antagonistic effect of decreasing oxidative stress and a decrease in hydrogen dioxide caused by dioxins. In addition, α -tocopherol reduces lipid peroxidation and oxidative stress caused by dioxins (Latchoumycandane and Mathur, 2002). This

study shows that dioxins damage testicular components through oxidative damage, while α -tocopherol provides a restorative effect through testosterone due to Leydig cell function's repairing.

Leydig cell count: When a rat is exposed to dioxins, a dioxin-AhR-Arnt compound-complex will form, interacting with DRE (Dioxin Responsive Enhancer Elements). This binding will increase the expression of cytochrome P450, especially CYP1A1. The ROS formed due to the CYP450 expression results in a disruption of the steroidogenesis as one of ROS's physiological sources in Leydig cells. In Leydig cells, there is a receptor mediator called AR (Androgen Receptor); AR acts to mediate the steroidogenesis pathway (Chang *et al.*, 2004). However, the bond of CYP450 and AR results in a decrease in AR action on Leydig cells and an increase in ROS in cells resulting in death in Leydig cells. The decline in the number of Leydig cells results in a reduction in testosterone production, causing decreased spermatogenesis. Dioxin-induced testes tissue damage can be repaired by administering antioxidants such as α -tocopherol (El-Gerbed *et al.*, 2015), including Leydig cells' damage. The administration of α -tocopherol breaks the dioxin chain bonds with the AhR (Aryl hydrocarbon receptor) (Kloser *et al.*, 2011) receptor found in the cell cytoplasm (Gupta *et al.*, 2018). Additionally, α -tocopherol antioxidants extinguish oxidative stress (Ruiz-Ramos *et al.*, 2010) so that cell damage is repaired (Górnicka *et al.*, 2019). The α -Tocopherol can interrupt the lipid peroxidation reaction and protect cells against oxidative stress (Soleimani Mehranjani and Taefi, 2012). By stopping lipid peroxidation reactions and removing free oxygen radicals, α -tocopherol protects lipids from peroxidation and stabilizes cell membranes, gene transcription and cell signaling pathway regulation (Górnicka *et al.*, 2019). Therefore, α -tocopherol normalizes the testes' structure, epithelial seminiferous tubule and the number of spermatozoa (Viguera-Villaseñor *et al.*, 2011) through the repairing of Leydig cell function (Yin *et al.*, 2012). Leydig cells produce testosterone due to LH stimulation produced by the anterior pituitary (Ramaswamy and Weinbauer, 2014). Testosterone regulates *signaling pathways* in Sertoli cells to maintain *spermatogenesis* (Smith and Walker, 2014).

Seminiferous tubule diameter and epithelium thickness:

The decrease in seminiferous tubule diameter due to dioxin induction can be caused by a decline in the number and production of spermatozoa in seminiferous tubules (Clermont and Perey, 2008, Kovacevic *et al.*, 2016). Administration of α -tocopherol can significantly improve the diameter of seminiferous tubules; the higher the dose given, the closer to normal size they become. Administration of α -tocopherol 259 mg/kg BW/day decreased ROS production and returned the seminiferous tubule diameter to nearly the same size as the CG. As an antioxidant, α -tocopherol can stabilize free radicals by complementing the lack of electrons in free radicals and inhibiting the chain reaction of free radical formation, which can cause cell damage. Thus, damage to cell membranes due to free radicals can be

inhibited, resulting in the bonds between hormones that play a role in the spermatogenesis process with hormone receptors not being disturbed. The spermatogenesis process is more optimal, such that there is an increase in spermatogenic cells affecting the diameter and thickness of the seminiferous tubule epithelium. Notably, α -tocopherol is a compound that counteracts free radicals, which can inhibit catechol-O-methyltransferase (COMT). This enzyme reduces the breakdown of epinephrine and inhibits heat shock proteins that can cause cell apoptosis (Kovacevic *et al.*, 2016).

Male fertility is seen not only in the number of spermatogenic cells but also from the diameter and thickness of the seminiferous tubule epithelium (Clermont and Perey, 2008, Kovacevic *et al.*, 2016). Dioxin exposure was caused by the degeneration of the seminiferous tubular epithelium, followed by a decrease in epithelial thickness. The reduced thickness of the seminiferous tubular epithelium was due to a decrease in the number of Sertoli cells and spermatogenic cells—or spermatogenesis inhibition—which was possibly due to the presence of germ cells undergoing apoptosis (Kovacevic *et al.*, 2016). The role of α -tocopherol in protecting spermatozoa from ROS and maintaining germ cell function is by reducing the production of ROS and hydroxyl radicals in hypoxic conditions and restoring endogenous homeostasis by increasing the total levels of GSH in the body and releasing free radical enzymes. The α -tocopherol inhibits oxidative stress by regulating the balance between oxidants and antioxidants, effectively protecting cells from free radical damage by increasing endogenous antioxidant levels (Oda and El Maddawi, 2012). The α -tocopherol acts as a reducing agent for hydrogen or an electron agent that can inhibit or reduce free radicals and increase antioxidants. In addition, α -tocopherol can suppress oxidative stress, including the production of ROS induced by dioxins. α -tocopherol, as an antioxidant, can be used as a free radical scavenger. If the excess free radicals in the body can be captured by antioxidants, the cells that have been damaged by free radicals can regenerate (Yin *et al.*, 2012).

These findings again prove the dangers of dioxins on male fertility based on observations of testicle histology. The use of α -tocopherol has been shown to repair testicle tissue damaged by dioxins. These findings can be used to solve the problem of male fertility decline due to exposure to dioxins. The damaged and repaired male rat fertility in this study was only limited based on the histological observations. Meanwhile, male fertility also involves the dynamics of endocrine that accompany these histological changes. Oxidative stress caused by dioxins inhibits testosterone production (Wang *et al.*, 2017) by damaging Leydig cells, derangement of other reproductive hormonal profiles (Darbandi *et al.*, 2018) and sperm parameters (Mohammadi *et al.*, 2019). Therefore, there is a need for further studies of α -tocopherol treated on dioxin induced male rats by measuring changes in GnRH, FSH, LH, testosterone levels and sperm parameters.

In conclusion, The α tocopherol administration 259 mg/kg BW/day repairs the spermatogenesis, restores

the seminiferous tubule epithelium's diameter and thickness and the number of Leydig cells in mice recovering from exposure to a toxic dose of 2,3,7,8 tetrachlorodibenzo-p-dioxin.

Disclosure statement: The authors declare there is no conflict of interest.

Acknowledgements

This study was supported by the Directorate of Research and Community Service of the Directorate General of Research and Development Strengthening of the Ministry of Research, Technology and Higher Education Contract Number: 4/AMD/E1/KP.PTNBH/2020 and 7070/UN3.14/PT/2020. The authors are grateful for it. The authors also thank Jumawan, the laboratory technician at Veterinary Pathology, Faculty of Veterinary Medicine Universitas Airlangga, for slide preparation and staining.

References

- Aitken R J and Roman S D 2008. Antioxidant system and oxidative stress in the testes. *Oxid Med Cell Longev.* 2008 Oct-Dec; 1(1): 15-24. <https://doi.org/10.4161/oxim.1.1.6843>.
- Asadi N, Bahmani M, Kheradmand A, Rafieian-Kopaei M. The Impact of Oxidative Stress on Testicular Function and the Role of Antioxidants in Improving it: A Review. *J Clin Diagn Res.* 2017;11(5):IE01-IE05. doi:10.7860/JCDR/2017/23927.9886.
- Bartosikova L, Necas J, Suchy V, Kubinova R, Vasela D, Benes L, Bartosik T, Illek J, Salplachta J, Klusakova J, Bartosova L, Strnadova V, Frana P and Franova J 2003. Monitoring of antioxidative effect of morine in alloxan-induced diabetes melitus in the laboratory rat. *Acta Vet Brno* 72 (2): 191-200. <https://doi.org/10.2754/avb200372020191>.
- Brehm R. and Steger K 2005. Regulation of Sertoli cell and germ cell differentiation. In: *Advances in Anatomy, Embryology and cell biology*, Springer-Verlag Berlin 181:2-7.
- Chandra AK, Chatterjee A, Ghosh R, and Sarkar M 2010. Vitamin E-supplementation protect chromium (VI)-induced spermatogenic and steroidogenic disorders in testicular tissues of rats. *Food Chem Toxicol* 2010 Mar;48(3):972-9. <https://doi.org/10.1016/j.fct.2010.01.008>.
- Chang HJ, Park JS, Lee EK, Kim MH, Baek MK, Kim HR, Jeong HG, Choi SY, and Jung YD 2009. Ascorbic acid suppresses the 2,3,7,8-tetrachlorodibenzo-p-dioxin (TCDD)-induced CYP1A1 expression in human HepG2 cells *Toxicol In Vitro* 2009 Jun;23(4):622-6. <https://doi.org/10.1016/j.tiv.2009.02.008>.
- Clermont Y and Perey B 2008. Quantitative Study of The Cell Population of The Seminiferous Tubules in Immature Rats. *Am J Anat* 100 (2): 353. <https://doi.org/10.1002/aja.1001000205>.
- Darbandi M, Darbandi S, Agarwal A, Sengupta P, Durairajanayagam D, Henkel R and Sadeghi MR 2018. Reactive oxygen species and male reproductive hormones. *Reprod Biol Endocrinol*

- 16(1):87. <https://doi.org/10.1186/s12958-018-0406-2>.
- Dirican EK and Kalender Y 2012. Dichlorvos-induced testicular toxicity in male rats and the protective role of vitamins C and E. *Exp Toxicol Pathol* 2012 Nov;64(7-8):821-30. <https://doi.org/10.1016/j.etp.2011.03.002>.
- Dobrzyński M, Całkosiński I, Przywitowska I, Brzoza JK, Waszkiewicz AC, Sołtan E and Parulska O 2009. Effects of Dioxins in Environmental Pollution on Development of Tooth Disorders. *Polish J Environ Stud* 18(3): 319-323.
- Ebtekar M 2004. Review paper effects of persistent organic pollutants on the immune system : the case of dioxin. *Iranian J Env Health Sci Eng*, 2004, Iranian J Env Health. *Iranian J Env Health Sci Eng* 1(2): 1-7. <http://diglib.tums.ac.ir/pub/>.
- El-Gerbed M, El-Saad AM, and Haussein AB 2015. 2, 3, 7, 8-tetrachloro-dibenzo-p-dioxin induced testicular toxicity in rats and the protective effect of quercetin: Biochemical, histopathological and immunohistochemical studies. *J Appl Pharm Sci* 5: 099-109. <https://doi.org/10.7324/JAPS.2015.50118>.
- Górnicka M, Ciecierska A, Hamułka J, Drywień M, Frąckiewicz J, Górnicki K and Wawrzyniak A 2019. α -Tocopherol Protects the Heart, Muscles, and Testes from Lipid Peroxidation in Growing Male Rats Subjected to Physical Efforts. *Oxid Med Cell Longev* 2019: 1-13. <https://doi.org/10.1155/2019/8431057>.
- Gupta P, Thompson BL, Wahlang B, Jordan CT, Zach Hilt J, Hennig B, and Dziubla T 2018. The environmental pollutant, polychlorinated biphenyls, and cardiovascular disease: a potential target for antioxidant nanotherapeutics. *Drug Deliv Transl Res*. 2018 8(3):740-759. <https://doi.org/10.1007/s13346-017-0429-9>.
- Jeyabalan A and Caritis SN 2006. Antioxidant and the prevention of preeclampsia-unresolved issues. *N Engl J Med*. 2006 Apr 27;354(17):1841-3. <https://doi.org/10.1056/NEJMe068046>.
- Kekeyama M and Tohyama C 2003. Developmental Neurotoxicity of Dioxin and Its Related Compounds Industrial Health. *Ind Health* 41(3):215-30. <https://doi.org/10.2486/indhealth.41.215>.
- Kaur P, Kaur G, Bansal MP 2006. Tertiary-butyl hydroperoxide induced oxidative stress and male reproductive activity in mice: role of transcription factor NF-kappaB and testicular antioxidant enzymes. *Reprod Toxicol* 2006 Oct;22(3):479-84. <https://doi.org/10.1016/j.reprotox.2006.03.017>.
- Kloser E, Böhmendorfer S, Brecker L, Kählig H, Netscher T, Mereiter K and Rosenau T 2011. Synthesis of 5-(Fluorophenyl)tocopherols as Novel Dioxin Receptor Antagonists. *Eur J Org Chem* 2011: 2450-2457. <https://doi.org/10.1002/ejoc.201100178>.
- Kovacevic K, Budefeld T and Majdic G 2016. Reduce Seminiferous Tubule Diameter in Mice Neonatally Exposed to Perfume. *Slov Vet Res* (43):177-183.
- Lali Z 2018. Release of Dioxins from Solid Waste Burning and its Impacts on Urban Human Population- A Review. *J Pollut Eff Cont* 6: 215. <https://doi.org/10.4172/2375-4397.1000215>.
- Latchoumycandane C and Mathur PP 2002. Effects of vitamin E on reactive oxygen species-mediated 2, 3, 7, 8-tetrachloro-dibenzo-p-dioxin toxicity in rat testis. *J Appl Toxicol* 22(5):345-51. <https://doi.org/10.1002/jat.866>.
- Lui WY and Lee WM 2009. Molecular mechanisms by which hormones and cytokines regulate cell junction dynamics in the testis. *J Mol Endocrinol* 43(2):43-51. <https://doi.org/10.1677/JME-08-0174>.
- Mathur PP and D'Cruz SC 2011. The effect of environmental contaminants on testicular function. *Asian J Androl* 13(4):585-91. <https://doi.org/10.1038/aja.2011.40>.
- Mohammadi S, Rahmani F, Hasanian SM, Beheshti F, Akbari Oryani M, Ebrahimzadeh A and Farzadfar S. Effects of dioxin on testicular histopathology, sperm parameters, and CatSper2 gene and protein expression in Naval Medical Research Institute male mice. *Andrologia* 51(11):e13411. <https://doi.org/10.1111/and.13411>.
- Murugesan P, Muthusamy T, Balasubramanian K and Arunakaran J 2007. Effects of vitamins C and E on steroidogenic enzymes mRNA expression in polychlorinated biphenyl (Aroclor 1254) exposed adult rat Leydig cells. *Toxicology* 232(3):170-82. <https://doi.org/10.1016/j.tox.2007.01.008>.
- Oda SS and El Maddawy ZK 2012. Protective effect of α -tocopherol and selenium combination on deltamethrin-induced reproductive toxicity in male rats. *Exp Toxicol Pathol* 2012 64 (7-8):813-9. <https://doi.org/10.1016/j.etp.2011.03.001>.
- Our world in data.org, 2020. <https://ourworldindata.org/plastic-pollution>, accessed 2 december 2020.
- Ramaswamy S, and Weinbauer GF 2015. Endocrine control of spermatogenesis: Role of FSH and LH/testosterone. *Spermatogenesis* 4(2):e996025. <https://doi.org/10.1080/21565562.2014.996025>.
- Ritschel WA, Vachharajani NN, Johnson RD and Hussain AS 1992. The allometric approach for interspecies scaling of pharmacokinetic parameters. *Comp Biochem Physiol C Comp Pharmacol Toxicol* 103(2):249-53. [https://doi.org/10.1016/0742-8413\(92\)90003-p](https://doi.org/10.1016/0742-8413(92)90003-p).
- Ruiz-Ramos M, Vargas LA, Fortoul Van der Goes TI, Cervantes-Sandoval A and Mendoza-Nunez VM 2010. Supplementation of ascorbic acid and α -tocopherol is useful to preventing bone loss linked to oxidative stress in elderly. *J Nutr Health Aging* 14(6):467-72. <https://doi.org/10.1007/s12603-010-0099-5>.
- Schultz R, Suominen J, Varre T, Hakovirta H, Parvinen M and Toppari J 2003. Expression of aryl hydrocarbon receptor and aryl hydrocarbon receptor nuclear translocator messenger ribonucleic acids and proteins in rat and human testis. *Endocrinology* 144(3):767-76. <https://doi.org/10.1210/en.2002-220642>.
- Smith LB and Walker WH 2014. The regulation of spermatogenesis by androgens. *Semin Cell Dev Biol* 30:2-13. <https://doi.org/10.1016/j.semcdb.2014.02.012>.
- Soleimani Mehranjani M and Taefi R 2012. The protective role of vitamin E on the testicular tissue in rats exposed to sodium arsenite during the

- prenatal stage till sex maturity: A stereological analysis. *Iran J Reprod Med.* 10(6):571-80. PMID: 25246929; PMCID: PMC4169852.
- Valko M, Leibfritz D, Moncol J, Cronin MTD, Mazur M and Telser J 2007. Review: Free radicals and antioxidants in normal physiological functions and human disease. *Int J Biochem Cell Biol* 39(1):44-84. <https://doi.org/10.1016/j.biocel.2006.07.001>.
- Vigueras-Villaseñor RM, Ojeda I, Gutierrez-Pérez O, Chavez-Saldaña M, Cuevas O, Maria DS and Rojas-Castañeda JC 2011. Protective effect of α -tocopherol on damage to rat testes by experimental cryptorchidism. *Int J Exp Pathol* 92(2):131-9. <https://doi.org/10.1111/j.1365-2613.2010.00757.x>.
- Walker WH 2009. Molecular mechanisms of testosterone action in spermatogenesis. *Steroids* 74 (7): 602-607. <https://doi.org/10.1016/j.steroids.2008.11.017>.
- Wang Y, Chen F, Ye L, Zirkin B and Chen H 2017. Steroidogenesis in Leydig cells: effects of aging and environmental factors. *Reproduction.* 154(4):R111-R122. <https://doi.org/10.1530/REP-17-0064>.
- Yang J, Lin H and Mau J 2002. Antioxidant properties of several commercial mushrooms. *Food Chemistry* 77 (2) :229-235. [https://doi.org/10.1016/S0308-8146\(01\)00342-9](https://doi.org/10.1016/S0308-8146(01)00342-9).
- Yin HP, Xu JP, Zhou XQ and Wang Y 2012. Effects of α -tocopherol on reproductive hormones and testis structure in chronic dioxin-treated mice. *Toxicol Ind Health* 28(2):152-61. <https://doi.org/10.1177/0748233711408381>.
- Yonemoto J 2000. The Effects of Dioxin on Reproduction and Development. *Ind Health* 38 (3): 259-68. <https://doi.org/10.2486/indhealth.38.259>.
- Yoon CY, Park M, Kim BH, Park JY, Park MS, Jeong YK, Kwon H, Jung HK, Kang H, Lee YS and Lee BJ 2006. Gene Expression Profile by 2,3,7,8-Tetrachlorodibenzo-p-dioxin in the Liver of Wild-Type (AhR +/+) and Aryl Hydrocarbon Receptor-Deficient (AhR -/-) Mice. *J Vet Med Sci.* 68(7): 663-668. <https://doi.org/10.1292/jvms.68.663>.
- Zhou B, Wang X, Li F, Wang Y, Yang L, Zhen X and Tan W 2017. Mitochondrial activity and oxidative stress functions are influenced by the activation of AhR-induced CYP1A1 overexpression in cardiomyocytes. *Mol Med Rep* 16 (1): 174-180. <https://doi.org/10.3892/mmr.2017.6580>.