

6-1-2021

## The effect of low-level laser therapy on rat unicortical femoral defect

Latif Emrah Yanmaz

Ugur Ersoz

Sitkican Okur

Betul Apaydin Yildirim

Selim Comakli

*See next page for additional authors*

Follow this and additional works at: <https://digital.car.chula.ac.th/tjvm>



Part of the [Veterinary Medicine Commons](#)

---

### Recommended Citation

Yanmaz, Latif Emrah; Ersoz, Ugur; Okur, Sitkican; Yildirim, Betul Apaydin; Comakli, Selim; Sağlam, Yavuz Selim; Dogan, Elif; Karatas, Ozhan; Turgut, Ferda; and Okumuş, Zafer (2021) "The effect of low-level laser therapy on rat unicortical femoral defect," *The Thai Journal of Veterinary Medicine*: Vol. 51: Iss. 2, Article 10.

Available at: <https://digital.car.chula.ac.th/tjvm/vol51/iss2/10>

This Article is brought to you for free and open access by the Chulalongkorn Journal Online (CUJO) at Chula Digital Collections. It has been accepted for inclusion in The Thai Journal of Veterinary Medicine by an authorized editor of Chula Digital Collections. For more information, please contact [ChulaDC@car.chula.ac.th](mailto:ChulaDC@car.chula.ac.th).

---

## The effect of low-level laser therapy on rat unicortical femoral defect

### Authors

Latif Emrah Yanmaz, Ugur Ersoz, Sitkican Okur, Betul Apaydin Yildirim, Selim Comakli, Yavuz Selim Sađlam, Elif Dogan, Ozhan Karatas, Ferda Turgut, and Zafer Okumuş

## The effect of low-level laser therapy on rat unicortical femoral defect

Latif Emrah Yanmaz<sup>1</sup> Ugur Ersoz<sup>1\*</sup> Sitkican Okur<sup>1</sup> Betul Apaydin Yildirim<sup>2</sup> Selim Comakli<sup>3</sup>

Yavuz Selim Sağlam<sup>3</sup> Elif Dogan<sup>4</sup> Ozhan Karatas<sup>5</sup> Ferda Turgut<sup>1</sup> Zafer Okumuş<sup>1</sup>

### Abstract

The aim of this study was to determine the effectiveness of low-level laser therapy (LLLT) in the healing of experimentally created unicortical defect (UCD) of rat femurs. Twenty-four adult Wister rats were randomly divided into 2 groups: UCD and UCD+LLLT. The animals were subdivided into 3 groups (each group had 4 animals) and then they sacrificed at day 8, 15 and 22 for radiological, pathological and biochemical analysis. Bone healing was significantly different between the groups at day 15 and 22 ( $P < 0.05$ ), while bone formation was significantly increased in the UCD+LLLT group at day 22 compared to the UCD group ( $P < 0.05$ ). On histopathological examination, significant difference was found between the UCD and UCD+LLLT groups on the 22nd day ( $P < 0.05$ ) while there was no difference on the 8th and 15th day. In the UCD group, the plasma Alkaline phosphatase activity decreased on the 15th and 22nd days, Calcium on the 15th day and Phosphorus on the 8th and 22nd days compared to the UCD+LLLT group. In addition, Glutathione levels, Plasma Catalase, Glutathione Peroxidase and Superoxide Dismutase activity significantly reduced in the UCD group compared with UCD+LLLT on the 8th, 15th and 22nd day ( $P < 0.05$ ). In conclusion, LLLT applied at a dose of 904 $\mu$ m accelerates fracture healing in UCD of a rat's femur. However, this effect shows an increase after the 22nd day of LLLT application.

---

**Keywords:** Bone, Defect, Femur, Healing, Rat

<sup>1</sup>Department of Surgery, Veterinary Faculty, Ataturk University, Erzurum, 25240 TURKEY

<sup>2</sup>Department of Biochemistry, Veterinary Faculty, Ataturk University, Erzurum, 25240 TURKEY

<sup>3</sup>Department of Pathology, Veterinary Faculty, Ataturk University, Erzurum, 25240 TURKEY

<sup>4</sup>Department of Surgery, Veterinary Faculty, Kastamonu University, Kastamonu, 37150, TURKEY

<sup>5</sup>Department of Pathology, Veterinary Faculty, Cumhuriyet University, Sivas, 58140, TURKEY

\*Correspondence: [ugur.ersoz@atauni.edu.tr](mailto:ugur.ersoz@atauni.edu.tr) (U. Ersoz)

Received: January 13, 2021.

Accepted: February 17, 2021.

doi: <https://doi.org/10.14456/tjvm.2021.35>

## Introduction

Bone repair is a highly complex regenerative process that results from many biological activities involving proteins and cells. During this process, possible disruptions and impairments in bone regeneration can result in delayed consolidation or non-union. Many biophysical and biochemical advances are being investigated to minimize the time of bone consolidation and to reduce possible complications associated with an abnormal regeneration process (Hadjiargyrou *et al.*, 1998; Sena *et al.*, 2005).

Low-level laser therapy (LLLT) can accelerate bone healing by means of its positive effect on bone metabolism and fracture consolidation. The advantages of the technique include easy accessibility, non-requirement of the concomitant use of drugs, safe application for the tissue and applicability over surgical implants (Sella *et al.*, 2015). Some authors claim that LLLT accelerate bone formation by increasing osteoblastic activity, vascularization, organization of collagen fibers and Adenosine triphosphate (ATP) levels (Lirani *et al.*, 2006). Moreover, LLLT appears to speed up the fracture healing process by increasing the callus volume and bone mineral density (Lirani *et al.*, 2006; Liu *et al.*, 2007).

Unicortical defect (UCD) has started to be used more frequently in experimental studies due to less tissue damage and no requirement of major intervention (Patrocinio *et al.*, 2014; Bayat *et al.*, 2016). Besides, intensity of the formation of callus at the cortical edges and the unnecessary use of special implants make UCD studies attractive (Barushka *et al.*, 1995; Yaakobi *et al.*, 1996; Pinheiro *et al.*, 2003). For these reasons, the aim of this study was to detect the effectiveness of LLLT on rat femoral UCD.

## Materials and Methods

This study was approved by the Ethics Committee for Animal Experimentation (2015/155), Faculty of Veterinary Medicine, Atatürk University, Erzurum, Turkey. The study was carried out during the period of January 2017 to June 2018 in the Atatürk University Medical Experimental Application and Research Center, Erzurum, Turkey. Twenty-four adult male Wistar rats (aged 12 weeks and weighing  $350 \pm 50$  g) were used. They were maintained under a controlled temperature ( $22 \pm 2^\circ\text{C}$ ) and light-dark environment. Rats had free access to water and commercial diet.

The rats were randomly divided into 2 groups with 12 animals in each group: UCD+ LLLT group and a control group (UCD without LLLT). The rats were sacrificed with a lethal dose of anesthetic substance (Thiopental Sodyum, Pentil Sodyum 1 g İ.E Ulagay İlaç Sanayi Turkey AŞ.) on days 8 (n = 8, 4 animals from each group), 15 (n = 8, 4 animals from each group) and 22 (n = 8, 4 animals from each group) for radiological, histopathological and biochemical analysis.

**Surgery:** General anesthesia was achieved by intramuscular administration of 114 mg/kg Ketamine (Ketasol %10 10 ml İnterhas-Richter Pharma Wels Austria) and 11.4 mg/kg Xylazine (Xylazin Bio %2 50 ml Bioveta) combination in a same syringe. Each

animal was placed in the left lateral position, skin was shaved and cleaned with 70% ethanol, then the craniolateral skin incision was performed. After the subcutaneous and fascia incision, the femur was reached at the base of the vastus lateralis and rectus femoris muscles. Then, the UCD was created in the middle diaphysis of the femur with a 1 mm diameter trephine drill (Driller K model BLM 600 plus 1 mm diameter drill, 690 rpm). The 5 mm proximal to the right femoral knee, 0.8 mm depth cortical bone defects were obtained by drilling one hole through the anterior cortical bone with a 1 mm low speed drill, after which the remaining bone and periosteum between the drill holes, as well as the bone marrow corresponding to the defect, was removed. All defects were left empty (Lirani *et al.*, 2006; He *et al.*, 2011). The right femoral diaphysis defect was performed by drilling under constant sterile saline irrigation and aspiration. The drill was withdrawn as soon as cortical resistance was lost as described previously (Arnold *et al.*, 1998). For closure, the muscles were sutured with 2.0 vicryl (Ethicon, Johnson & Johnson) and the skin was closed with continuous suturing with 3.0 silk (Dogsan, Turkey).

**Laser Application:** In the group UCD+LLLT, laser therapy was applied to the inner face of the right femur with a mono-diode laser probe (MLA1/25) and a GaAs (gallium arsenide) laser device (Lasermed 2200, Eme Phsio Italy) by direct contact with the skin once a day, starting the day after the operation. The laser device was set as  $\lambda = 904 \mu\text{m}$ , 7000 Hz, 17 Mw, in continuous mode and exposure time was 60 seconds (Table 1). Laser irradiation started immediately after the surgery and was applied transcutaneously upon a single point directly to the defect (using direct contact to the skin technique) and it was repeated every 24 hours until the sacrificing day.

**Radiological Analysis:** For radiographical examination, the craniocaudal and mediolateral positions of the femur were taken with a stationary x-ray machine (Mex-100, Oberhausen-Germany) at the end of the experimental period (8th, 15th, and 22nd days). Tomographic images of the femur were scanned in lateral recumbency by Toshiba Asteion 4-slice CT System (Toshiba, Tokyo, JAPAN) on days 8, 15 and 22. Radiographic and tomographic images were evaluated using a modified scoring system (O'Neill *et al.*, 2012; Tawonsawatruk *et al.*, 2014).

**Histopathological Analysis:** The femur samples of the rats were removed and fixed in 10% neutral phosphate buffered formalin. After the detection process, they were decalcified in 10% HNO<sub>3</sub>. Tissues were dehydrated in 70–99.9% ethanol series, cleared in xylene and embedded in paraffin. Tissue sections were cut into about 5  $\mu\text{m}$  thickness using a microtome (LEICA RM 2255) and put onto slides. They were stained with hematoxylin and eosin (H & E) and masson's trichrome, examined and photographed using a light microscope (Olympus BX 51, DP72 Camera Attachment). The evaluation was made as suggested by Emery *et al.*, (1994) (Table 2).

**Table 1** LLLT parameters for each application.

	UCD Group	UCD+LLLT Group
Laser Frequency	-	Continuous Output
Optical Output	-	25 mW
Energy Density	-	1 J/cm <sup>2</sup>
Power Density	-	17 mW
Wave Length	-	904 μm
Treatment Time	60 seconds	60 seconds
Irridation Area	Direct to the skin (1cm <sup>2</sup> )	Direct to the skin (1 cm <sup>2</sup> )

**Table 2** Histological scoring scale for bone healing (Emery et al., 1994).

Score Point	Tissue Present
7	Bone only
6	More bone than fibrocartilage
5	More fibrocartilage than bone
4	Fibrocartilage only
3	More fibrocartilage than fibrous tissue
2	More fibrous tissue than fibrocartilage
1	Fibrous tissue
0	Empty cleft

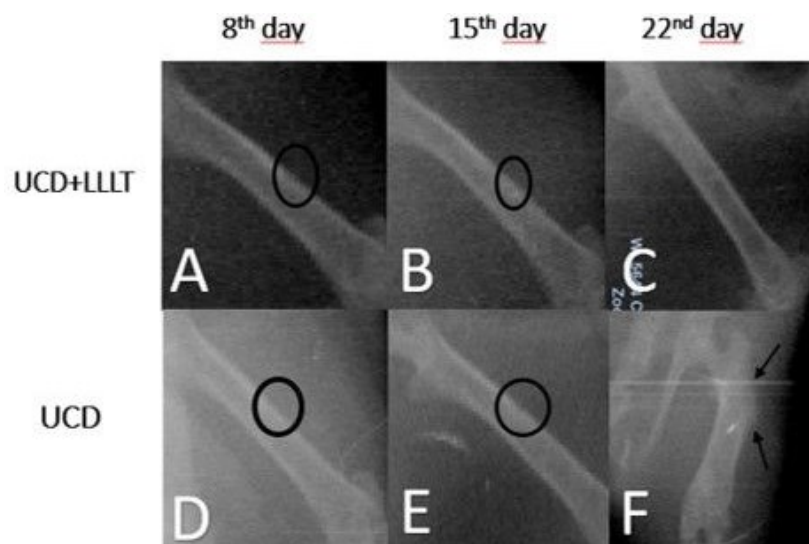
**Biochemical Analysis:** The blood samples were taken directly from the heart and the samples were transferred to lithium heparin tubes and centrifuged at 3000 rpm, +4°C for 10 minutes and their plasma was separated and stored in a deep freeze at -20°C until biochemical analysis. TML (Diagnostic Medical Products, Ankara, Turkey) commercial kit was used in the analysis for Alkaline phosphatase (ALP), Calcium (Ca) and Phosphorus (P) determinations. Plasma malondialdehyde (MDA) (Yoshioka et al., 1979), Glutathione (GSH) levels (Tietze, 1969), plasma catalase (CAT) (Goth, 1991), superoxide dismutase (SOD) (Sun et al., 1988) and glutathione peroxidase (GPx) activities (Matkovic, 1988) were measured with Biotek ELISA Reader (Bio Tek μQuant MQX200 Elisa reader/USA).

**Statistical Analysis:** One-way analysis of variance was performed on days 8, 15, and 22 to detect the significance among the same group. Tukey's multiple range test was applied and represented as Mean±Standard Error (SE) (values with  $P < 0.05$  were considered significantly different). An independent test was used to compare UCD and LLLT+UCD groups on the same day. Differences between groups in the

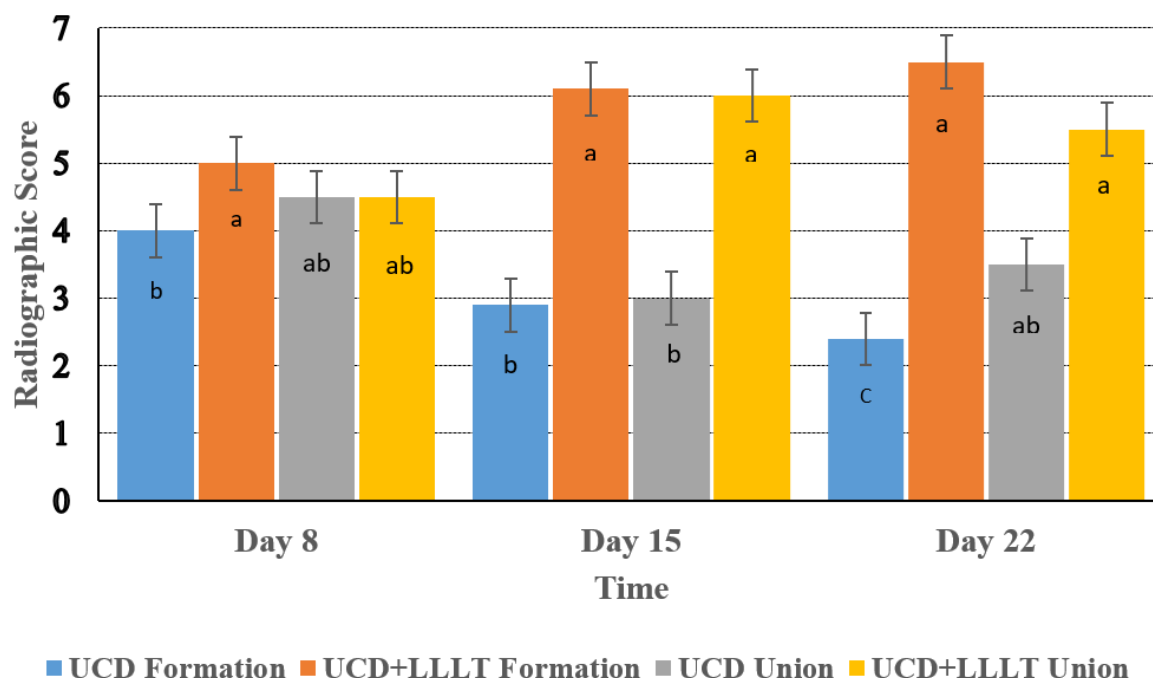
analysis of radiographical scores were made using the Mann-Whitney Test. All data was analyzed using the statistical package for SPSS software version 22.0 program (IBM software, Inc. Chicago, USA).

## Results

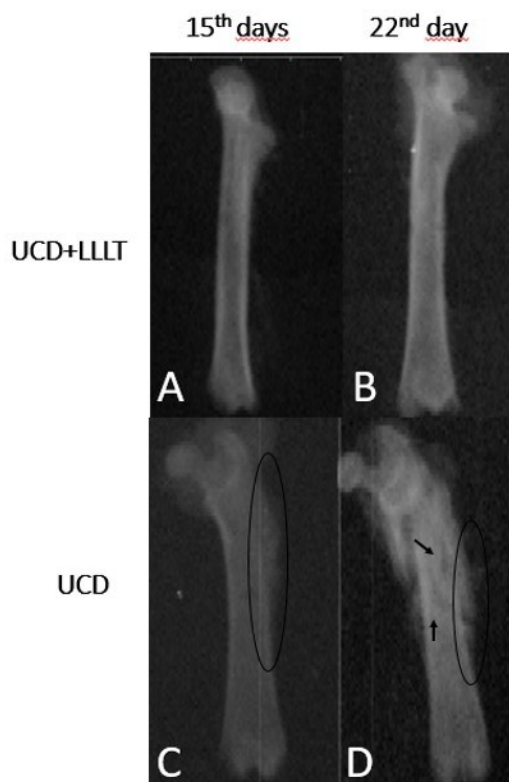
**Radiological findings:** In radiography, bone formation was not observed in the defect area on the 8th day and cortical bone volume increased on the 15th and 22nd days in both groups. External callus was noted in one case in the UCD group at day 22 (Fig. 1). Bone healing was significantly different between groups at day 15 and 22 ( $P < 0.05$ ), while bone formation was significantly increased in the UCD+LLLT group at day 22 compared to the UCD group ( $P < 0.05$ ) (Fig. 2). The bone was clearly visible on tomography. Tomography confirmed that the bone integrity was not compromised during the creation of UCD and that the defect was limited to a single cortex. While bone healing progressed more regularly in the UCD+LLLT group, external callus was observed in the bone tissue on the 15th and 22nd days in the UCD group. In addition, bone fractures were seen at day 22 in UCD group (Fig. 3).



**Figure 1** Radiographic images by group and time. Defect can be seen on the 8th and 15th days (A, B) in Group UCD+LLLT, it is not visible on day 22 (C). Likewise, defect can be seen on the 8th and 15th days in group UCD (D, E) However, the external callus in the defect area was noted (F) in one case on the 22nd day. Circle: defect area, black arrows: external callus.



**Figure 2** On day 22, both bone formation and bone union were significantly increased in the UCD+LLLT group compared to the UCD group. Different superscripts among groups differ ( $P < 0.05$ ).

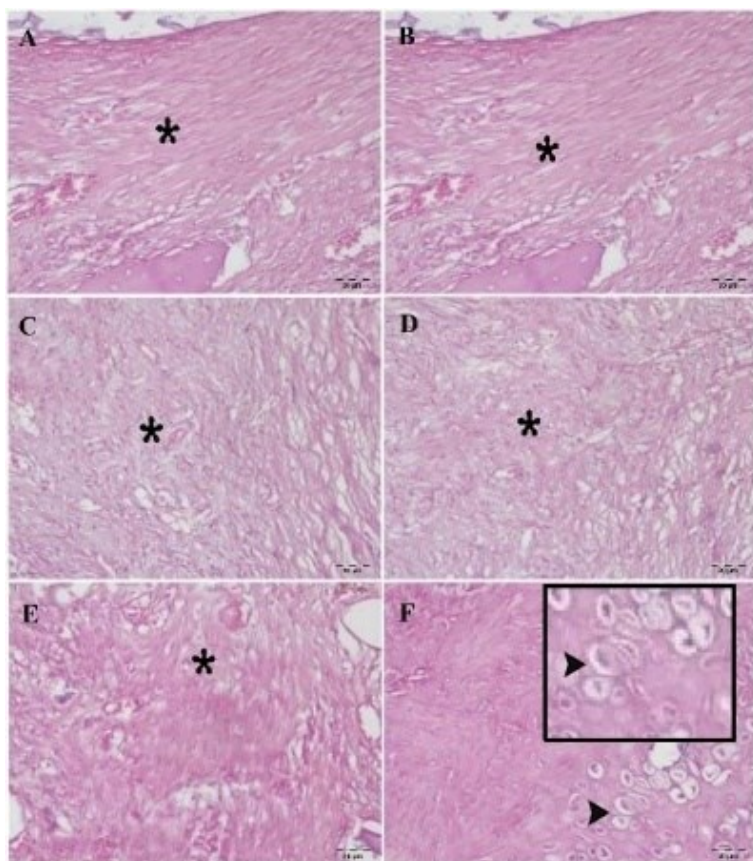


**Figure 3** While defective areas were filled with bone tissue on days 15 and 22 in the UCD+LLLT group (A, B), External callus formation (C) and bone fractures (D) on the 22nd day were noted in the UCD group. Circle: external callus, black arrows: fractured bone.

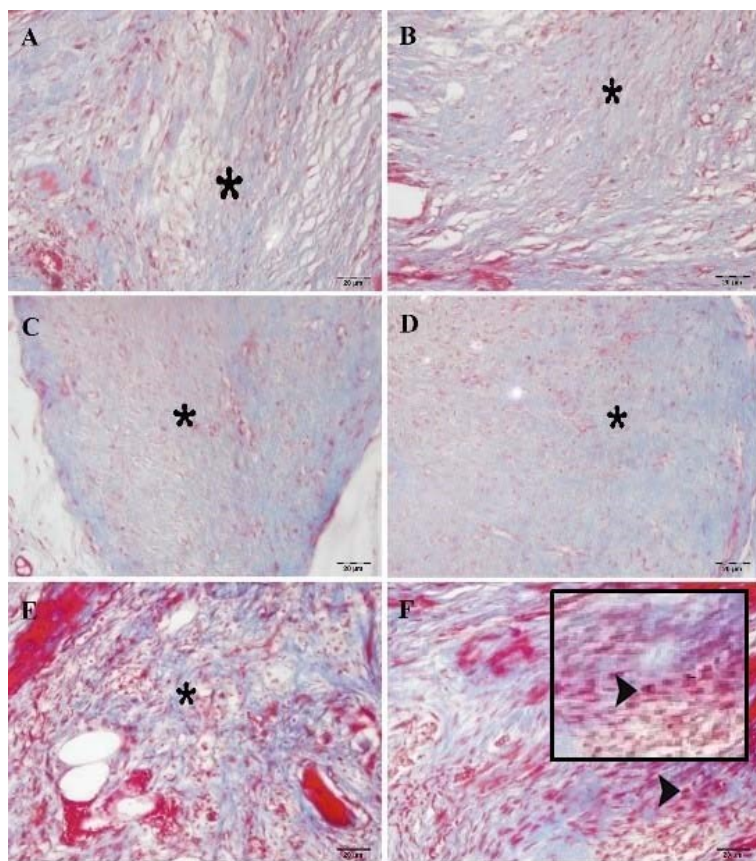
**Histopathological findings:** On histopathological examination, a significant difference was found between the UCD and UCD+LLLT groups on the 22nd day ( $P < 0.05$ ) while there was no difference on the 8th and 15th day (Fig. 4). A fibrous tissue was formed at a similar level in the fracture area of the UCD and UCD+LLLT groups on the 8th and 15th day. On the 22nd day, fibrous tissue that had started to mature in the UCD group was replaced by chondrocytes in the UCD+LLLT group (Fig. 5).

**Biochemical findings:** Biochemical differences between groups UCD and UCD+LLLT are shown in Table 3. In this study, plasma MDA levels of the UCD group increased significantly compared with the UCD+LLLT group on the 8th, 15th and 22nd day. In the UCD group, the plasma ALP activities decreased on the 15th and 22nd days, Ca on the 15th day and P on the 8th and 22nd days compared to the UCD+LLLT group. Besides, GSH levels, CAT, GPx and SOD activity significantly reduced in the UCD group compared with UCD+LLLT on the 8th, 15th and 22nd day ( $P < 0.05$ ).





**Figure 4** (A) -8th day UCD, (B) UCD+LLLT and UCD groups on day 8, (C) UCD group, (D) UCD+LLLT and UCD groups on 15th day, (E) Fibrous tissue formation in UCD groups 22nd day (\*), (F) 22nd day chondrocyte formation (arrowhead) in UCD+LLLT group. (HE).



**Figure 5** (A) -8th UCD, (B) 8th day UCD+LLLT group, (C) 15th day UCD, (D) 15th UCD+LLLT group, (E) 22nd day of fibrous tissue formation in UCD groups (\*), (F) 22nd day chondrocyte formation (arrowhead) in the UCD+LLLT group. (MT).

**Table 3** Biochemical differences in UCD and UCD+LLLT groups.

	DAY	UCD GROUP	UCD+ LLLT GROUP	P
ALP (U/L)	8 <sup>th</sup>	119.30±0.67 <sup>aA</sup>	114.93±0.94 <sup>B</sup>	**
	15 <sup>th</sup>	111.61±0.59 <sup>bB</sup>	115.16±0.66 <sup>A</sup>	**
	22 <sup>nd</sup>	102.67±0.57 <sup>cB</sup>	115.20±0.56 <sup>A</sup>	***
P		***	NS	
Ca (mmol/L)	8 <sup>th</sup>	9.71±0.00 <sup>aA</sup>	9.40±0.01 <sup>aB</sup>	***
	15 <sup>th</sup>	9.21±0.01 <sup>cB</sup>	9.30±0.00 <sup>bA</sup>	***
	22 <sup>nd</sup>	9.38±0.01 <sup>bA</sup>	9.33±0.01 <sup>bB</sup>	**
P		***	***	
P (mmol/L)	8 <sup>th</sup>	7.30±0.01 <sup>aB</sup>	7.61±0.00 <sup>aA</sup>	***
	15 <sup>th</sup>	7.23±0.01 <sup>bA</sup>	7.20±0.00 <sup>bB</sup>	*
	22 <sup>nd</sup>	7.11±0.01 <sup>cB</sup>	7.23±0.01 <sup>bA</sup>	***
P		***	***	
CAT (kU/L)	8 <sup>th</sup>	167.23±3.25 <sup>aB</sup>	197.78±1.93 <sup>A</sup>	***
	15 <sup>th</sup>	119.84±2.24 <sup>bB</sup>	199.31±2.52 <sup>A</sup>	***
	22 <sup>nd</sup>	117.82±1.06 <sup>bB</sup>	199.92±2.63 <sup>A</sup>	***
P		***	NS	
GPx (U/mL)	8 <sup>th</sup>	0.21±0.01 <sup>aB</sup>	0.27±0.00 <sup>A</sup>	***
	15 <sup>th</sup>	0.18±0.01 <sup>bB</sup>	0.26±0.01 <sup>A</sup>	***
	22 <sup>nd</sup>	0.18±0.01 <sup>bB</sup>	0.28±0.01 <sup>A</sup>	***
P		*	NS	
GSH (mmol/L) <sub>SEP</sub>	8 <sup>th</sup>	0.92±0.02 <sup>B</sup>	0.98±0.06 <sup>A</sup>	NS
	15 <sup>th</sup>	0.90±0.02 <sup>B</sup>	0.97±0.02 <sup>A</sup>	*
	22 <sup>nd</sup>	0.86±0.01 <sup>B</sup>	0.99±0.02 <sup>A</sup>	***
P		NS	NS	
MDA (mmol/L) <sub>SEP</sub>	8 <sup>th</sup>	27.20±0.63 <sup>bA</sup>	22.85±0.37 <sup>B</sup>	***
	15 <sup>th</sup>	27.03±0.53 <sup>bA</sup>	21.90±0.68 <sup>B</sup>	***
	22 <sup>nd</sup>	29.34±0.55 <sup>aA</sup>	21.25±0.72 <sup>B</sup>	***
P		*	NS	
SOD(U/mL)	8 <sup>th</sup>	24.18±0.98 <sup>aB</sup>	35.54±0.97 <sup>A</sup>	***
	15 <sup>th</sup>	20.75±0.85 <sup>bB</sup>	35.38±0.64 <sup>A</sup>	***
	22 <sup>nd</sup>	17.27±0.38 <sup>cB</sup>	37.72±1.00 <sup>A</sup>	***
P		***	NS	

\*  $P < 0.05$ , \*\*  $P < 0.01$ , \*\*\*  $P < 0.00$ , NS: Non significant.

<sup>a,b,c</sup>: Values with different superscripts within one column differ significantly ( $P < 0.05$ ).

<sup>A,B</sup>: Values with different superscripts within one row differ significantly ( $P < 0.05$ ).

## Discussion

This study aimed to investigate the effectiveness of LLLT on experimentally created femoral fractures in healthy rats. Although many studies have been conducted on the effect of laser therapy on fractures, the therapeutic effect of lasers has not been fully explained (Liu *et al.*, 2007). The effecting factors such as wavelength and exposure time of LLLT are still under investigation (Mota *et al.*, 2013). While different LLLT dose levels have been used in cortical fractures (Bayat *et al.*, 2018), in this study, the effects of 904  $\mu\text{m}/17\text{ mW}$  and 1  $\text{Jcm}^2$  low-level laser dose on femoral UCD were evaluated. Various LLLT regimens of irradiation procedure have been used, however no standardization exists about the dose and irradiation zone (Pires-Oliveira *et al.*, 2010). In this study, a laser was applied to a single point of the rat lateral femur for 60 seconds. Freitas *et al.*, (2000) also applied the laser application vertically from a single point for 30 seconds, 5 minutes and 15 minutes. They have reported that the group in which they applied lasers at a dose of 94.7 J for 15 minutes showed better values at the end of the experiment. Although Freitas and her colleagues used different doses, they found differences between the groups irradiated and non-irradiated at 8 and 15 days as a result of irradiation from a single point (Freitas *et al.*, 2000). Yaakobi *et al.*, (1996) applied LLLT to a single point and they observed, in both, biochemical values and calcification levels on the 11th,

13th and 15th days of their study (Yaakobi *et al.*, 1996). In our study, no statistically significant difference was observed on histopathological examination at day 8, but the findings at day 15 and 22 were consistent with previous reports (Sun *et al.*, 1988; Freitas *et al.*, 2000; Tim *et al.*, 2014).

Laser irradiation increases molecular oxygen consumption and can stimulate cell biochemical reactions and mitochondrial respiration with ATP synthesis. These effects can increase the synthesis of DNA, RNA and cell cycle regulatory proteins, thus promoting cell proliferation (Tim *et al.*, 2014). As a result, although LLLT seems to have an accelerating effect on bone healing, it is thought that time is required for these physiological events. Besides, exposure time and application dose are thought to play an important role in the effect of LLLT (Bayat *et al.*, 2018). However, a previous study has reported that 904  $\mu\text{m}$  50 mJ LLLT dose resulted in irregular trabecular formation during fracture healing on the 7<sup>th</sup> day (Pires *et al.*, 2010). In the current study, a fibrous callus in the fracture area was observed at day 15. This formation was replaced by chondrocytes at the day of 22. These findings showed similarity with a previous report (Garavello *et al.*, 2003).

Radiography and computed tomography were conveniently used to evaluate bone healing in this study. In radiography, bone formation was not observed in the defect area on the 8th day and cortical bone volume increased on the 15th and 22nd days in



both groups. We observed significant difference in radiographic evaluations on days 15 and 22. External callus was noted in one case in the UCD group at day 22. Previous study observed clear radiographic differences after the 28th day (Bigham *et al.*, 2008). For this reason, we recommend extending the working period for future experiments.

The main limitation of our study was the diameter of UCD, which was created with a 1 mm bur tip. Based on our study it can be said that a thicker bur tip is more suitable for computed tomographic and radiographic evaluations. Previous study has stated that a 2.8 mm drill has been found suitable for radiographic evaluation of rats femur (Barbosa *et al.*, 2013).

Osteoclasts and inflammatory cells appeared to play an important role in the formation of oxidative stress in the early healing process of the fracture as they produce reactive oxygen intermediates (Foschi *et al.*, 1990; Garrett *et al.*, 1990; Cornell and Lane, 1992). Reactive oxygen intermediates damage cellular proteins and nucleic acids, inducing lipid peroxidation and causing cell membrane destruction and cellular damage. In this study, the formation of oxygen free radicals increased during the fracture healing process and this continued for 22 days after the UCD formation. Therefore, measurement of MDA, which is the end product of lipid peroxidation, is widely used (Suzuki and Packer, 1993). In this study, plasma MDA levels of the UCD group increased significantly compared with the UCD+LLLT group on the 8th, 15th and 22nd day. Moreover, GSH, GPx, SOD and CAT activities increased in the laser treated group compared to the UCD group. So, it can be said that laser application has positive effects on fracture healing by regulating antioxidant enzyme activity and suppressing the harmful effects of ROS. During the normal healing process, osteoblasts express antioxidant enzymes (SOD, CAT, GPx) to induce osteoblast differentiation and convert ROS to O and H<sub>2</sub>O. In case of significant bone defects, high ROS causes oxidative stress and decreases the regenerative capacity of the bone by inhibiting osteogenesis. Therefore, the number of studies on the role of oxidative stress in various fractures has increased in recent years (Zhang *et al.*, 2011). Jówko *et al.*, (2019) found that LLLT could protect the enzymatic antioxidant system from degradation and shorten the inflammation process (Jówko *et al.*, 2019).

In conclusion, LLLT applied at a dose of 904µm accelerates fracture healing in UCD of rat femurs. However, this effect shows an increase after the 22nd day of LLLT application.

### References

- Arnold M, Stas P, Kummermehr J, Schultz HS and Trott KR 1998. Radiation-induced impairment of bone healing in the rat femur: effects of radiation dose, sequence and interval between surgery and irradiation. *Radiother. Oncol.* 48(3): 259-265.
- Barbosa D, De Souza RA, Xavier M, Da Silva FF, Arisawa EL and Villaverde AGJB 2013. Effects of low-level laser therapy (LLLT) on bone repair in rats: optical densitometry analysis. *Lasers Med. Sci.* 28(2): 651-656.
- Barushka O, Yaakobi T and Oron U 1995. Effect of low-energy laser (He-Ne) irradiation on the process of bone repair in the rat tibia. *Bone.* 16(1): 47-55.
- Bayat M, Fridoni M, Nejati H, Mostafavinia A, Salimi M, Ghatrehsamani M, Abdollahifar Ma, Najar A, Bayat S and Rezaei F 2016. An evaluation of the effect of pulsed wave low-level laser therapy on the biomechanical properties of the vertebral body in two experimental osteoporosis rat models. *Lasers Med. Sci.* 31(2): 305-314.
- Bayat M, Virdi A, Jalalifirouzkouhi R and Rezaei F 2018. Comparison of effects of LLLT and LIPUS on fracture healing in animal models and patients: A systematic review. *Prog. Biophys. Mol. Biol.* 132: 3-22.
- Bigham A, Dehghani S, Shafiei Z and Nezhad ST 2008. Xenogenic demineralized bone matrix and fresh autogenous cortical bone effects on experimental bone healing: radiological, histopathological and biomechanical evaluation. *J. Orthop. Traumatol.* 9(2): 73-80.
- Cornell CN and Lane JM 1992. Newest factors in fracture healing. *Clin. Orthop. Relat. Res.* 277: 297-311.
- Emery SE, Brazinski MS, Koka A, Bensusan JS and Stevenson S 1994. The biological and biomechanical effects of irradiation on anterior spinal bone grafts in a canine model. *J. Bone Joint Surg. Am.* 76(4): 540-548.
- Foschi D, Castoldi L, Radaelli E, Abelli P, Calderini G, Rastrelli A, Mariscotti C, Marazzi M and Trabucchi E 1990. Hyaluronic acid prevents oxygen free-radical damage to granulation tissue: a study in rats. *Int. J. Tissue React.* 12(6): 333.
- Freitas I, Baranauskas V and Cruz HM 2000. Laser effects on osteogenesis. *Appl. Surf. Sci.* 154: 548-554.
- Garavello I, Baranauskas V, Joazeiro P, Padovani C, Dal Pai-Silva M and Da Cruz-Höfling MA 2003. Low-power laser irradiation improves histomorphometrical parameters and bone matrix organization during tibia wound healing in rats. *J. Photoch. Photobio. B.* 70(2): 81-89.
- Garrett I, Boyce B, Oreffo R, Bonewald L, Poser J and Mundy G 1990. Oxygen-derived free radicals stimulate osteoclastic bone resorption in rodent bone in vitro and in vivo. *J. Clin. Invest.* 85(3): 632-639.
- Goth L 1991. A simple method for determination of serum catalase activity and revision of reference range. *Clin. Chim. Acta.* 196(2-3): 143-151.
- Hadjiargyrou M, McLeod K, Ryaby JP and Rubin C 1998. Enhancement of fracture healing by low intensity ultrasound. *Clin. Orthop. Relat. Res.* 355: 216-229.
- He YX, Zhang G, Pan XH, Liu Z, Zheng LZ, Chan CW, Qin L 2011. Impaired bone healing pattern in mice with ovariectomy-induced osteoporosis: A drill-hole defect model. *Bone.* 48(6): 1388-1400.
- Jówko E, Plaszewski M, Cieśliński M, Sacewicz T, Cieśliński I and Jarocka M 2019. The effect of low level laser irradiation on oxidative stress, muscle damage and function following neuromuscular electrical stimulation. A double blind, randomised,

- crossover trial. *BMC Sports Sci. Med. Rehabil.* 11(1): 38.
- Lirani-Galvão AP, Jorgetti V and Da Silva OL 2006. Comparative study of how low-level laser therapy and low-intensity pulsed ultrasound affect bone repair in rats. *Photomed Laser Surg.* 24(6): 735-740.
- Liu X, Lyon R, Meier HT, Thometz J and Haworth ST 2007. Effect of lower-level laser therapy on rabbit tibial fracture. *Photomed Laser Surg.* 25(6): 487-494.
- Matkovic B 1988. Determination of enzyme activity in lipid peroxidation and glutathione pathways. *Lab. Diagn.* 15: 248-250.
- Mota F, Belo M, Beletti M, Okubo R, Prado E and Casale R 2013. Low-power laser therapy for repairing acute and chronic-phase bone lesions. *Res. Vet. Sci.* 94(1): 105-110.
- O'Neill KR, Stutz CM, Mignemi NA, Burns MC, Murry MR, Nyman JS and Schoenecker JG 2012. Micro-computed tomography assessment of the progression of fracture healing in mice. *Bone.* 50(6): 1357-1367.
- Patrocínio-Silva TL, de Souza AF, Goulart RL, Pegorari CF, Oliveira JR, Fernandes K, Magri A, Pereira RR, Araki DR and Nagaoka MR 2014. The effects of low-level laser irradiation on bone tissue in diabetic rats. *Lasers Med. Sci.* 29(4): 1357-1364.
- Pinheiro ALB, Limeira Júnior FDA, Gerbi MEM, Ramalho LMP, Marzola C, Ponzi E AC, Soares AO, De Carvalho LCB, Lima HCV and Goncalves TO 2003. Effect of 830-nm laser light on the repair of bone defects grafted with inorganic bovine bone and decalcified cortical osseus membrane. *J. Clin. Laser Med. Surg.* 21(5): 301-306.
- Pires-Oliveira D, Oliveira R, Amadei S, Pacheco-Soares C and Rocha R 2010. Laser 904 nm action on bone repair in rats with osteoporosis. *Osteoporos. Int.* 21(12): 2109-2114.
- Sella VRG, Do Bomfim FRC, Machado PCD, Da Silva Morsoleto MJM, Chohfi M and Plapler H 2015. Effect of low-level laser therapy on bone repair: a randomized controlled experimental study. *Lasers Med. Sci.* 30(3): 1061-1068.
- Sena K, Leven RM, Mazhar K, Sumner DR and Viridi AS 2005. Early gene response to low-intensity pulsed ultrasound in rat osteoblastic cells. *Ultrasound Med. Biol.* 31(5): 703-708.
- Sun Y, Oberley LW and Li Y 1988. A simple method for clinical assay of superoxide dismutase. *Clin. Chem.* 34(3): 497-500.
- Suzuki YJ and Packer L 1993. Inhibition of NF- $\kappa$ B activation by vitamin E derivatives. *Biochem. Biophys. Res. Commun.* 193(1): 277-283.
- Tawonsawatruk T, Hamilton DF and Simpson AHR 2014. Validation of the use of radiographic fracture-healing scores in a small animal model. *J. Orthop. Res.* 32(9): 1117-1119.
- Tietze F 1969. Enzymic method for quantitative determination of nanogram amounts of total and oxidized glutathione. *Anal. Biochem.* 27(3): 502-522.
- Tim CR, Pinto KNZ, Rossi BRO, Fernandes K, Matsumoto MA, Parizotto NA and Rennó ACM 2014. Low-level laser therapy enhances the expression of osteogenic factors during bone repair in rats. *Lasers Med. Sci.* 29(1): 147-156.
- Yaakobi T, Maltz L and Oron U 1996. Promotion of bone repair in the cortical bone of the tibia in rats by low energy laser (He-Ne) irradiation. *Calcif. Tissue Int.* 59(4): 297-300.
- Yoshioka T, Kawada K, Shimada T and Mori M 1979. Lipid peroxidation in maternal and cord blood and protective mechanism against activated-oxygen toxicity in the blood. *Am. J. Obstet. Gynecol.* 135(3): 372-376.
- Zhang YB, Zhong ZM, Hou G, Jiang H and Chen JT 2011. Involvement of oxidative stress in age-related bone loss. *J. Surg. Res.* 169(1): 37-42.