

9-1-1987

Harrington instrumentation in unstable fractures of thoracolumbar spines

Pibul Itiravivong

Follow this and additional works at: <https://digital.car.chula.ac.th/clmjournal>



Part of the [Medicine and Health Sciences Commons](#)

Recommended Citation

Itiravivong, Pibul (1987) "Harrington instrumentation in unstable fractures of thoracolumbar spines," *Chulalongkorn Medical Journal*: Vol. 31: Iss. 9, Article 5.

DOI: 10.58837/CHULA.CMJ.31.9.5

Available at: <https://digital.car.chula.ac.th/clmjournal/vol31/iss9/5>

This Article is brought to you for free and open access by the Chulalongkorn Journal Online (CUJO) at Chula Digital Collections. It has been accepted for inclusion in Chulalongkorn Medical Journal by an authorized editor of Chula Digital Collections. For more information, please contact ChulaDC@car.chula.ac.th.

Harrington instrumentation in unstable fractures of thoracolumbar spines

Pibul Itiravivong*

Itiravivong P. Harrington instrumentation in unstable fractures of thoracolumbar spines. Chula Med J 1987 Sep; 31 (9) : 691-699

Fifty-seven cases of unstable thoracolumbar spinal fracture treated by Harrington double distraction rod technique, were reviewed to assess the efficacy of this treatment. There were forty-three males and fourteen females of ages ranging from fifteen to sixty years average 31.9 years. Twenty-eight patients had no neurological involvement, while ten incomplete and nineteen complete neurological deficit. The average deformities before surgery were kyphosis 20.2° , scoliotic angle 4.2° and vertebral displacement 15.3%. After Harrington instrumentation, the average corrections gained were 65% for kyphosis, 77% for scoliosis and 75% for vertebral displacement. The follow up periods were at least 16 months. There were no deaths. Eight cases were found with hooks dislodged. The paraplegics remained unchanged, but a few of those in the incomplete neurological group gained some improvement.

Reprint requests : Itiravivong P. Department of Orthopaedic and Rehabilitation Medicine,
Faculty of Medicine, Chulalongkorn University, Bangkok 10500, Thailand.
Received for publications. June 16, 1987.

* Department of Orthopaedic and Rehabilitation Medicine, Faculty of Medicine, Chulalongkorn University.

พิบูลย์ อธิระวิวงศ์. การรักษากระดูกสันหลังหักไม่มั่นคงด้วยเครื่องมือ Harrington. จุฬาลงกรณ์เวชสาร 2530 กันยายน ; 31 (9) : 691 - 699

รายงานผลการรักษาผู้ป่วยที่มีกระดูกสันหลังหักชนิดไม่มั่นคง โดยผ่าตัดใส่แท่งโลหะ Harrington ยึดกระดูกสันหลัง การรายงานผลเน้นเรื่องประสิทธิภาพของแท่งโลหะ Harrington ว่า สามารถแก้ไขกระดูกสันหลังที่หักเคลื่อนผิดปกติให้คืนสู่สภาพเดิมได้มากน้อยเพียงใด รายงานผู้ป่วยทั้งหมด 57 ราย เป็นชาย 43 ราย หญิง 14 ราย อายุระหว่าง 15 ถึง 60 ปี เฉลี่ย 31.9 ปี ในจำนวนนั้นพบว่าผู้ป่วย 19 รายมีอัมพาตของขา 2 ข้าง 10 รายมีอัมพาตบางส่วน และ 28 รายไม่มีอาการของระบบประสาท ก่อนผ่าตัดค่าความผิดปกติของกระดูกสันหลังที่หักเคลื่อนมีค่าเฉลี่ยความโก่ง (kyphosis) 20.2 องศา ความคด (scoliosis) 4.2 องศา และเคลื่อน (displacement) 15.3% ภายหลังการผ่าตัดพบว่า แท่งโลหะ Harrington สามารถแก้ไขความโก่งได้ 64% แก้ความคดได้ 77% และแก้ความเคลื่อนได้ 75% ภาวะแทรกซ้อนจากการผ่าตัดพบมีตะขอก้าง (hook) หลุด 8 ราย ไม่มีผู้ป่วยรายใดเสียชีวิตจากการผ่าตัด ส่วนอัมพาตที่มีอยู่เดิมดีขึ้นเล็กน้อยในบางรายเท่านั้น

During the past ten years, many orthopaedic surgeons have paid much attention to the operative management of patients with vertebral fractures.⁽¹⁾ The recent trend towards rigid internal fixation of fractures to allow rapid mobilization of patients and to decrease the complications of prolonged immobilization of joints and muscles has been generally and almost totally accepted.^(2,3) The development of biomechanically sound instrumentation to provide internal fixation has rapidly changed the concept of patient management from the conservative approach to surgery.

Orthopaedic surgeons such as Holdsworth⁽⁴⁾ pioneered early orthopaedic interest in the management of the unstable thoracolumbar fracture. His classification of the stability of fractures remains a classic in orthopaedic literature. He deviated from the traditional approach of postural reduction by advocating open reduction and internal fixation with plates attached to the spinous processes of fractured vertebrae. The purpose was to restore the alignment of the spine and prevent further injury to the neural elements as the patient was being turned in bed. These patients, however, still required three months of bed rest.

Other methods of internal fixation, other than plate fixation as initiated by Holdsworth, including interspinous process wiring, serrated spinous process plates, short compression rods, springs, circumlaminar wiring and transpedicular screws have been advocated to improved fixation.⁽⁵⁻⁹⁾ However, the development and later modification of the Harrington double-rod system by Harrington provide the most reliable documented method, as have been reported in many orthopaedic literatures^(8,10-14) of reestablishing normal alignment of the spine and allowing it to heal in the most anatomically correct position.

This is a review of fifty-seven Thai patients with unstable thoracolumbar fractures. All these patients were operated upon by open reduction of fractures and internally fixed with Harrington double-rod system. The objective of this retrospective study is to record the efficacy of this technique of instrumentation in terms of corrective reduction of fractures.

Materials and Method

There were fifty-seven patients in this review, composing of forty-three males and fourteen females. Their ages ranged from fifteen to sixty years with an average of 31.9 years. Nineteen patients

had been injured in a fall, eleven had sustained a direct blow, seventeen had been in an automobile accident and ten in a motor-cycle accident. Associated injuries occurred in fifteen patients, eleven of whom had multiple associated injuries, while four had only one additional injury associating with the spinal fracture. Fractures of the ribs and of the long bones of the lower extremities were the most common associating fractures. Seven patients had a pneumothorax and three, an abdominal injury requiring laparotomy. Five patients had cerebral concussion. Concerning the spinal fractures, the most common site was at twelfth-first thoracic lumbar vertebral level, with only five cases occurring at the eleventh-twelfth thoracic level and another five cases at the first-second lumbar level. All these injuries were interpreted as unstable fractures according to the criteria set by Holdsworth.⁽⁴⁾ As soon as their general medical condition permitted, these patients had undergone open reduction and had been internally fixed with Harrington double distraction rods aimed at two levels above and two levels below the fractured vertebra. There were three cases with fractures instrumented at three levels above and three levels below. The operations were performed mainly by the author with one-fourth of all cases by two other surgeons, employing the same technique. The follow-up periods were from one to two years. The malalignments of the injured spinal column, created by fractured vertebrae, were measured in terms of degrees of kyphosis, degrees of scoliotic deviation and percentage of vertebral displacement, before and after Harrington instrumentation and also at the end of the follow up period.

Operative Technique^(8,10,12)

Two distraction rods, one on each side, were used for spinal instrumentation in all cases, but posterior fusion was performed in only half of the series, in which the bone graft was taken from the iliac crest. The incision over the spine was made so that the vertebrae bordering two interspaces above and two below the fractured interspace could be exposed. The area of the fracture was dissected with great care.

Two superior distraction hooks were placed under the inferior articular processes of the superior vertebra two interspaces above the fracture level. Two inferior hooks were placed on the inferior lamina at the second interspace below the fracture. For example, when there was a fracture at the

first lumbar vertebra with anterior displacement of the twelfth thoracic vertebra, the superior hooks were placed on the tenth thoracic and inferior hooks, on the third lumbar vertebrae. Two intact vertebrae above and two below the fracture had to be spanned to provide a lever arm long enough to reduce the fracture and to maintain the reduction.

After the hooks were in place, an outrigger, used only initially in the series, was engaged with the hooks on one side of the vertebral column and tightened. The resulting distraction restored the fractured segment to a better alignment and provided partial reduction. The first distraction rod was then inserted into the hooks on the opposite side, and just enough distraction was applied to attain reduction. Posterior fusion was performed on the side where the outrigger was in place. Usually fusion was limited to the area, only across the fractured site. Once the fusion was complete on this side, the outrigger was removed and the second distraction rod was inserted in its place. Distraction was applied until the hooks were firmly implanted. With the second in place, the first rod was removed. Fusion was performed on this side

and the rod was reinserted. A C-washer was usually applied on the ratchet just below the superior hook on each rod to prevent the hook from moving down the ratchet as the patient was mobilized.

However, in the latter cases of the series, the outrigger was not used, experience showed that the distraction could be directly applied at the distraction rods, once they are in place. In this way, there was no need for the removal and reinsertion of the first rod, and posterolateral fusion could be carried out without difficulty while the procedure was shortened. Postoperatively, the patient was instructed to wear a cast or brace in order to facilitate sitting or walking, if he had enough muscle strength.

Results

A method for measuring the kyphotic and scoliotic deformities as well as the amount of displacement was developed to enable quantification of the deformities of the spine. (Fig. 1,2,3) (Fig. 4,5,6,7)




FIGURE 1 ANGLE OF KYPHOSIS

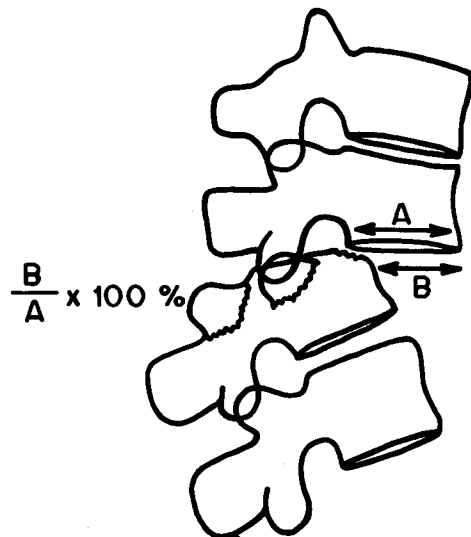


FIGURE 2 VERTEBRAL DISPLACEMENT

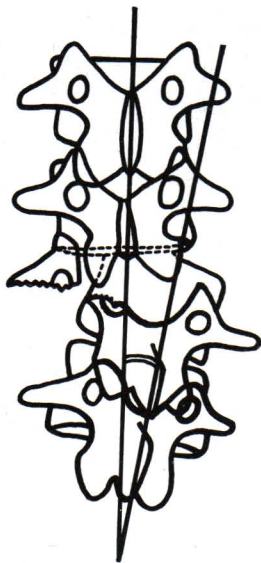


FIGURE 3 SCOLIOTIC DEVIATION.

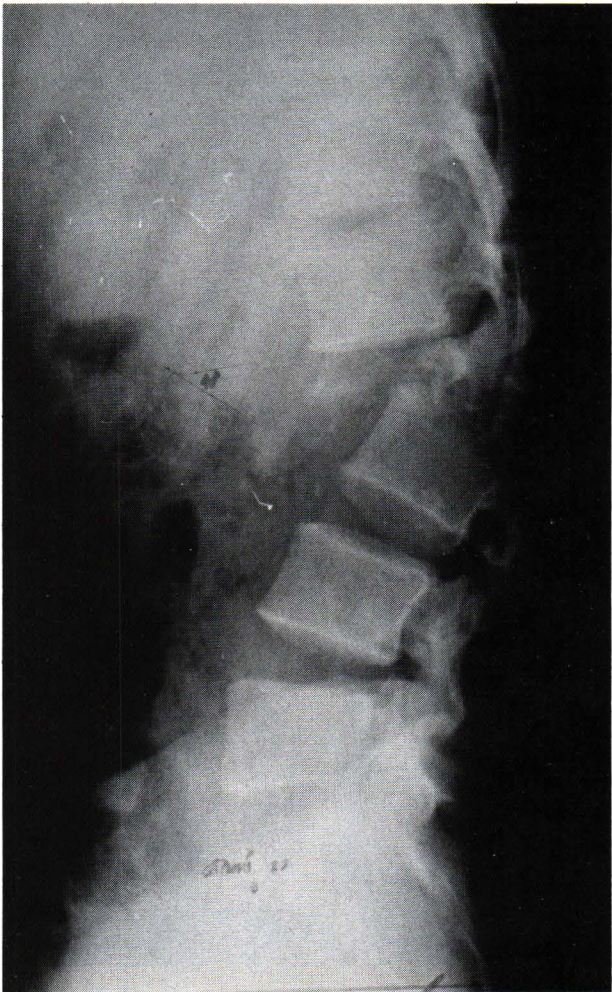


FIGURE 5 LATERAL VIEW SHOWING MARKED DISPLACEMENT OF UNSTABLE FRACTURE AT T12-L1

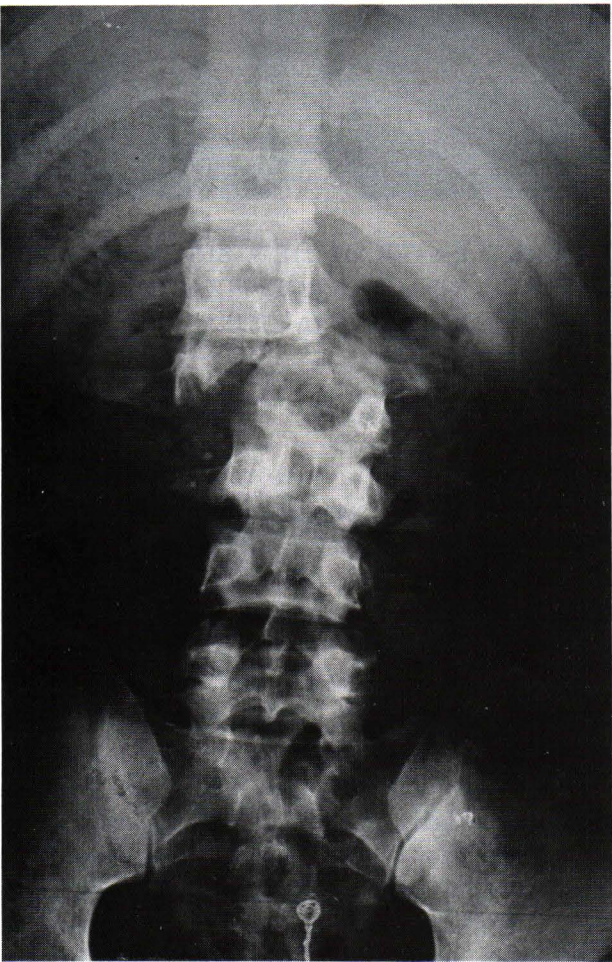


FIGURE 4 A-P X-RAYS SHOWING UNSTABLE FRACTURE AT T12-L1

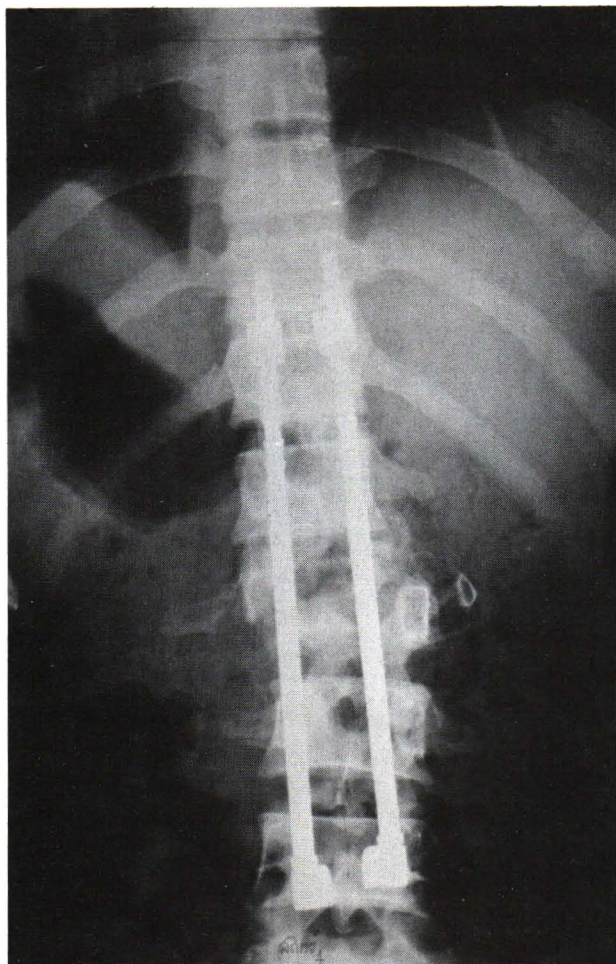


FIGURE 6 A-P VIEW SHOWING UNSTABLE FRACTURE T12-L1 FIXED WITH HARRINGTON RODS.

This measurement provided a baseline for the evaluation of reduction. Pre-operatively, the average measurement of kyphotic angle was 20.2 degrees, ranging from 10 degrees to 40 degrees, while immediately after surgery, the average measurement after correction was 7 degrees. This meant that Harrington instrumentation achieved 65 per cent of correction for kyphotic deformity. Concerning vertebral displacement, pre-operatively the average measurement was 15.3 per cent, ranging from zero to eighty per cent, and post-operatively, the average measurement was 3.8 per cent. This was interpreted as 75 per cent correction for vertebral displacement, provided by the double rod system. Considering the scoliotic deformity caused by the deviation of the fractured vertebral column, pre-operatively the average measurement was 4.2

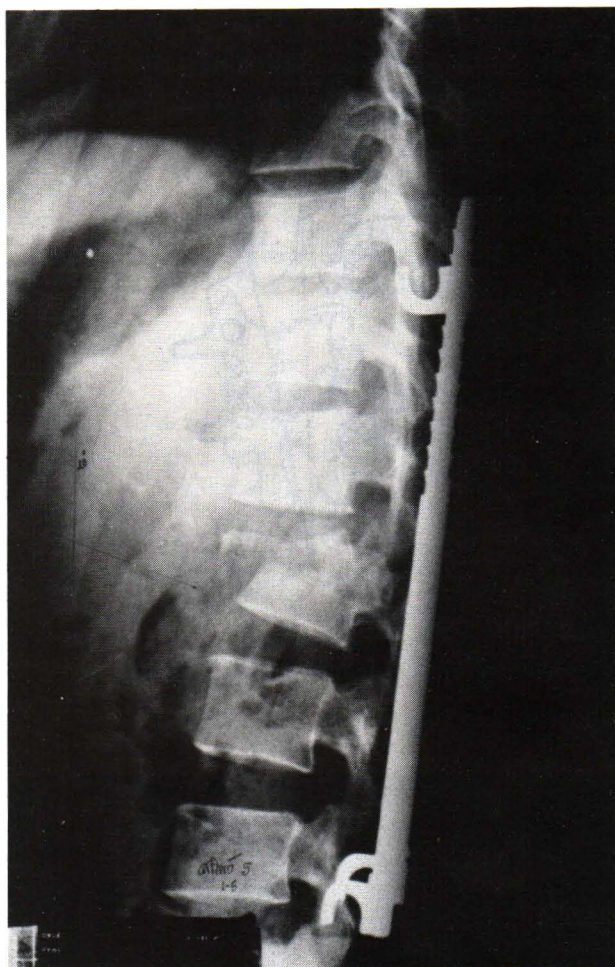


FIGURE 7 LATERAL VIEW SHOWING HARRINGTON ROD FIXATION IN UNSTABLE FRACTURE T12-L1.

degrees, ranging from zero to 18 degrees while postoperatively the average measurement was 1.0 degree. This showed that 77 per cent of correction for scoliotic deviation was obtained by this procedure. Summation of the results is displayed in Table I.

In this series, the author has no intention of giving detailed results of the neural involvements as this will be presented in the other report. However, it could be briefly stated that of the nineteen patients who had complete neurological involvement after injury, none gained any significant improvement from this operative technique. Two patients, out of ten, who sustained incomplete neurological deficit after injury showed an improvement of one and two grades, according to Frankel's classification,⁽¹⁵⁾ after Harrington instrumentation.

Table I Reduction of deformities.

Deformities	Pre operative	Post operative	Amount of correction
Kyphotic angle	20.2°	7.0°	65%
Vertebral displacement	15.3%	3.8%	75%
Scoliotic deviation	4.2°	1.0°	77%

Complications

There were fifteen patients with complications relating to the operation : incorrect placement of instruments, hook displacement and infection. The error in placing the instrument was often that the rod spanned an insufficient number of vertebrae. In four patients, the span above the fractured interspace was one segment short and in two patients, the span below, was one segment short. Hook displacements were found in eight patients, five at the upper hooks and three at the lower. Deep infection developed immediately after operation, was found in one patient and was cleared in a few weeks by cleansing, debridement and appropriate antibiotics.

Discussion

Open reduction with internal fixation of unstable fractures of the thoracolumbar spine has the following advantages.^(3-6, 9-14, 16) (1) reduction and maintenance of alignment; (2) restoration of stability to promote healing and prevent further increased neurologic loss; (3) prevention of late deformity ; and (4) early mobilization.

Harrington double-rod instrumentation is an effective means of achieving these goals. In our series, 65 per cent correction of kyphotic deformity, 75 per cent correction of vertebral displacement and 77 per cent correction of scoliotic deviation were obtained. These figures are comparable to ninety five patient-series of Dickson et al⁽¹⁰⁾ who reported 65 per cent correction of kyphotic deformity and 78 per cent correction of vertebral displacement. However, the lesser degrees of correction of angular or kyphotic deformity were reported by Gertzbein et al,⁽¹⁷⁾ Flesch et al,⁽¹¹⁾ and Yosipovitch et al⁽¹²⁾ who documented 58 per cent, 47 per cent and 46 per cent of correction respectively.

As already mentioned, early mobilization is one of the reasons for doing open reduction and internal fixation of the unstable thoracolumbar spine fractures. Once the patient is mobilized, stress and strain will concentrate on the Harrington rods with flexion, lateral and rotational loadings.^(3,7,18,19) That is why there are complications relating to this kind of instrumentation. In our series, aside from the technical errors, there were 8 cases (14 per cent) of hook displacement, occurring mainly at the upper hooks. This incidence also happened in the series of Dickson et al⁽¹⁰⁾ who reported 6 per cent hook dislodgement and also 6 per cent broken rods. A report of critical analysis of deficiencies of the Harrington instrumentation technique by Gertzbein et al⁽¹⁷⁾ also revealed 28 per cent slippage of the upper hooks down the rods.

On evaluation at the end of follow up periods in most reports, many authors^(10-14, 16-19) recognized the loss of initial correction of the angular deformity. Dickson et al⁽¹⁰⁾, Fresh et al⁽¹¹⁾ and Gertzbein et al⁽¹⁷⁾ reported an average loss of about five percent of final correction in their series. The same figure was also noted in many cases of this series.

Considering the above figures of the efficacy of reduction and complications, it seems that the Harrington instrumentation system does not provide the rigid internal fixation it is assumed and expected to have. The Harrington distraction rods were initially designed to counteract forces of vertical loading.^(8,10,17) When used for fractures, they act as an internal splint but are required to counteract forces of bending and tension, forces which they are not as capable of resisting. Perfect reduction could not be obtained in most cases of the series and instrumentation failure rates were relatively high.

What are the wayout now, for the Harrington distraction rod system to overcome instru-

mentation failures, to gain better correction and to maintain reduction. If one is to carry on with this Harrington instrumentation, one must really be strict with the technique.^(8,10,11,12,17) Attention to detail, particularly in securing the hook on the rod at the upper end, is very important. The C-clamp or washer or wire must abut adjacent to the hook. If there is a space, the hooks can migrate down the rod resulting in loss of fixation and reduction. A second technical problem is lateral placement of the upper hooks. When the facet joints are being prepared, destruction of the capsular ligaments may result in lateral migration of the hooks with loss of contact and failure of the fixation device. Whenever possible, the upper hooks should be seated under the lamina, not between the facets. If too much bone is removed the lamina supporting the lower hooks may fracture. By taking most of the bone from the lamina above, this complication can be averted.

Beside this strict operative technique of Harrington instrumentation, the introduction of sublaminar wiring to the Harrington distraction rods^(18,19,20) in order to increase spinal stability is beneficial and gaining popularity. The clinical and experimental studies of Gaines et al⁽¹⁹⁾ and Sullivan⁽¹⁸⁾ showed that the stability of the Harrington rods can be enhanced by sublaminar wiring and that spines stressed to failure in flexion and in rotation fall outside the instrumented area or at the hook-bone interface. The increased stability is attributed to fixation at multiple sites.

Acknowledgements

The author would like to thank Dr. Pairach Prasongghin and Dr. Yongyudth Siripakarn who contributed their patients for study.

References

1. Dwyer AP. Editorial comment. Clin Orthop 1984 Oct; 189 : 2-5
2. Donovan WH, Dwyer AP. An update on the early management of traumatic paraplegia (non-operative and operative management). Clin Orthop 1984 Oct; 189 : 12-21
3. Jacobs RR, Casey MP. Surgical management of thoracolumbar spinal injuries. Clin Orthop 1984 Oct; 189 : 22-35
4. Holdsworth F. Review article. Fractures, dislocations and fracture dislocations of the spine. J Bone Joint Surg (Am) 1970 Dec; 52 A (8) : 1534-1551
5. Kaufer H, Hayes JT. Lumbar fracture-Dislocation: a study of twenty one cases. J Bone Joint Surg (Am) 1966 Jun; 48A (6) : 712-730
6. Lewis J, McKibbin B. The treatment of unstable fracture dislocations of the thoracolumbar spine associated by paraplegia. J Bone Joint Surg (Br) 1974 Nov; 56B (4) : 603-612
7. Weiss M, Bentkowsky Z. Biomechanical study in dynamic spondylodesis of the spine. Clin Orthop 1974 Jan; 103 : 199-203
8. Harrington PR. Technical details in relation to the Successful use of instrumentation in scoliosis. Orthop Clin North Am 1972 Jan ; 3 (1) : 49-67
9. Spence WT. Internal plastic splint and fusion for stabilization of the spine. Clin Orthop 1973 Jan; 92 : 325-329
10. Dickson JH, Harrington PR, Erwin WD. Harrington instrumentation in the fractured unstable thoracic and lumbar spine. J Bone Joint Surg (Am) 1978 Sept ; 60A (6) : 799-805
11. Flesch JR, Leider LL, Erickson DL, Chou SN, Bradford DS. Harrington instrumentation and spine fusion for unstable fractures and fracturedislocations of the thoracic and lumbar spine. J Bone Joint Surg (Am) 1977 Mar; 59A (2) : 143-153
12. Yosipovitch Z, Robin GC, Mankin M. Open reduction of unstable Thoracolumbar spinal injuries and fixation with Harrington rods. J Bone Joint Surg 1977 Dec; 59A (8) : 1003-1015
13. Roberts JB, Curtiss PH, Jr. Stability of the thoracic and lumbar spine in traumatic paraplegia following fracture or fracture-dislocation. J Bone Joint Surg (Am) 1970. Sep; 52A (6) : 1115-1130
14. Burke DC, Murray DD. The management of thoracic and thoraco-lumbar injuries of the spine with neurological involvement.

- J Bone Joint Surg (Br) 1976 Feb; 58B (1): 72-78
15. Frankel HL, Hancock DD, Hyslop G, Melzak J, Michaelis LS, Ungar GH, Vernon JDS, Walsh JJ. The value of postural reduction in the initial management of closed injuries of the spine with paraplegia and tetraplegia. Part I. Paraplegia 1979 Nov ; 7 : 179-192
 16. Gaines WR, Humphreys GW. A plea for judgment in management of thoracolumbar fractures and fracturedislocations. Clin Orthop 1984 Oct; 189 : 36-42
 17. Gertzbein DS, Macmichael D, Tile M. Harrington instrumentation as a method of fixation in fracture of the spine : a critical analysis of deficiencies. J Bone Joint Surg (Br) 1982, May ; 64B (2) : 526-529
 18. Sullivan AJ. Sublaminar wiring of Harrington distraction rods for unstable thoracolumbar spine fractures. Clin Orthop 1984 Oct; 189 : 178-194
 19. Gaines WR, Breedlove FR, Munson G. Stabilization of thoracic and thoracolumbar fracture. Clin Orthop 1984 Oct ; 189 195-203
 20. Wenger RD, Carollo JJ. The mechanics of thoracolumbar fractures stabilized by segmental fixation. Clin orthop 1984 Oct; 189 : 89-96