

9-1-1987

Isolated anterior dislocation of the radialhead; Case report and review of literature

Pibul Itiravivong

Follow this and additional works at: <https://digital.car.chula.ac.th/clmjournal>



Part of the [Medicine and Health Sciences Commons](#)

Recommended Citation

Itiravivong, Pibul (1987) "Isolated anterior dislocation of the radialhead; Case report and review of literature," *Chulalongkorn Medical Journal*: Vol. 31: Iss. 9, Article 3.

DOI: 10.58837/CHULA.CMJ.31.9.3

Available at: <https://digital.car.chula.ac.th/clmjournal/vol31/iss9/3>

This Special Article is brought to you for free and open access by the Chulalongkorn Journal Online (CUJO) at Chula Digital Collections. It has been accepted for inclusion in Chulalongkorn Medical Journal by an authorized editor of Chula Digital Collections. For more information, please contact ChulaDC@car.chula.ac.th.

Isolated anterior dislocation of the radial head; Case report and review of literature

Pibul Itiravivong*

Itiravivong P. Isolated anterior dislocation of the radial head; Case report and review of literature. Chula Med J 1987 Sep; 31(9) : 681-684

A rare case of isolated anterior dislocation of the radial head was reported in a thirteen year old Thai boy. The mechanism of injury and clinical presentation in this patient were discussed together with a review of previous reports in the literature. Treatment was by immediate closed reduction and maintained by a plaster of Paris cast. It yielded satisfactory result.

พิบูลย์ อธิระวิวงศ์. หัวกระดูกเรเดียสหลุดทางด้านหน้า. จุฬาลงกรณ์เวชสาร 2530 กันยายน; 31 (9) : 681 - 684

รายงานของเด็กชายไทยอายุ 13 ปี ภายหลังหกล้มมือขวายันพื้นและปลายแขนบิดออกแล้ว ตรวจพบ มีหัวกระดูกเรเดียสหลุดออกจากเบ้าโคต ๆ ทางด้านหน้าโดยไม่มีกระดูกหักอื่นร่วมด้วย ถือเป็นอุบัติเหตุที่เกิดขึ้นได้น้อยมาก รายงานนี้ได้รวบรวมข้อมูลต่าง ๆ เกี่ยวกับโรคนี้ที่เคยลงพิมพ์ในวารสารต่าง ๆ ด้วย แล้วเปรียบเทียบกับอุบัติเหตุที่เกิดขึ้นในรายนี้ทั้งในแง่คลินิก กลไกทำให้เกิด และการรักษา ผลการรักษาในผู้ป่วยรายนี้ได้ผลดี โดยวิธีอนุรักษนิยม

Reprint requests : Itiravivong P. Department of Orthopaedic and Rehabilitation Medicine,
Faculty of Medicine, Chulalongkorn University, Bangkok 10500, Thailand.
Received for publications. July 20, 1987.

* Department of Orthopaedic and Rehabilitation Medicine, Faculty of Medicine, Chulalongkorn University.

Isolated dislocation of the radial head is a rare condition.^(1,2,3) Congenital and traumatic dislocations have been reported in a small number of patients and the incidence was higher in children than in adults.^(1,2,3) Little is known of mechanisms which permit such an unusual displacement of the radius. We wish to report a case of isolated anterior dislocation of the radial head resulting from an accidental fall.

Classification and Radiography

Congenital dislocation of the radial head may be anterior, posterior or lateral.^(1,4) The isolated anomaly is most commonly reported as anterior (47% of 72 cases).⁽¹⁾ Posterior and lateral dislocations were found in about 43% and 10% respectively.⁽¹⁾ Both anterior and posterior forms may be associated with other anomalies such as Klinefelter's syndrome, Madelung's deformity, Ehler-Danlos syndrome, Arthrogryposis, Konig disease, Nail-Patella syndrome.^(1,4) Traumatic dislocation is considered as rare. Three types have been noted to occur : anterior, lateral and posterior. Anterior dislocation is the most and posterior the least common.^(2,3,5)

Differentiation between congenital and traumatic dislocation is assisted by roentgenographic criteria.^(1,3) In anterior congenital dislocation, the posterior border of the ulna is concave rather than slightly convex as normally seen. The radial head is dome-shaped with no clear depression. This in contrast with traumatic dislocation which exhibits a normal central depression. Posterior congenital dislocation is characterized by an elongated and thinned contour of the radial head. The normal convexity of the posterior border of the ulna is accentuated. The lateral dislocation is recognized by a distinctive separation between the proximal end of the radius and the capitellum.

Mechanism of Injury

It is usually impossible from the history, to be certain of the direction of forces directed at the forearm and elbow at the time of injury. Previous authors have discussed mechanisms of injury.^(3,6) Some believe that the mechanism should be a hyperextension force applied to the fully supinated forearm producing an anteriorly dislocated radial head.⁽⁶⁾ Other authors suggest that the force is directed at the partly extended elbow with the forearm pronated thus causing rupture of the annular ligament.⁽³⁾ The dislocated proximal

radius may then assume a position lateral, anterior, or even posterolateral to the elbow joint proper. Its final location is then dictated by the post injury position of the extremity.^(3,6)

Clinical Features and Management

The patient, usually a child, presents with a painful elbow which he or she protects against movement. Little or no deformity is apparent. Passive flexion and extension of the elbow is possible or only slightly restricted. Pronation and supination of the forearm usually results in strong resistance. Roentgenographic studies confirm the diagnosis. It should be recalled that on a lateral radiograph of the normal elbow, a line through the long axis of the radius must bisect the capitellum.

Management is usually by closed manipulation.^(1,3) In the anterior type, the reduction is accomplished by gentle supination of the forearm combined with extension of the elbow and, if necessary, direct thumb pressure over the radial head. In the posterior dislocation, the radial head is reduced by maintaining manual traction in extension and rotating the forearm into full pronation.⁽³⁾ The elbow is immobilized in a posterior plaster splint for three weeks when rehabilitation begins. Surgery has to be employed in an old dislocation.^(1,3) This requires incision of the annular ligament and capsule in order to reduce the radial head.⁽³⁾ When open reduction is impossible and or recurrence occurs,⁽⁸⁾ radial head resection is performed.^(1,3,8)

Pathological Anatomy

From cadaver studies by Wiley et al,⁽³⁾ it was found that

[1] Lateral dislocation could be produced by a lateral capsular incision which included the annular ligament followed by forced pronation of the forearm and varus strain at the elbow.

[2] With the radial head dislocated laterally, supination of the forearm either reduced the radial head to its normal position or directed the head to a seemingly irreducible position posteriorly.

[3] Anterior dislocation could be produced only with difficulty. It could be produced when the forearm was in extreme supination, after completely severing the anterior capsule and annular ligament and then applying force in an anterior direction to the posterior aspect of the radial head.

Case Report

A thirteen year old Thai boy had an accidental fall and sustained injury to his right elbow. He was seen in the emergency room two hours after the accident. From the history the patient revealed that he was normally very active and in good health, but after the fall on the out-strected right hand, he experienced sudden pain in his right elbow. On physical examination, his right elbow was in a semiflexion position. No obvious deformity and minimal swelling were noted at the

elbow joint. There were marked limitation of pronation and supination of his right forearm due to pain. Flexion of the elbow was almost full, but extension was restricted. The three point-triangular alignment of the two humeral condyles and olecranon tip at the right elbow was normal. Neurovascular examination of this upper limb was intact. Radiology of the right elbow revealed isolated anterior dislocation of the radial head without associated fracture. (Fig. 1)

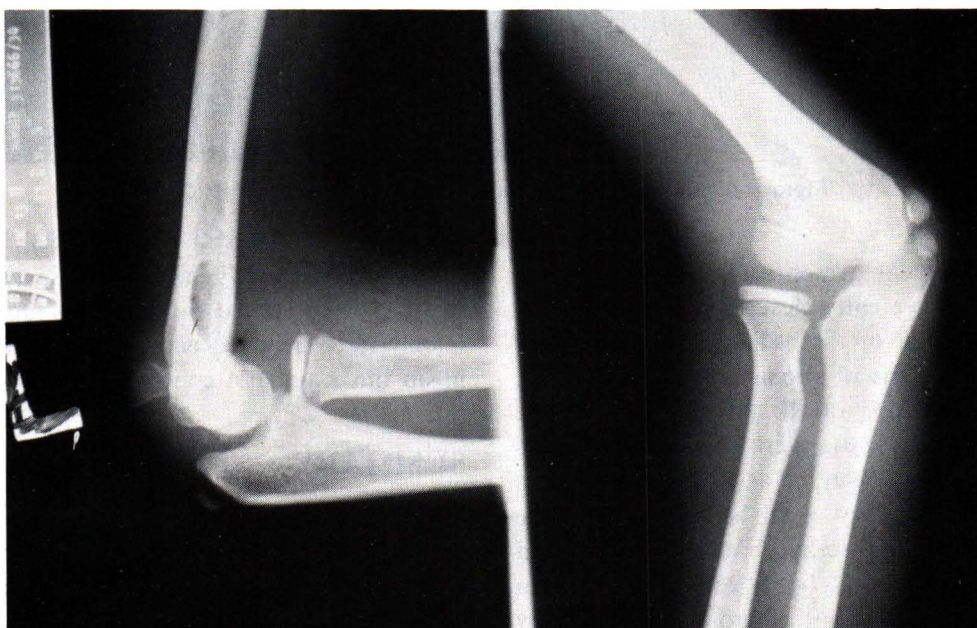


Figure 1 Showing anterior dislocation of radial head.

Management in this case was by closed manipulation under local anesthesia. By exerting longitudinal traction force along the supinated right forearm and with thumb pressure over the radial head, the dislocation was easily reduced with a faint audible click. The reduction was then maintained by a posterior plaster slap on a fully

flexed elbow. Radiology after reduction showed normal seating of the radial head. (Fig. 2) Three weeks after the injury, the plaster slab was removed rehabilitation began. Physical examination, a week later, showed that the patient regained full function of his right elbow and had no pain.

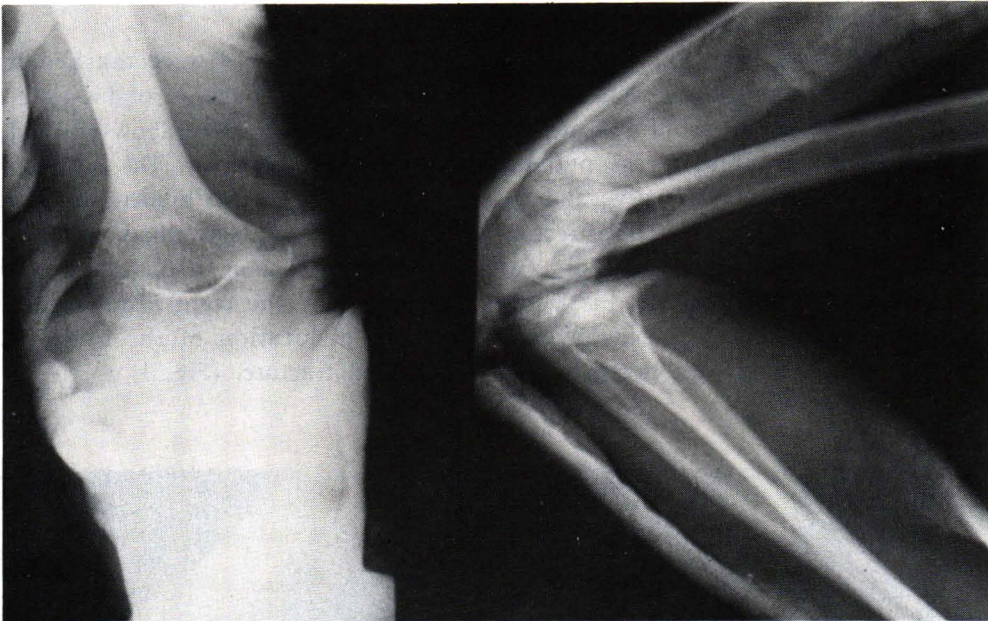


Figure 2 Showing good reduction of radial head.

Discussion

The clinical presentation of this patient was almost as typically described for the usual anterior dislocation of the radial head. There were significant limitations of pronation and supination. Flexion and extension of the affected elbow were slightly restricted. These were the usual features of case reports by Wiley et al.⁽³⁾ The mechanism of injury, if the history could be trusted, was one of trauma with outstretched hand and supinated forearm. This contrasts with conclusion drawn from the pathological and anatomical studies by Wiley.⁽³⁾ The radiological appearance confirms the diagnosis of anterior dislocation of the radial head. It was not a congenital dislocation since

radiographs displayed a normal radial head. Closed reduction is usually possible in a recent injury and has been proved in this case. Open reduction is only rarely required and may be needed especially in an old traumatic condition.⁽⁹⁾

SUMMARY

We report a thirteen year old Thai patient with isolated anterior dislocation of the radial head together with a review of the literature dealing with congenital and traumatic radial head disorders. The clinical presentation of our case did not differ from those previously reported. Treatment was by closed reduction and yielded satisfactory results.

References

1. Almgvist EE, Gordon LN, Blue AI. Congenital dislocation of the head of the radius. *J Bone Joint Surg (Am)* 1969 Sep; 51A (6) : 1118-1127
2. Vesely DG. Isolated traumatic dislocations of the radial head in children. *Clin Orthop* 1967 Jan-Feb; 50 : 31-36
3. Wiley JJ, Pegination J, Horwich JP. Traumatic dislocation of the radius at the elbow. *J Bone Joint Surg (Br)* 1974 Aug; 56B(3) : 501-507
4. Gunn DR, Pillay VK. Congenital posterior dislocation of the head of the radius. *Clin Orthops* 1964 Jul-Aug; 34 : 108 head of the radius. *Clin Orthop* 1984 Jun; 186 : 192
5. Gurgess RC, Sprague HH. Post-Traumatic posterior radial head subluxation, a report of two cases. *Clin Orthop* 1984 Jun; 186 : 192
6. Neviaser RJ, Lefevre GW. Irreducible isolated dislocation of the radial head : a case report. *Clin Orthop* 1971 Oct; 80 : 72-74
7. Hamilton W, Parkes JC. Isolated dislocation of the radial head without fracture of the ulna. *Clin Orthop* 1973 Nov-Dec; 97 : 94-96
8. Salama R, Wientrous S, Weissman SL. Recurrent dislocation of the head of the radius. *Clin Orthop* 1977 Jun; 125 : 156
9. Morrey BF, Chao EY, Hut FC. Biomechanical study of the elbow following excision of the radial head. *J Bone Joint Surg (Am)* 1979 Jan; 61A(1) : 62