

12-1-2020

Comparison between conventional and applied vertebral heart score (VHS) methods to evaluate heart size in healthy Thai domestic shorthair cats

Jetsada Rungpupradit

Somchin Sutthigran

Follow this and additional works at: <https://digital.car.chula.ac.th/tjvm>



Part of the [Veterinary Medicine Commons](#)

Recommended Citation

Rungpupradit, Jetsada and Sutthigran, Somchin (2020) "Comparison between conventional and applied vertebral heart score (VHS) methods to evaluate heart size in healthy Thai domestic shorthair cats," *The Thai Journal of Veterinary Medicine*: Vol. 50: Iss. 4, Article 2.

Available at: <https://digital.car.chula.ac.th/tjvm/vol50/iss4/2>

This Article is brought to you for free and open access by the Chulalongkorn Journal Online (CUJO) at Chula Digital Collections. It has been accepted for inclusion in The Thai Journal of Veterinary Medicine by an authorized editor of Chula Digital Collections. For more information, please contact ChulaDC@car.chula.ac.th.

Comparison between conventional and applied vertebral heart score (VHS) methods to evaluate heart size in healthy Thai domestic shorthair cats

Jetsada Rungpupradit^{1*} Somchin Sutthigran¹

Abstract

Thoracic radiography is the most common first modality for heart size evaluation and confirming cardiogenic pulmonary edema in cats with suspected heart diseases. The Vertebral Heart Score (VHS) was established as an objective method for diagnosing cardiomegaly via thoracic radiography. However, the conventional VHS method is inappropriate for cats with abnormal thoracic vertebrae. Therefore, the applied VHS method, which uses the lateral view axis sum divided with the length of each thoracic vertebra (T4, T5 and T6) was created to minimize the limitation of VHS in these cases. This study compared the conventional and the applied VHS methods in healthy Thai domestic shorthair cats to evaluate the heart size of cats with abnormal thoracic vertebrae or improper thoracic vertebral alignment.

Right lateral (RL) and left lateral (LL) radiographs were taken of 97 clinically healthy adult Thai domestic shorthair cats, and the VHS was measured on both RL and LL views. Applied VHS was calculated by using the summation of cardiac long and short axis divided by the length of each thoracic vertebra (T4, T5 and T6). The mean±SD values of VHS were 7.2 ± 0.45 v. (LL) and 7.43 ± 0.44 v. (RL). The mean±SD of applied VHS of T4, T5 and T6 in LL view axis were 7.17 ± 0.48 v, 7.11 ± 0.47 v and 7.03 ± 0.47 v respectively, while the mean±SD of applied VHS of T4, T5 and T6 in RL view were 7.43 ± 0.47 v, 7.38 ± 0.46 v and 7.29 ± 0.47 v respectively. No statistical difference between the mean of conventional VHS compared to the mean of applied VHS for both LL and RL view were found from ANOVA testing.

Results indicated that differences between conventional VHS and applied VHS of both LL and RL view axes were not significant. Therefore, applied VHS methods might provide increased accuracy for evaluation of heart size in cats with abnormal thoracic vertebrae. However, suitability of the applied VHS methods in different cat breeds requires further investigation.

Keywords: applied, heart, radiograph, VHS, cats

¹Department of Small Domestic Animal and Radiology, Faculty of Veterinary Medicine, Mahanakorn University of Technology, Bangkok, Thailand

*Correspondence: rung7@hotmail.com (J. Rungpupradit)

Received May 14, 2020.

Accepted September 21, 2020.

Introduction

Feline heart diseases including congenital malformations, acquired heart diseases, and vascular disorders are life-threatening (Paige *et al.*, 2009; Scrope DP, 2015). Hypertrophic cardiomyopathy (HCM) is the most common primary cardiomyopathy in cats, with symptoms including systolic murmur, gallop rhythm, dyspnea and syncope (Etienne *et al.*, 2011; Smith and Dukes-McEwan, 2012). However, many cats with HCM are asymptomatic and the disease is difficult to diagnose in general practice (Paige *et al.*, 2009).

Thoracic radiography is commonly selected as the first method to evaluate heart size and confirm cardiogenic pulmonary edema in cats with heart disease (Guglielmini *et al.*, 2014). The Vertebral Heart Score (VHS) was established to create a more objective way of diagnosing cardiomegaly via thoracic radiography (Buchanan and Bucheler, 1995). The VHS is obtained by measuring the long and short axes of the heart and comparing their sum to the mid-thoracic vertebral bodies starting from the cranial edge of the 4th thoracic vertebra. The distance to the caudal point was estimated to the nearest 0.1 vertebra. Mean VHS of normal dogs and cats obtained from lateral radiographs are 9.7 ± 0.5 and 7.5 ± 0.3 vertebrae, respectively (Buchanan and Bucheler, 1995; Litster and Buchanan, 2000). Variations of VHS ranges in different dog and cat breeds were reported; however, no significant differences between sex and position in evaluated VHS were found (Alireza *et al.*, 2008; Greco *et al.*, 2008). Furthermore, radiographic cardiac size in various canine and feline cardiovascular diseases were also reported (Litster *et al.*, 2005; Sleeper *et al.*, 2013).

When using the VHS method to measure heart size, both the cardiac long axis and short axis lines should be repositioned parallel to the thoracic vertebrae, and the caudal point of the long and short axes should be estimated to the nearest 0.1 vertebra (Buchana and Bucheler, 1995; Buchanan JW, 2000). Therefore, dogs and cats that have nonlinear thoracic vertebral alignment may record an inaccurate estimation of cardiac size using conventional VHS. In addition, cats with abnormal thoracic vertebrae as a result of vertebral fracture, intervertebral disc disease (IVDD), vertebral neoplasia, spondylosis deformans and kyphosis due to juvenile secondary nutritional hyperparathyroidism may affect the accuracy of this method (Tomsa *et al.*, 1999). The conventional VHS is subjective when used to evaluate heart size, especially when comparing the caudal point of the cardiac axis with thoracic vertebrae, and results depend on individual observation. This study was based on a previous study of Buchanan and colleague (1995) that reported good correlation between heart size and the length between the T4 and T6 vertebrae. In this study, we developed the applied VHS by using the sum of the cardiac long and short axes divided by the length of each thoracic vertebra (T4, T5 and T6) using lateral radiography. Our applied VHS method was designed to enhance the accuracy of cardiac size estimation and minimize the limitation of the conventional VHS method in cats with abnormal thoracic vertebrae.

Thus, the aim of this study was to compare the conventional and applied VHS methods for heart size

measurement using the sum of the cardiac long and short axes measured by lateral radiography, correlated with the length of each thoracic vertebra (T4, T5 and T6) in 93 healthy Thai domestic shorthair cats.

Materials and Methods

Study populations: This study was approved by Animal care and Use Committee of Mahanakorn University of Technology (ACUC-MUT); the approval number 2020/004. In this retrospective study, thoracic radiographic images were retrieved from 50 male and 47 female cats that were enrolled for the cardiac disease screening program at the Small Animal Teaching Hospital, Faculty of Veterinary Medicine, Mahanakorn University of Technology during January - October 2016. All enrolled cats underwent physical examination (such as heart and lung sound, mucous membrane color, hydration status, body temperature), thoracic radiography, electrocardiogram (ECG) and echocardiogram. Thoracic radiographic images of the cats were taken from the thoracic inlet to the diaphragm. Inclusion criteria for images were cats 1-5 years of age, non-obese (body condition score 2-4/5), no abnormalities of physical examination, no abnormalities of electrocardiography and echocardiography. Cats presenting cardiac disease and/or abnormalities of physical examination, electrocardiography and echocardiography were excluded from this study.

Thoracic radiography: All cats were given thoracic radiography including left and right lateral views by manual restraint without sedation. Exposure factors were 45-50 kVp; 10-12 mAs depending on body thickness. All thoracic radiographic images were retrieved from the hospital radiological system in the Digital Imaging and Communications in Medicine (DICOM) format and reanalyzed using DICOM viewer software (Osirix®, Geneva, Switzerland).

Conventional VHS and applied VHS measurement: All radiographic data were measured and calculated by one observer with 7 years of experience in small animal practice. Conventional VHS was calculated from both RL and LL measurements based on a previous study (Lister and Buchanan, 2000). The sum of the cardiac long axis (distance from the ventral border of the carina to the cardiac apex) and short axis (perpendicular line to the long axis measurement at the point of maximum cardiac width) were measured on both RL and LL views in millimeters (mm) (Figure 1). The length of each thoracic vertebra T4, T5 and T6 was measured from the cranial edge of the proximal vertebra to the cranial edge of the next vertebra on both RL and LL views in mm (Figure 2). Applied VHS was calculated as the summation of cardiac long and short axes divided by the length of each thoracic vertebra (T4, T5 and T6).

Statistical analysis: Clinical data was expressed as mean and standard deviation (SD) with normal distribution determined by Shapiro-Wilk test. Analysis of variance (ANOVA) was used to evaluate significant difference among each method (conventional VHS,

applied VHS T4, applied VHS T5 and applied VHS T6). Correlation between conventional VHS and applied VHS were analyzed by Pearson's correlation

coefficient. For all tests, a *P* value < 0.05 was considered significant.

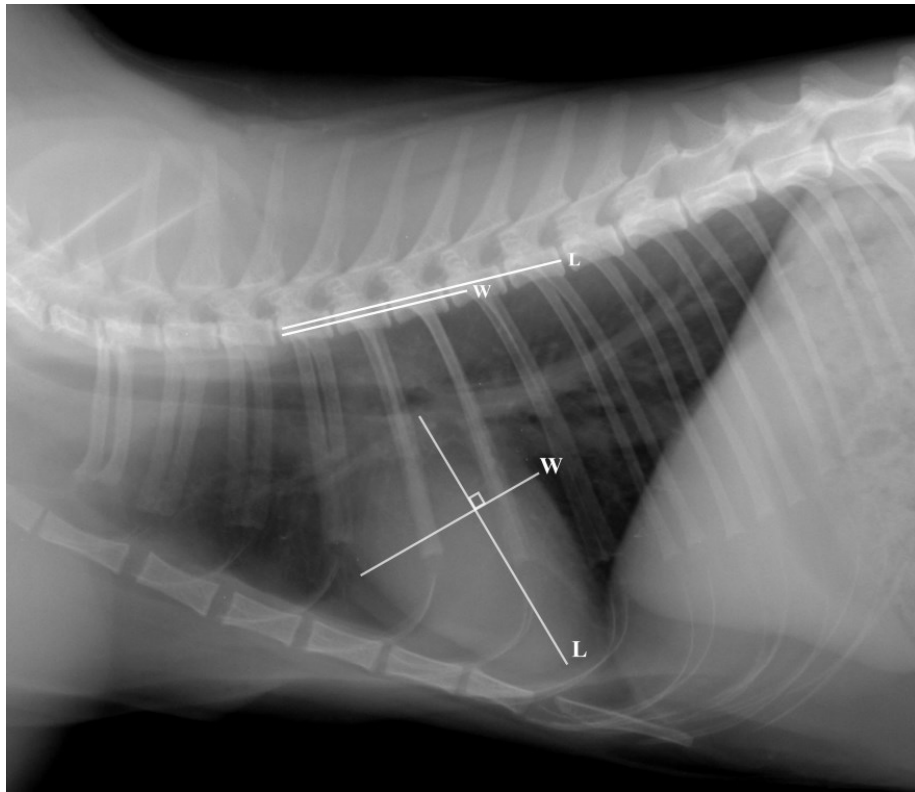


Figure 1 The vertebral heart score (VHS) was calculated by drawing a line from the carina to the ventral aspect of heart (long axis, L) and drawing a line perpendicular to the long axis at the widest point (short axis, W). These lines are compared with the vertebral bodies from the cranial aspect of T4. The number of vertebrae are added together for the VHS.

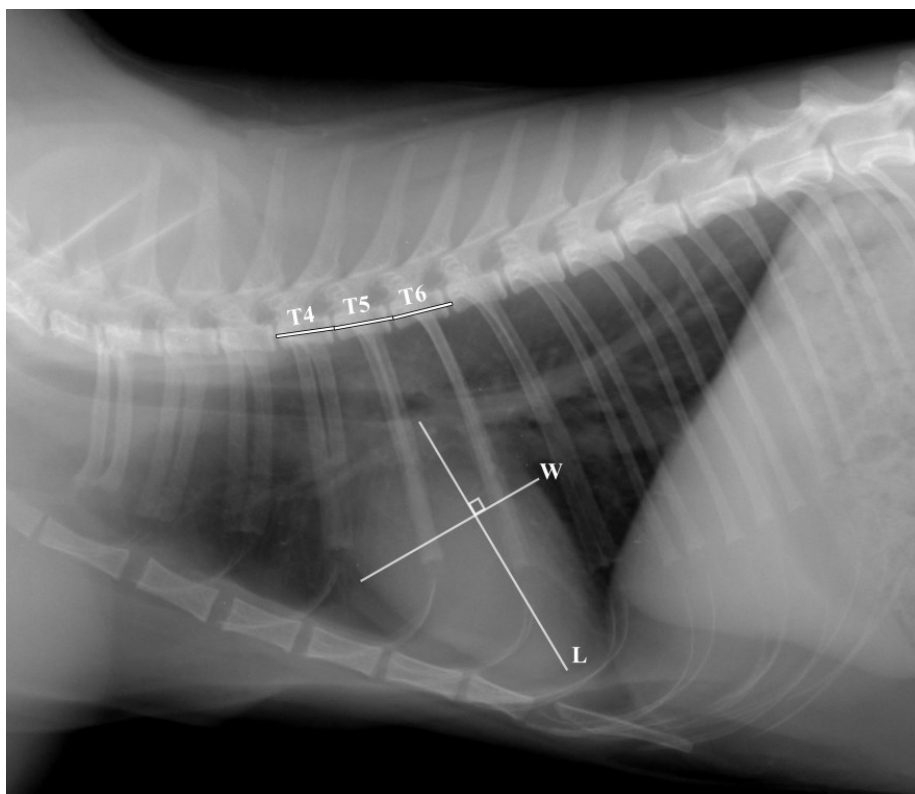


Figure 2 The applied vertebral heart score (applied VHS) are calculated by drawing a line from the carina to the ventral aspect of heart (long axis, L) and drawing a line perpendicular to the long axis at the widest point (short axis, W) the same as conventional VHS. The length of each single thoracic vertebral body (T4, T5 and T6) were measured. The applied VHS was summation of cardiac long and short axes divided with the length of each single thoracic vertebrae.

Results

Ninety-seven healthy Thai domestic shorthair cats as 50 males (25 intact, 5 castrated and 20 with unidentified gonadal status) and 47 females (32 intact, 3 spayed and 12 with unidentified gonadal status) were included in the study. Median age was 2 years (1-5.2 years) for males and 1.5 years (1-5 years) for females, with median bodyweight 3.95 kg (2.2-6 kg) in males and 3.30 kg (1.7-5.8 kg) in females. Median body condition score in both males and females was 3. Mean \pm SD results of conventional VHS and applied VHS of each T4, T5 and T6 vertebra on both left and right views are shown in Table 1. For the left lateral view, mean \pm SD of applied VHS of each thoracic vertebra (T4, T5 and T6) was slightly lower than for the conventional VHS method; however, difference between the groups was not significant (Table 1). For the right lateral view, mean \pm SD of applied VHS of T4 was equal to the conventional VHS method, while T5 and T6 were slightly lower than the conventional VHS method.

Differences between the groups were also not significant (Table 1).

Cardiac long axis and short axis lengths in males were significantly longer than in females ($P < 0.0001$). Thoracic vertebral lengths (T4, T5 and T6) in males were also significantly longer than in females ($P < 0.0001$), but with no significant differences among each thoracic vertebral length in the same sex. Conventional VHS and applied VHS results of each thoracic vertebra (T4, T5 and T6) were not significantly different between male and female cats (Table 2).

Pearson's correlation test showed no statistical correlation between body weight and applied VHS ($r = -0.037$, $P = 0.716$, Figure 3). Age and applied VHS also showed no statistical correlation ($r = -0.148$, $P = 0.146$, Figure 4), while conventional VHS and applied VHS results had a strong positive correlation ($P < 0.0001$). Scatter plots of correlation between conventional VHS and applied VHS in each thoracic vertebra for left and right lateral views are shown in Figure 5 a-c and Figure 6 a-c.

Table 1 Measurement of VHS and applied VHS (T4, T5 and T6) in left lateral and right lateral view (data are reported as mean \pm SD No. of vertebrae). The results showed no significant difference between groups.

View	conventional VHS (v.)	Applied VHS (v.)		
		T4	T5	T6
Left lateral	7.2 \pm 0.45	7.17 \pm 0.48	7.11 \pm 0.47	7.03 \pm 0.47
Right lateral	7.43 \pm 0.44	7.43 \pm 0.47	7.38 \pm 0.46	7.29 \pm 0.47

Table 2 Comparison of cardiac length, cardiac short axis and thoracic vertebral length (T4, T5 and T6) between male and female on right lateral view. The data are reported as mean \pm SD (mm). The results showed significant difference between male and female.

Measurement	Male	Female	P value
Cardiac long axis length (mm)	47.08 \pm 2.97	43.93 \pm 3.71	< 0.0001
Cardiac short axis length (mm)	29.83 \pm 0.280	27.68 \pm 2.63	0.0002
T4 length (mm)	10.45 \pm 0.59	9.69 \pm 0.73	< 0.0001
T5 length (mm)	10.47 \pm 0.056	9.77 \pm 0.73	< 0.0001
T6 length (mm)	10.57 \pm 0.58	9.83 \pm 0.75	< 0.0001
Conventional VHS (v)	7.40 \pm 0.46	7.42 \pm 0.41	0.8530
Applied VHS T4 (v)	7.37 \pm 0.51	7.40 \pm 0.44	0.7913
Applied VHS T5 (v)	7.36 \pm 0.47	7.39 \pm 0.43	0.7698
Applied VHS T6 (v)	7.29 \pm 0.51	7.30 \pm 0.44	0.9357

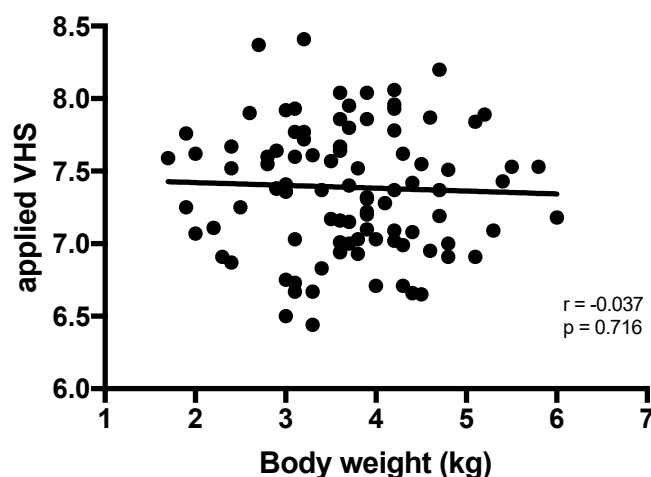


Figure 3 Results of Pearson's correlation test between body weight and applied VHS. The result showed no correlation between body weight and applied VHS.

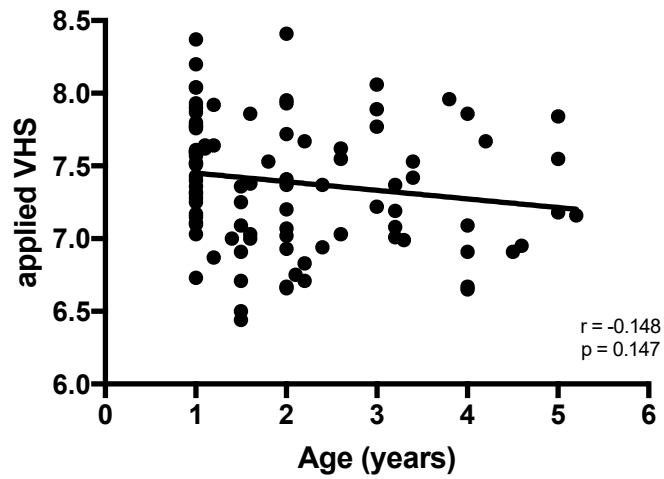


Figure 4 Results of Pearson's correlation test between age and applied VHS. The result showed no correlation between body weight and applied VHS.

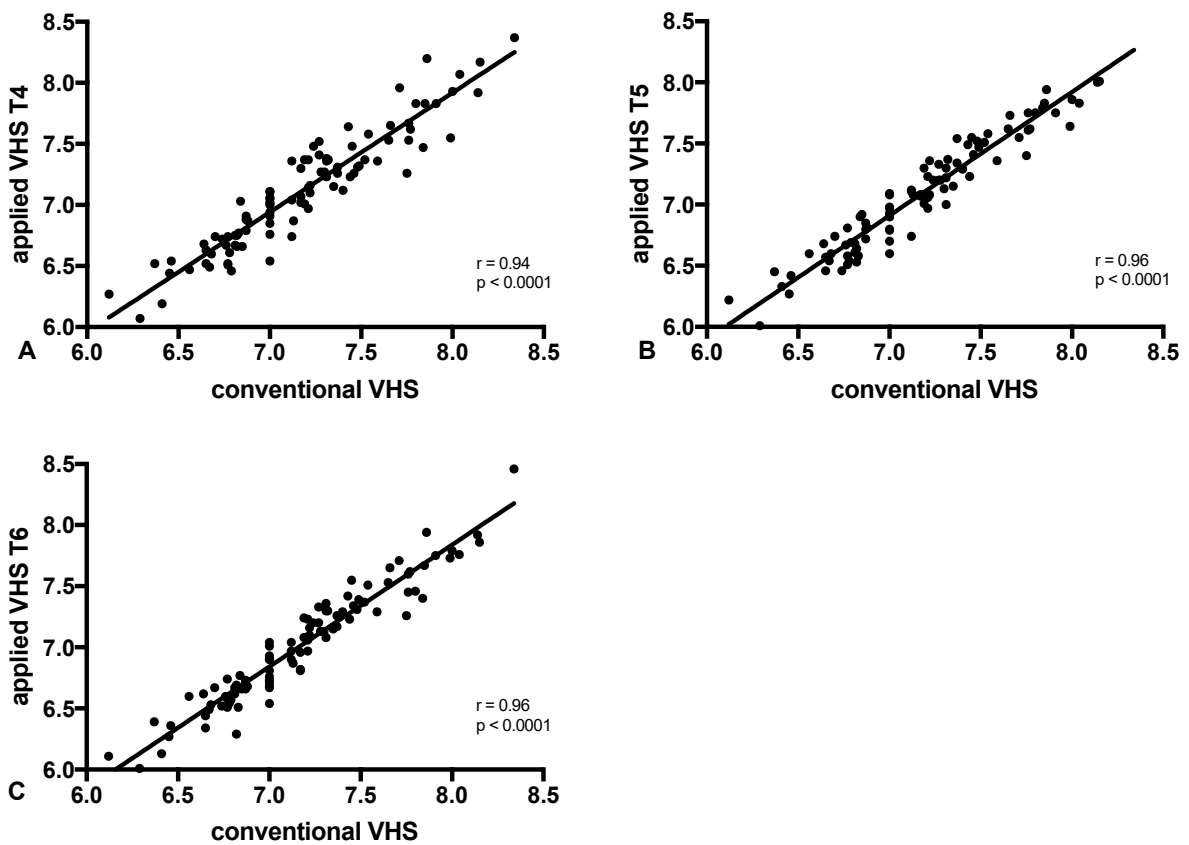


Figure 5 Results of Pearson's correlation test between conventional VHS and applied VHS on left lateral view. The Scatter plots of conventional VHS versus applied VHS T4 (A), applied VHS T5 (B) and applied VHS T6 (C) were shown.

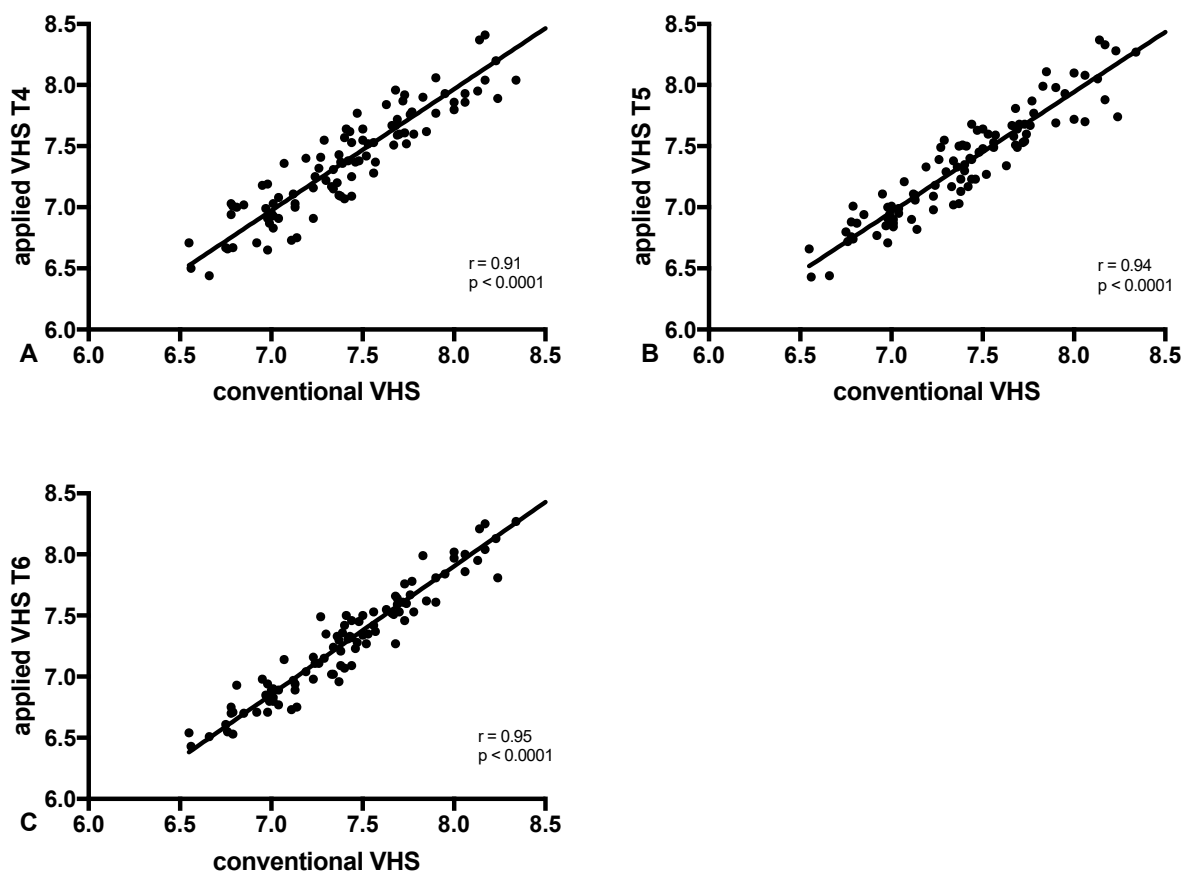


Figure 6 Results of Pearson's correlation test between conventional VHS and applied VHS on right lateral view. The Scatter plots of conventional VHS versus applied VHS T4 (A), applied VHS T5 (B) and applied VHS T6 (C) were shown.

Discussion

Prevalence of heart disease in asymptomatic and symptomatic cats was reported, with hypertrophic cardiomyopathy (HCM) the most common (Ferasin *et al.*, 2003). Congenital cardiovascular malformations and ventricular septal defects were also documented (Schrope DP, 2015; Tidholm *et al.*, 2015). Conventional VHS measurement was commonly used to evaluate heart size via thoracic radiography in cats suspected of having heart diseases.

However, for optimal accuracy of cardiac size evaluation using this VHS method, the animals should have a normal thoracic vertebral column. Abnormalities of thoracic vertebrae such as kyphosis due to juvenile secondary nutritional hyperparathyroidism, vertebral fracture, intervertebral disc disease (IVD), neoplasia and spondylosis deformans were reported in cats together with congenital transitional abnormality, while hemivertebrae and spina bifida are not common (Newitt *et al.*, 2008). These diseases might affect the accuracy of conventional VHS. To mitigate these circumstances, our applied VHS used only the length of each thoracic vertebra. There were two major reasons that we chose the T4, T5 and T6 vertebrae. Firstly, these thoracic vertebrae (T4, T5 and T6) are also used in the conventional VHS method by Lister and Buchanan (2000) and secondly, they are located dorsal to the heart and in the center of the x-ray beam when thoracic radiographs are performed.

Our results showed no significant differences among applied VHS for each thoracic vertebra (T4, T5 and T6), while the mean of the applied VHS method of each vertebra T4, T5 and T6 (7.17 ± 0.05 v, 7.11 ± 0.05 v, 7.03 ± 0.5 v) showed no significant difference compared to the conventional VHS method (7.2 ± 0.45) on LL radiography. The mean of the applied VHS method for each vertebra T4, T5 and T6 (7.43 ± 0.47 v, 7.38 ± 0.46 v, 7.29 ± 0.47 v) also showed no significant difference compared to the conventional VHS method (7.43 ± 0.44 v) on RL radiography. Male cats recorded cardiac long axis, short axis and thoracic vertebral length at longer than females but conventional VHS and applied VHS results were not significantly different.

The conventional VHS method is suitable for the assessment of heart size in cats. Apart from differences in VHS measurements from interbreeding or interpopulation variations (Alireza *et al.*, 2008), measurements of the intact normal T4-T6 thoracic vertebrae are necessary for the conventional VHS method. Non-linear alignment of thoracic vertebrae as a result of lordosis, kyphosis or improper positioning that may affect the accuracy to assess heart size. The applied VHS using only a single segment of thoracic vertebra might eliminate this limitation by choosing one of three thoracic vertebrae (T4, T5 or T6) that is not affected by thoracic vertebral alignment.

Results from this study suggest that no significant difference between the conventional VHS method and the applied VHS to assess actual heart size in cats. The correlation between conventional VHS and applied

VHS of each thoracic vertebrae are good. Therefore, the applied VHS can be used to estimate and monitor heart size in cats including those with abnormal thoracic vertebrae. Limitations of this study were only Thai domestic shorthair cats that were included. The variability in the measurement of applied VHS methods from interbreed or interpopulation cats should be considered and require further investigation. The effects of gonadal status on cardiac size and VHS were not investigated due to the small sample size of gonadectomized cats. Male and female cats gonadectomized at 7 weeks and 7 months of age show delayed physical closure time and longer radial length compared with intact cats (Root *et al.*, 1997). However, the effect of gonadal status on thoracic vertebral length remains unclear.

In conclusion, our applied VHS methods using each thoracic vertebrae T4, T5 and T6 can be used for heart size evaluation in Thai domestic shorthair cats. This method showed a good correlation with the conventional method. Our applied VHS method may be used to enhance the accuracy of heart size evaluation, including cats with abnormal thoracic vertebrae.

Acknowledgements

We would like to thank the animal owners for their cooperation. This work was supported by Small Animal Teaching Hospital, Faculty of Veterinary Medicine, Mahanakorn University of Technology.

References

- Alireza G, Reza A, Abdoirahman and Ali Y 2008. Radiographic measurement of vertebral in heart stray cats. *J Feline Med Surg.* 10: 61-65.
- Bavegems V, Caelenberg AV, Duchateau L, Sys SU, Bree HV and Rick AD 2005. Vertebral heart size ranges specific for whippets. *Vet radiol ultrasound.* 46: 400-403.
- Buchanan JW and Bucheler J 1995. Vertebral scale system to measure canine heart size in radiographs. *J Am Vet Med Assoc.* 206(2):194-199.
- Buchanan JW 2000. Vertebral scale system to measure heart size in radiographs. *Vet Clin North Am Small Anim Pract.* 30: 379-393.
- Etienne C, Kristin AM, Kathryn MM and Sleeper MM 2011. *Feline cardiology.* John Wiley and Sons, Inc. Oxford. P. 23-395.
- Ferasin L, Sturgess CP, Cannon MJ, Caney SMA, Gruffydd TJ and Wotton PR 2003. Feline idiopathic cardiomyopathy: a retrospective study of 106 cats (1994-2001). *J Feline Med Surg.* 5: 151-159.
- Greco A, Meomartino L, Raiano V, Fatone G. and Brunetti A 2008. Effect of left versus right recumbency on the vertebral heart score in normal dogs. *Radiology & Ultrasound.* 49(5): 454-455.
- Guglielmini C, Toaldo MB, Poser H, Menciotti G, Cipone M, Cordella A, Contiero B and Diana A 2014. Diagnostic accuracy of vertebral heart score and other radiographic indices in the detection of cardiac enlargement in cat with different cardiac disease. *J Feline Med Surg.* 16(10): 812-825.
- Jepsen-Grant K, Pollard RE and Johnson LR 2013. Vertebral Heart Scores in eight dog breeds. *Vet Radiol Ultrasound.* 54(1):3-8.
- Lamb CR, Wilkeley H, Boswood A, Pfeiffer DU 2001. Use of breed-specific ranges for the vertebral heart scale as an aid to the radiographic diagnosis of cardiac disease in dogs. *Vet Rec.* 148:707-711.
- Litster A, Atkins C, Atwell R and Buchanan J 2005. Radiographic cardiac size in cats and dogs with heartworm disease compared with reference values using the vertebral heart scale method: 53 cases. *J Vet Cardiol.* 7: 33-40.
- Litster AL and Buchanan JW 2000. Vertebral scale system to measure heart size in radiographs of cats. *J Am Vet Med Assoc.* 216(2): 210-214.
- Newitt A, German AJ and Barr FJ 2008. Congenital abnormalities of the feline vertebral column. *Vet Radiol Ultrasound.* 49(1): 35-41.
- Paige C, Abbott JA and Elvinger F. 2009. Prevalence of cardiomyopathy in apparently right healthy cats. *J Am Vet Med Assoc.* 234: 1398-1403.
- Root MV, Johnston SD and Olson PN 1997. The effect of pre- puberal and postpuberal gonadectomy on radial physeal closure in male and female domestic cats. *Vet Radiol Ultra- sound.* 38: 42-47.
- Schrope DP 2015. Prevalence of congenital heart disease in 76,301 mixed-breed dogs and 57,025 mixed-breed cats. *J Vet Cardiol.* 17(3):192-202.
- Sleeper MM and Buchanan J 2001. Vertebral scale system to measure heart size in growing puppies. *J Am Vet Med Assoc.* 219(1): 57-59.
- Sleeper MM, Roland R and Drobatz KJ 2013. Use of the vertebral heart scale for differentiation of cardiac and noncardiac causes of respiratory distress in cats: 67 cases (2002-2003). *J Am Vet Med Assoc.* 242: 366-371.
- Smith S and Dukes-McEwan J 2012. Clinical signs and left atrial size in cats with cardiovascular disease in general practice. *J Small Anim Pract.* 53: 27-33.
- Tidholm A, Ljungvall I, Michal J, Haggstrom J and Hoglund K 2015. Congenital heart defects in cats: a retrospective study of 162 cats (1996 - 2013). *J Vet Cardiol.* 17: 215-219.
- Tomsa K, Glaus T, Hauser B, Fluckiger M, Arnold P, Wess G and Reusch C 1999. Nutritional secondary hyperparathyroidism in six cats. *J Small Anim Pract.* 40: 533-539.