

12-1-2019

## Successful treatment of feline pseudomycetoma caused by *Microsporium canis*: a case study

Pansawut Sudjaidee

Thanida Sananmuang

Kanchanarut Mankong

Premsak Jeeratanyasakul

Follow this and additional works at: <https://digital.car.chula.ac.th/tjvm>



Part of the [Veterinary Medicine Commons](#)

---

### Recommended Citation

Sudjaidee, Pansawut; Sananmuang, Thanida; Mankong, Kanchanarut; and Jeeratanyasakul, Premsak (2019) "Successful treatment of feline pseudomycetoma caused by *Microsporium canis*: a case study," *The Thai Journal of Veterinary Medicine*: Vol. 49: Iss. 4, Article 15.

DOI: <https://doi.org/10.56808/2985-1130.3009>

Available at: <https://digital.car.chula.ac.th/tjvm/vol49/iss4/15>

This Report is brought to you for free and open access by the Chulalongkorn Journal Online (CUJO) at Chula Digital Collections. It has been accepted for inclusion in The Thai Journal of Veterinary Medicine by an authorized editor of Chula Digital Collections. For more information, please contact [ChulaDC@car.chula.ac.th](mailto:ChulaDC@car.chula.ac.th).

## Successful treatment of feline pseudomycetoma caused by *Microsporium canis*: a case study

Pansawut Sudjaidee<sup>1\*</sup> Thanida Sananmuang<sup>1</sup>

Kanchanarut Mankong<sup>2</sup> Premsak Jeeratanyasakul<sup>2</sup>

### *Abstract*

A 3.5-year-old, 3.9 kg, intact, male Persian cat was presented at the hospital for chronic multifocal nodular dermatitis. The lesions with ulcerated nodules and yellow granular discharge were found mainly on the body and tail. Fungal culture was positive to *Microsporium canis* and skin biopsy revealed multifocal extensive fungal granuloma throughout necrotic fibrosis. The cat was treated with itaconazole for 4 months and the lesions were slightly improved. The skin nodules localized on the body, except the tail, were eventually removed. Approximately 1 month after surgery, the cat was vaccinated with inactivated vaccine against mycotic disease caused by *Microsporium canis* two-week apart for two treatments. There was no recurrence of the dermatophyte infection at least 8 months after surgical treatment.

---

**Keywords:** Pseudomycetoma, *Microsporium canis*, feline

<sup>1</sup>Faculty of Veterinary Medicine, Rajamangala University of Technology Tawan-OK, 43 Moo 6 Bangpra, Sriracha, Chonburi 20110, Thailand

<sup>2</sup>Smile Dog Small Animal Hospital, 19/16 Mhoo 8, Samed, Muang, Chonburi 20130, Thailand

\*Correspondence: pansawut\_su@rmutto.ac.th (P. Sudjaidee)

## Introduction

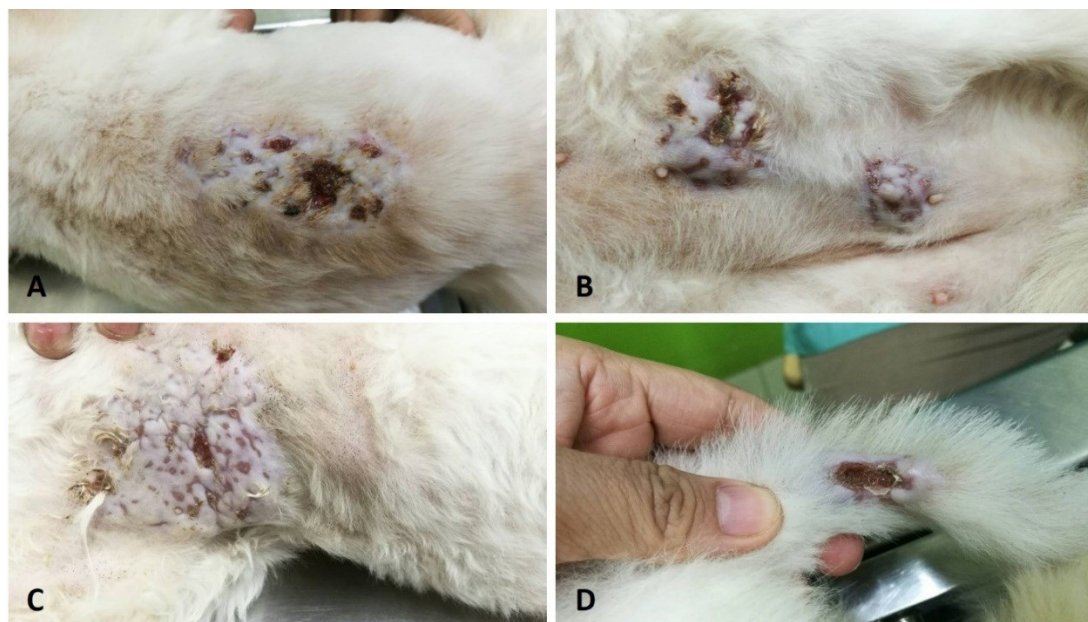
Pseudomycetoma is a subcutaneous and/or deeper dermal dermatophyte infection, which is sometimes called “subcutaneous mycosis” or “dermatophytic pseudomycetoma (DPM)” (Chang *et al.*, 2011). Persian cats are recognized as a breed predisposed to dermatophytic pseudomycetoma and the most common dermatophyte caused is *Microsporum canis* (Thian *et al.*, 2008; Nobre *et al.*, 2010; Chang *et al.*, 2011; Duangkaew *et al.*, 2017). The lesions are not restricted only to epidermal structures but also invade deeper into the dermal tissue and rupture the follicular structure causing multifocal nodular dermatitis (Chang *et al.*, 2011). Currently, the pathogenesis of the progression from cutaneous to subcutaneous mycosis is still unclear. Diagnosis of DPM includes wood’s lamp and trichograms of broken hairs affected by fungal hyphae. In addition, histopathology can confirm the diagnosis with coalescing foci of pyogranulomatous inflammation surrounding multiple, irregular basophilic hyphae-like elements in a sparse, granular, faintly eosinophilic matrix. These elements are strongly positive to Periodic acid Schiff staining. Treatment of DPM is quite difficult and the prognosis is poor since the outcome of antifungal drug (griseofulvin, ketoconazole, itraconazole) usage with/without surgical treatment is variable. Moreover, the lesions often recur after surgical excision (Chang *et al.*, 2011; Duangkaew *et al.*, 2017). Moreover, there has been a report revealing lack of griseofulvin, itraconazole or terbinafine in DPM (Bond *et al.*, 2001). This case report aims to report the pseudomycetoma of indoor Persian cats successfully treated by wide-margin surgery concurrent with *Microsporum canis* vaccination.

## Case Report

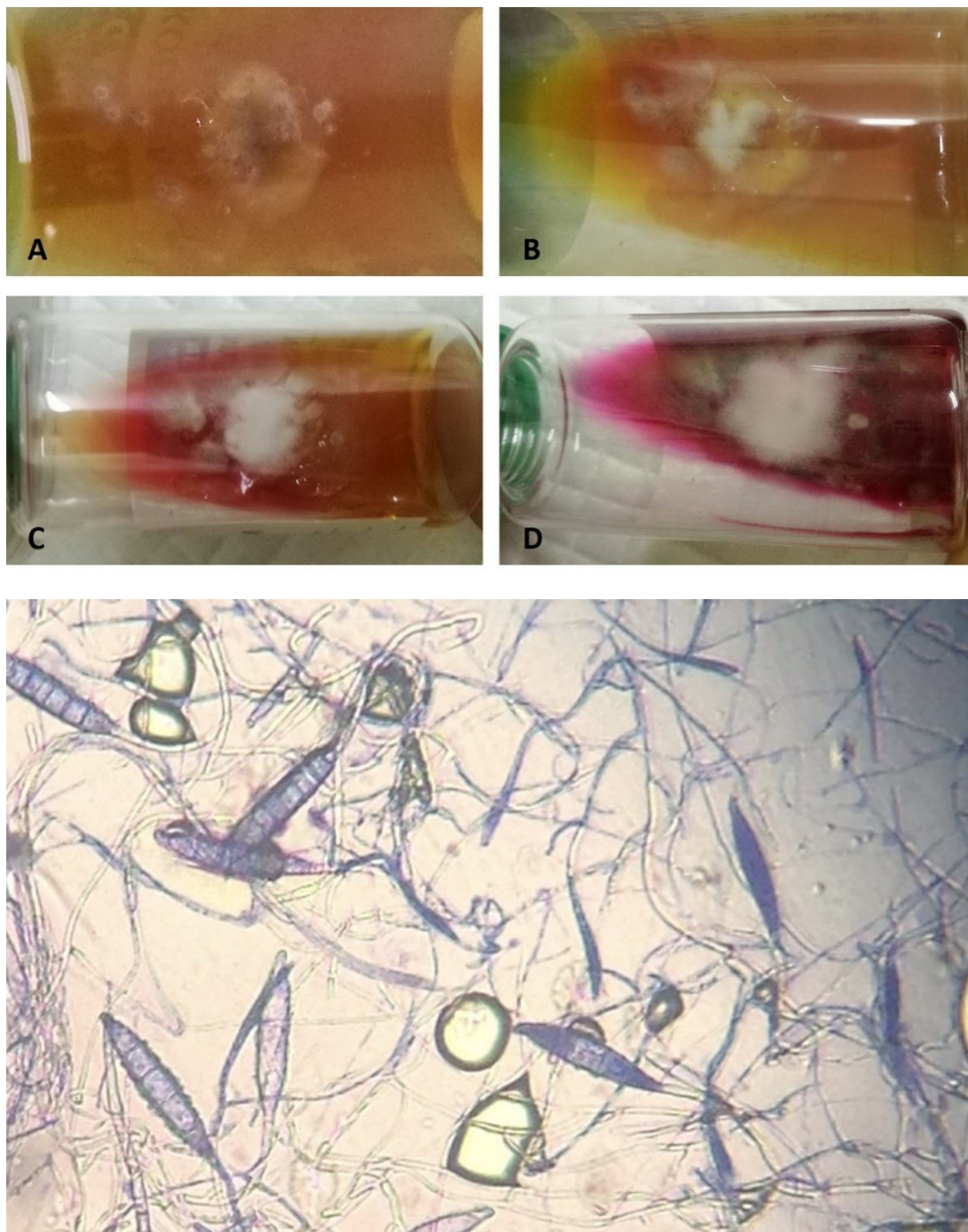
A 3.5-year-old, 3.9 kg, intact, male Persian cat presented at the hospital for chronic skin lesions. The

lesions, alopecia and multifocal ulcerated nodules with yellow granular discharge, were localized mainly on body and tail (Fig. 1). At first, the veterinary surgeon suspected common chronic dermatitis since cytology revealed large number of rod and cocci bacteria, neutrophils, mast cells and mononuclear cells without hyphae of dermatophyte. The cat was treated with oral antibiotic (amoxicillin and clavulanic acid, Clavamox®) at a dose of 25 mg/kg twice a day for two weeks but the lesions were still the same after treatment. Skin biopsy and fungal cultures were performed from the nodules on the third week of the treatment. From the dermatophyte culture, the result was positive to *Microsporum canis* (Fig. 2). The result of histopathology from the skin biopsy revealed multifocal extensive fungal granuloma throughout the fibrotic dermis. Each granuloma consisted of necrosis in the center, an accumulation of large arthrospore, numerous fungal hyphae recognized as *Microsporum spp.*, infiltration of neutrophils, foamy macrophages, lymphocytes and multinucleated giant cells (Fig. 3). The section was positive when stained with Periodic acid Schiff staining (Fig. 4). A diagnosis of pseudomycetoma caused by *Microsporum spp.* was made. The cat was then treated with antifungal drugs (Itraconazole) at a dose of 5 mg/kg orally once a day for two months. The skin lesions improved but were still present. The cat was then treated with antifungal drugs (Itraconazole) at a dose of 10 mg/kg orally once a day for two months. During the medical treatment, complete blood count, liver enzyme (ALT, ALKP), and renal panel tests (BUN and creatinine) were within normal. Feline leukemia and immunodeficiency tests were negative.

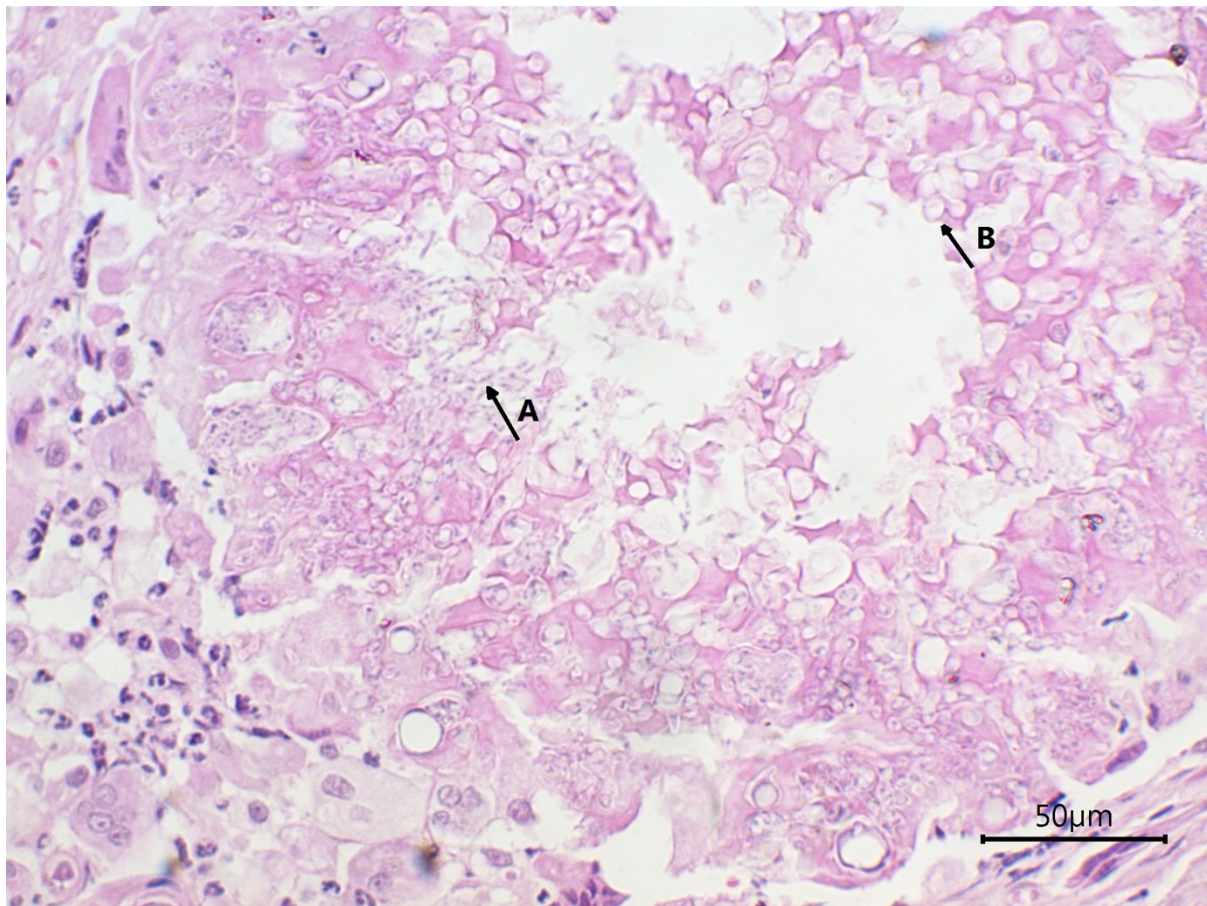
After 4 months of medical treatment, the lesions showed some improvement but were not completely cured. The owner decided to do a wide-margin surgical remove. After stitch removal, the killed dermatophyte vaccine (Biocan® M Plus vaccine, Biovetta Czech Republic) was used two times two weeks apart. There was no recurrence found for at least 2 years after surgical removed.



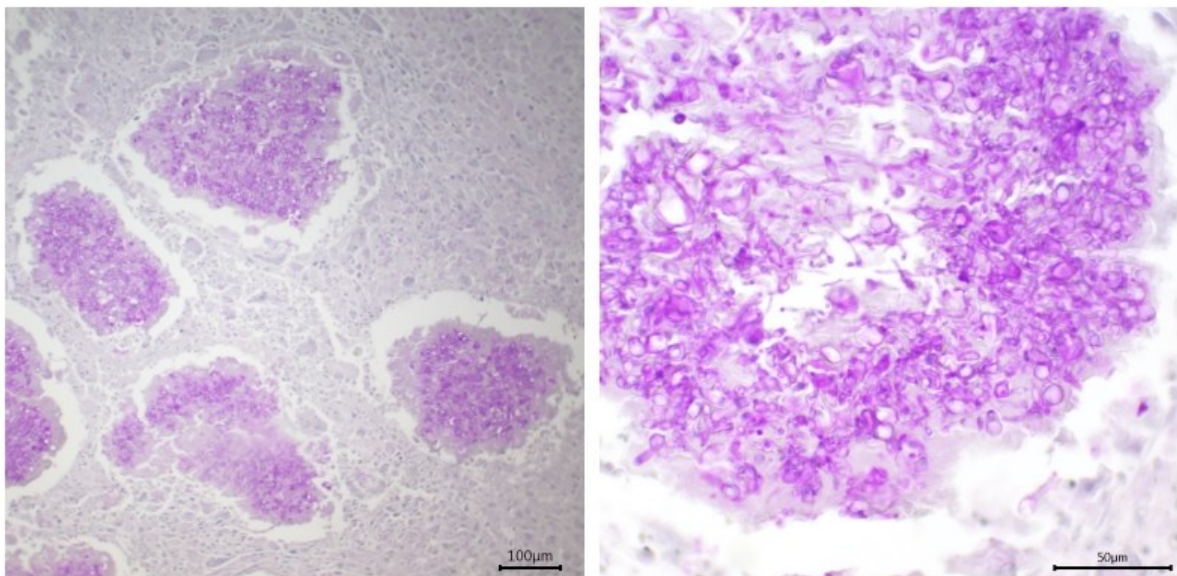
**Figure 1** The first observed lesions with ulcerated nodules with yellow granular discharge were found on dorsal (A), abdominal (B), chest (C) and tail (D).



**Figure 2** Fungal culture test on day-3 (A), day-4 (B), day-5 (C) and day-6 (D) revealed positive on *Microsporium canis* (E)



**Figure 3** The result of histopathology from skin biopsy stained with haematoxylin and eosin stain (H&E) revealed multifocal extensive fungal granuloma throughout the fibrotic dermis. Each granuloma consisted of necrosis in the center, an accumulation of large arthrospore (arrow B), numerous fungal hyphae recognized as *Microsporum spp.* (arrow A), infiltration of neutrophils, foamy macrophages, lymphocytes and multinucleated giant cells.



**Figure 4** The result of histopathology from skin biopsy stained with Periodic acid Schiff staining (PAS) revealed multifocal extensive fungal granuloma. Each granuloma consisted of an accumulation of large arthrospore and numerous fungal hyphae recognized as *Microsporum spp.*

### Discussion

Pseudomycetoma is a disease often seen Persian cats (Thian *et al.*, 2008; Nobre *et al.*, 2010; Chang *et al.*, 2011). Some researchers believe that poorly innate

immune response in some Persian cats may be involved in the development of pseudomycetoma (Thian *et al.*, 2008). The pathogenesis is still unclear but the fungal invasion might develop on hair shafts and invade deeper into hair follicles concurrent with poor

innate immunity causing pseudomycetoma in deeper dermis.

Oral antifungal drugs have failed to treat pseudomycetoma often seen in many reports (Nobre et al., 2010; Chang et al., 2011; Duangkaew et al., 2017) as presented in this study. Itraconazole was given at 5 mg/kg once a day even double dosage to 10 mg/kg once daily which had been proven in deep mycosis treatment in feline cryptococcosis (Pennisi et al., 2013) might be imply that the fungal disease probably needed immunity concurrent with drug treatment. Surgical removal alone has sometimes failed to treat pseudomycetoma (Thian et al., 2008; Nobre et al., 2010; Chang et al., 2011; Duangkaew et al., 2017). The combined treatment with oral antifungal drug with surgery yielded a better response in some cats but recurrence might be seen (Thian et al., 2008; Chang et al., 2011) while the lack of any antifungals response was noted in the previous study (Bond et al., 2001) as presented in this study. After two years monitoring, the lesion on the tail-surface was cured and no recurrence was found.

The inactivated dermatophyte vaccine is widely used in Europe and yields a good response in cats with natural-occurring superficial dermatophytosis (DeBoer and Moriello, 1995; Blanco and Garcia, 2008; Moriello et al., 2017). The better response might be related to post-exposure specific immunity development in superficial dermatophytosis but has not been used in pseudomycetoma cases. The vaccine was aimed to develop the specific immune response both in humoral and cell-mediated immunity (DeBoer and Moriello, 1995). In this case, there was no recurrence of the lesion after vaccination even though the antifungal was not given and there was no recurrence found after 2-year monitoring. This might imply the importance of specific immunity on fungal disease control (Moriello et al., 2017).

In conclusion, this case reported the successful treatment of pseudomycetoma in Persian cats by wide-margin surgical removal combined with inactivated dermatophyte vaccination. This might be used as an alternative treatment in disease recurrent control and management, yielding a good response in feline pseudomycetoma. However, the study in immune response from vaccination in disease-response and disease-failure cases should be further investigated.

### Acknowledgements

We would like to thank all our colleagues and staff from Smile Dog Small Animal Hospital for participation in the study and their technical support.

### References

- Blanco JL and Garcia ME 2008. Immune response to fungal infections. *Vet. Immunol. Immunopathol.* 125, 47-70.
- Bond R, Pocknell AM and Toze CE 2001. Pseudomycetoma caused by *Microsporum canis* in a Persian cat: lack of response to oral terbinafine. *J. Small Anim. Pract.* 42, 557-560.
- Chang SC, Liao JW, Shyu CL, Hsu WL and Wong ML 2011. Dermatophytic pseudomycetomas in four cats. *Vet. Dermatol.* 22, 181-187.
- DeBoer D. and Moriello K. 1995. Investigations of a killed dermatophyte cell-wall vaccine against infection with *Microsporum canis* in cats. *Res. Vet. Sci.* 59, 110-113.
- Duangkaew L, Larsuprom L, Kasondorkbua C, Chen C and Chindamporn A 2017. Cutaneous blastomycosis and dermatophytic pseudomycetoma in a Persian cat from Bangkok, Thailand. *Med. Mycol. Case Rep.* 15, 12-15.
- Moriello KA, Coyner K, Paterson S and Mignon B 2017. Diagnosis and treatment of dermatophytosis in dogs and cats. *Vet. Dermatol.* 28, 266-e68.
- Nobre MD, Mueller EN, Tillmann MT, Rosa CD, Guim TN, Vives P, Fernandes M, Madrid IM, Fernandes CG and Meireles MCA 2010. Disease progression of dermatophytic pseudomycetoma in a Persian cat. *Rev. Iberoam. Micol.* 27, 98-100.
- Pennisi MG, Hartmann K, Lloret A, Ferrer L, Addie D, Belak S, Boucraut-Baralon C, Egberink H, Frymus T, Gruffydd-Jones T, Hosie MJ, Lutz H, Marsilio F, Mostl K, Radford AD, Thiry E, Truyen U and Horzinek MC 2013. Cryptococcosis in cats: ABCD guidelines on prevention and management. *J. Feline Med. Surg.* 15, 611-618.
- Thian A, Woodgyer AJ and Holloway SA 2008. Dysgonic strain of *Microsporum canis* pseudomycetoma in a Domestic Long-hair cat. *Aust. Vet. J.* 86, 324-328.