

12-1-2019

## Variations in the branching pattern of the canine coeliac trunk in Thailand: an anatomical study

Rachanchai Chawangwongsanukun

Krai Meemon

Damri Darawiroj

Tuempong Wongtawan

Follow this and additional works at: <https://digital.car.chula.ac.th/tjvm>



Part of the [Veterinary Medicine Commons](#)

---

### Recommended Citation

Chawangwongsanukun, Rachanchai; Meemon, Krai; Darawiroj, Damri; and Wongtawan, Tuempong (2019) "Variations in the branching pattern of the canine coeliac trunk in Thailand: an anatomical study," *The Thai Journal of Veterinary Medicine*: Vol. 49: Iss. 4, Article 3.

DOI: <https://doi.org/10.56808/2985-1130.2997>

Available at: <https://digital.car.chula.ac.th/tjvm/vol49/iss4/3>

This Article is brought to you for free and open access by the Chulalongkorn Journal Online (CUJO) at Chula Digital Collections. It has been accepted for inclusion in The Thai Journal of Veterinary Medicine by an authorized editor of Chula Digital Collections. For more information, please contact [ChulaDC@car.chula.ac.th](mailto:ChulaDC@car.chula.ac.th).

# Variations in the branching pattern of the canine coeliac trunk in Thailand: an anatomical study

Rachanchai Chawangwongsanukun<sup>1</sup> Krai Meemon<sup>2</sup>

Damri Darawiroj<sup>3\*</sup> Tuempong Wongtawan<sup>1,4,5\*</sup>

## Abstract

Although the major dog population in Thailand is the Thai native dog, its anatomy has rarely been studied. This study aimed to investigate anatomical variations of the canine coeliac trunk (CT) in Thailand by observing 62 cadavers including 46 Thai native dogs and 16 non-Thai native dogs. All cadavers were preserved in formalin solution, and the arteries were illustrated by injection of red coloured latex. Variations of CT were initially classified into 2 main types and 7 subtypes (type 1a-e and 2a-b) based on the previous reports. Type 1 was described as CT separated from the cranial mesenteric artery (CMA) while type 2, CT fused with CMA and called the coeliacomesenteric trunk (CMT). In this study, only 5 of 7 patterns were found (1a-c and 2a), but a new variation was identified as type 2c. The common patterns were type 1a (CT bifurcated into the gastrosplenic and hepatic arteries; 53.2%) and type 1b (CT trifurcated into the hepatic, left gastric and splenic arteries; 40.3%). The CMT was observed only at 3.2% while two types (1d-e) were not observed in this study. The male and female were different in the most common patterns (1b and 1a, respectively). Thai native dogs showed similar result to all dog results. To the authors' knowledge, this is the first study concerning anatomical variations of the canine coeliac trunk of dogs in Thailand. This study is useful for facilitating imaging diagnosis and surgical treatment and also provides important knowledge for understanding the pathogenesis of the coeliac trunk related diseases.

---

**Keywords:** Branching pattern, Coeliac trunk, Coeliacomesenteric trunk, Thai native dogs

<sup>1</sup>Department of Preclinic and Applied Animal Science, Faculty of Veterinary Science, Mahidol University, Salaya, Puttamonthon, Nakhon Pathom, 73170, Thailand.

<sup>2</sup>Department of Anatomy, Faculty of Science, Mahidol University, Phayathai, Ratchathewi, Bangkok, 10400, Thailand.

<sup>3</sup>Department of Anatomy, Faculty of Veterinary Science, Chulalongkorn University, Pathumwan, Bangkok, 10330, Thailand.

<sup>4</sup>Laboratory of Cellular Biomedicine, Faculty of Veterinary Science, Mahidol University, Salaya, Puttamonthon, Nakhon Pathom, 73170, Thailand.

<sup>5</sup>Current address, Akkhraratchakumari Veterinary College (AVC), Walailak University, 222 Thaiburi, Thasala, Nakhon Si Thammarat, 80160, Thailand.

\*Correspondence: tuempong@gmail.com, damri@chula.ac.th (T. Wongtawan, D. Darawiroj)

## Introduction

Knowledge of anatomical variations is essential to understanding canine physiology and pathology. It is also useful for imaging diagnosis, medicine and surgical operations. However, there are only few reports related to the pattern of anatomical variations of canine vessels compared to human studies (Abidu-Figueiredo *et al.*, 2005, Avedillo *et al.*, 2016).

The present study focused on the branching pattern of the coeliac trunk (CT) (also known as the coeliac artery) and its anatomical relation to the cranial mesenteric artery (CMA). The CT and CMA are the first and second visceral branches originating from the abdominal aorta, respectively. The CT is the second largest branch of the abdominal aorta, its terminal branches are the hepatic, splenic, and left gastric arteries supplying blood to the liver, spleen, and stomach, respectively. The CMA is the largest visceral branch of the canine aorta. It passes through the mesentery and supplies blood to intestines (Evan & Lahunta, 2013). The CT and CMA also attach to the coeliac and mesenteric nerve plexuses, the largest nerve network in the abdomen that controls the function of abdominal visceral organs (Evan & Lahunta, 2013). The anatomy of the CT and CMA is important for surgery and medicine. An occlusion or compressing of these vessels may cause visceral ischaemia and neurological disorders (Kazan *et al.*, 2013, Loukas *et al.*, 2007). The location and pattern of the coeliac trunk can be used to locate the coeliac and mesenteric plexuses for the treatment of severe abdominal pain and for postoperative ileus resolution (Ravasio *et al.*, 2015).

A previous study demonstrates that the coeliac trunk in some dogs (9%) has been compressed by median arcuate ligament of diaphragm (Le Pommellet *et al.*, 2018). In humans, the compression of the CT is clinically important because it can affect the blood circulation and nerve function resulting in abdominal pain and weight loss (Kazan *et al.*, 2013, Loukas *et al.*, 2007). However, the relation of the compression of the coeliac trunk to clinical problems in dogs is still inconclusive and requires more study (Le Pommellet *et al.*, 2018). Some abnormalities of CMA can be found in dogs, for example, canine mesenteric artery ischaemia (also known as cranial mesentery block). This abnormality is caused by thromboembolism (Sakaguchi *et al.*, 2002) or rotation of the root of mesentery (Junius *et al.*, 2004) causing the death of dogs. Notably, the study of the CT and the cranial mesenteric artery is not only essential for dogs but is also being used as a model for visceral ischaemia in human (Bonakdarpour *et al.*, 1975, Mandarry *et al.*, 2010, Romano *et al.*, 2011).

A few studies of the anatomical variation of the canine CT and CMA have been done, and six branching patterns have been found (Kennedy & Smith, 1930, Roza *et al.*, 2012, Schmidt & Schoenau, 2007) but a summary of branching patterns has never been reported. In human studies, the coeliac trunk variation can be found in more than fifteen patterns (De Martino, 2015, Yi *et al.*, 2007).

The present study investigated the variation of canine coeliac trunks in Thailand. The majority of dogs

in Thailand are Thai native dogs which are unique and ancient with regard to genetics, archaeology and biogeography studies from years ago (Boonyaparakob *et al.*, 2017, Larson *et al.*, 2012, Pilot *et al.*, 2015, Wang *et al.*, 2016). Most Thai native dogs are free-breeding and considered to be mongrels except for the Thai Ridgeback breed that is registered by the world dog organisation (Federation Cynologique Internationale, 2004), and their anatomies have not been recorded.

The aim of the study was to reveal the branching patterns of CT of dogs in Thailand and compare them to those of previous studies.

## Materials and Methods

**Cadavers:** All canine cadavers in this study had naturally died from non-infectious diseases and were donated to the Faculties of Veterinary Science (Mahidol and Chulalongkorn Universities) for being used in teaching veterinary gross anatomy.

This study was performed on dissected cadavers previously used for gross anatomy learning by veterinary students. This research project was approved by the Animal Care and Use Committee, Faculty of Veterinary Science, Mahidol University. Forty-six cadavers of Thai native dogs (none were Ridgebacks) were observed (26 males/ 20 females) and sixteen non-Thai native dogs (4 golden retrievers, 3 beagles, 3 Labrador retrievers, 1 Dalmatian, 1 French bulldog, 2 Siberians huskies, and 2 poodles) were also included in the study (8 males/ 8 females). In total, the number of male dogs was 34 and females 28. The dogs' ages were approximately 8 to 12 years old and their body weight was between 5 and 15 kg.

**Cadaver preparation:** After donation, the cadavers were kept either in 4 °C (1 to 3 days at Chulalongkorn University) or -20 °C freezer (1 to 2 weeks at Mahidol University) until embalming. Thereafter, the cadavers were thawed at room temperature for a day and then a preservative chemical solution (a mixture of formaldehyde, glycerine, and phenol) was injected into the left common carotid artery of the specimens until an excess amount of solution leaked out from their noses and the body (abdomen) of the cadavers began to swell. A day later, approximately 500 mL of red coloured latex was injected by a pressure pump into the left common carotid artery to clearly illustrate arterial vessels. The cadavers were then kept at room temperature for a day before they were immersed in diluted formalin solution for long-term storage.

Most of the dogs in the present study were Thai native dogs. Their body weight was about 10-15 kg and they had short hair with colours that were white, brown, black, grey or mixed (Figure 1).

**Classification of branching patterns:** The classification of the CT patterns was based on our observation and previous reports (Abidu-Figueiredo *et al.*, 2005, Araujo Neto and Campos, 2015, Awal *et al.*, 2001, Kennedy & Smith, 1930, Le Pommellet *et al.*, 2018, Ricciardi *et al.*, 2013, Roza *et al.*, 2012, Schmidt & Schoenau, 2007). According to the information from previous studies, we categorised branching patterns into two major groups (Figure 2): type 1, the CT and CMA arose

separately from the abdominal aorta while type 2, the CT and CMA shared common trunk called coeliacomesenteric trunk (CMT) before branching. Seven subtypes were subsequently identified and named type 1a, 1b, 1c, 1d, 1e, 2a, and 2b as shown in Figure 2.

Type 1a was described as the CT bifurcated to the hepatic artery and gastrosplenic trunk which later branched into the left gastric and splenic arteries. In Type 1b, the CT trifurcated into the hepatic, left gastric and splenic arteries. Type 1c, the CT had a bifurcation of hepatic and left gastric arteries while the splenic

artery branched off as the first branch of the CMA. In Type 1d, the CT trifurcated into the splenic artery, the gastroduodenal artery and the gastrosplenic trunk which branched into the left gastric and hepatic arteries. In Type 1e, the CT branched into the two-left gastric, splenic, and hepatic arteries.

In type 2a, the CMA and CT branched off from the CMT, after that, the CT trifurcated into the hepatic, left gastric and splenic arteries whereas in type 2b, the first two branches of the CMT were the hepatic and left gastric arteries followed by the bifurcation of the splenic artery and the CMA.



Figure 1 The appearance of the Thai native dog.

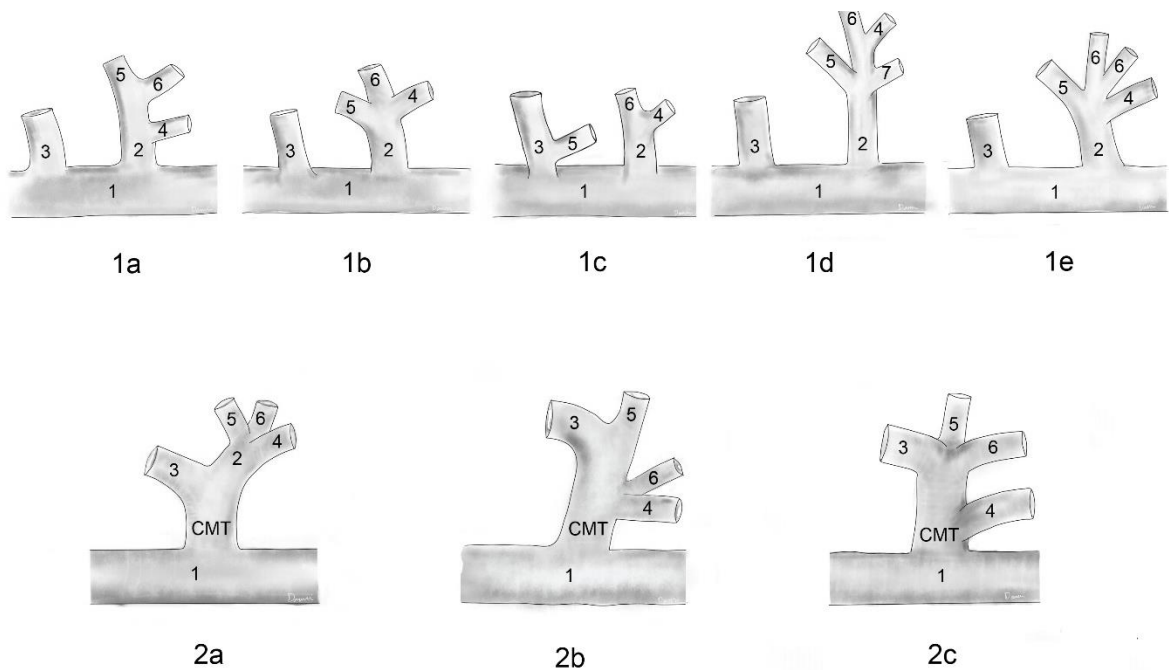


Figure 2 Branching patterns of the coeliac trunk that can be found in our study and previous studies. 1= the abdominal aorta, 2 = the coeliac trunk (CT), 3 = the cranial mesenteric artery (CMA), 4 = the hepatic artery, 5 = the splenic artery, 6 = the left gastric artery, 7 = the gastroduodenal artery and the CMT = the coeliacomesenteric trunk.

## Results

The occurrence of each branching pattern in all dogs is summarised in Table 1, and the occurrence in Thai native dogs is shown in Table 2. From observation, 93.5% of all specimens were type 1a and 1b (53.2% and 40.3%, respectively). These common patterns were also observed in Thai native dogs (95.6%) in which type 1a was 45.3% and type 1b was 41.3%.

In the present study, we found a new pattern of the coeliac trunk in a Labrador retriever and placed it into type 2c (Figure 2 and 3). This pattern was described by the CMT gave the hepatic artery as a first branch, and then trifurcation of the CMA, splenic and left gastric arteries. Two subtypes (type 1d and 1e) were not found

in this study. Moreover, types 1c, 2a, 2b, and 2c were rarely found (6.4%) and each type was only found in one dog. Type 2a and 2b were identified in Thai native dogs, and type 1c was found in a Golden retriever.

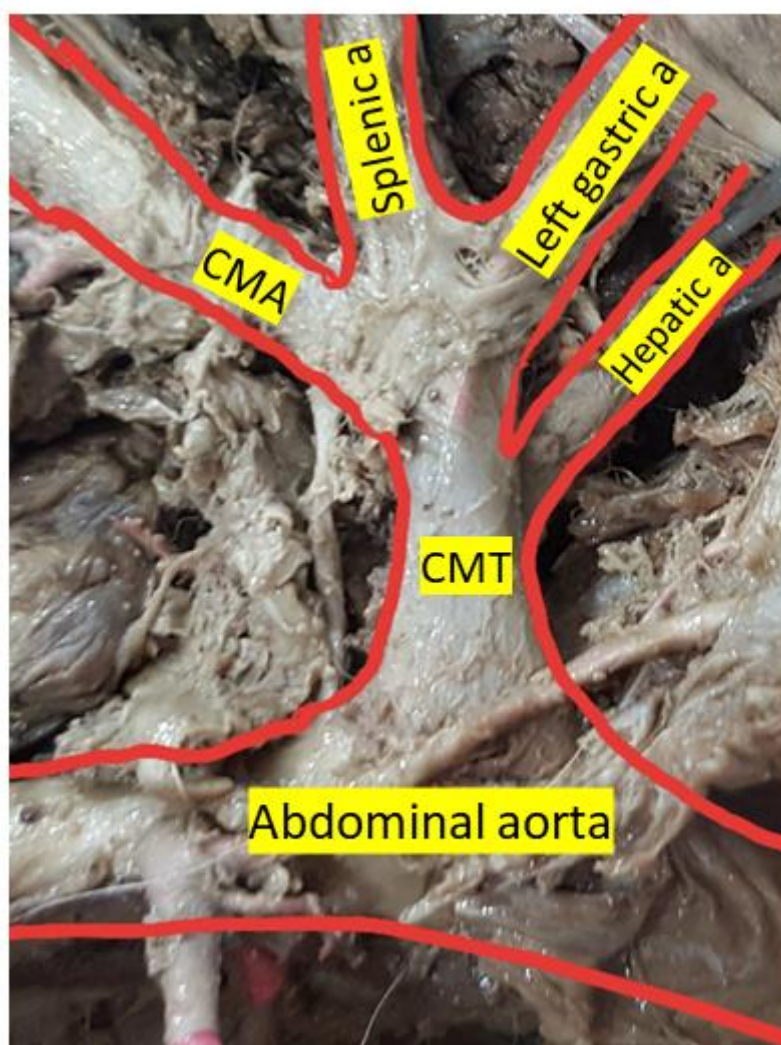
A comparison between male and female dogs revealed that the most common branching pattern of male dogs was type 1b (50.0%) which was slightly higher than type 1a (47.1%) (Table 1). On the other hand, type 1a was the most common pattern found in female dogs, and the occurrence was clearly different from type 1b (60.7% Vs 28.6%). A difference in the most common pattern between male and female dogs was also observed in Thai native dogs (Table 2), the most common pattern in the male Thai native dogs was type 1b (50.0%) while in the female, it was type 1a (65.0%).

**Table 1** The occurrence of branching patterns of the coeliac trunk in all dogs.

Type	Sub Type	Comparison by sex		
		All n (%)	Males n (%)	Females n (%)
1	1a	33 (53.2)	16 (47.1)	17 (60.7)
	1b	25 (40.3)	17 (50.0)	8 (28.6)
	1c	1 (1.6)	0 (0.0)	1 (3.6)
	1d	0 (0.0)	0 (0.0)	0 (0.0)
	1e	0 (0.0)	0 (0.0)	0 (0.0)
	Sub Total	59 (95.2)	33 (97.1)	26 (92.9)
2	2a	1 (1.6)	1 (2.9)	0 (0.0)
	2b	1 (1.6)	0 (0.0)	1 (3.6)
	2c	1 (1.6)	0 (0.0)	1 (3.6)
	Sub Total	3 (4.8)	1 (2.9)	2 (7.1)
<b>Total</b>	<b>62 (100)</b>	<b>34 (100)</b>	<b>28 (100)</b>	

**Table 2** The occurrence of branching patterns of the coeliac trunk found in Thai native dogs.

Type	Sub type	Comparison by sex		
		All n (%)	Males n (%)	Females n (%)
1	1a	25 (45.3)	12 (46.2)	13 (65.0)
	1b	19 (41.3)	13 (50.0)	6 (30.0)
	1c	0 (0.0)	0 (0.0)	0 (0.0)
	1d	0 (0.0)	0 (0.0)	0 (0.0)
	1e	0 (0.0)	0 (0.0)	0 (0.0)
	Sub total	44 (95.6)	26 (96.2)	19 (95.0)
2	2a	1 (2.2)	1 (3.8)	0 (0.0)
	2b	1 (2.2)	0 (0.0)	1 (5.0)
	Sub total	2 (4.4)	1 (3.8)	1 (5.0)
<b>Total</b>	<b>46 (100)</b>	<b>26 (56.5)</b>	<b>20 (43.5)</b>	



**Figure 3** Type 2c, the new type found in this study. This pattern was described as the CMT gave the hepatic artery as a first branch, and then trifurcation of the CMA, splenic and left gastric arteries

### Discussion

In the present study, we identified six branching patterns of the coeliac trunk from the cadavers including types 1a to 1c and 2a to 2c. Notably, type 2c was the new pattern, however, two subtypes (type 1d and 1e) that had been reported in other studies (Awal *et al.*, 2001, Le Pommellet *et al.*, 2018) were not observed in this study. Additionally, the extraordinary pulmonary branch reported by Roza *et al.* (2012) was also not found in this study.

The common patterns in the present study were types 1a and 1b which accounted for more than 90% of dogs. These two common patterns were also observed by Abidu-Figueiredo *et al.* (2005). Conversely, Le Pommellet *et al.* (2018) reported type 1a as the common pattern but type 1b was not observed, and others (Evans & de Lahunta, 2013, Dyce *et al.*, 2010) stated that type 1b was the common pattern while type 1a was rare. Notably, for the first time, the present study revealed a difference in the most common pattern of the coeliac trunk between male and female dogs (particularly Thai native dogs); this difference has never been reported in other species. A knowledge of the difference in the common pattern between sexes and breeds is useful for imaging diagnosis and

surgery. It has been reported that the coeliac trunk variations increase the difficulty and risk of abdominal operations and require preoperative imaging evaluation (Huang *et al.*, 2015).

The CMT (type 2) was infrequent in dogs. It was found in 4.8% of the present study, 2.3% in the study of Le Pommellet *et al.*, (2018), and two case reports (Kennedy & Smith, 1930, Ricciardi *et al.*, 2014). In comparison to other species of mammals, the CMT was not found in rabbits (Abidu-Figueiredo *et al.*, 2008, Estruc *et al.*, 2015), cattle (Khalifa, 2013), goats (Alsafy, 2009), chinchillas (Ozdemir *et al.*, 2013) and it was extremely rare in humans (<1%) (De Martino, 2015), but a higher occurrence of the CMT was observed in cats (15%) (Le Pommellet *et al.*, 2018) and sheep (39%) (Langenfeld & Pastea, 1977). Surprisingly, the CMT was very common (nearly 100% occurrence) in some rodents such as the degus and guinea pigs (Petrenko, 2014, Bednárová Z & Malinovský, 1990, Shively & Stump, 1975) and was also the most frequently observed pattern in non-mammalian species such as bullfrogs (Ichimura *et al.*, 2001) and Pirarucu fish (Santos *et al.*, 2007).

From a clinical point of view, the CMT can cause more clinical and surgical complications, therefore a preoperative knowledge of vascular anomalies is

necessary when planning a surgical approach (Sangster *et al.*, 2014). The occlusive diseases of the CMT may create more serious ischaemic consequences to the abdominal visceral organs due to no redundancy between the coeliac and mesenteric arterial circulation (Ailawadi *et al.*, 2004). From the evolution perspective, the incidence of the CMT may represent the anatomical evolution of vertebrates. The low occurrence of the CMT may represent the high development of the abdominal aorta due to the separation of the coeliac trunk and the CMA can help to compensate the blood flow when occlusion occurs in one of these vessels. The theory of blood flow compensation between the coeliac trunk and the CMA has already been shown in a previous study in dogs (Keskitalo *et al.*, 1976).

In conclusion, the present study proposed that there were eight variations of the branching pattern of the coeliac trunk in dogs in which type 1a and 1b were the most common patterns. However, the most common pattern in male dogs was type 1b while type 1a was the most common pattern in female dogs. A knowledge of anatomy of coeliac trunk is useful for teaching veterinary anatomy and can be applied surgery and imaging diagnosis.

### Acknowledgements

This research did not receive any specific grant from funding agencies in the public, commercial, or not-for-profit sectors. We would like to thank Mr Somchai Sa-ingkaew for technical assistance.

### References

- Abidu-Figueiredo M, Dias GP, Cerutti S, Carvalho-De-Souza B, Maia RS and Babinski MA 2005. Variations of celiac artery in dogs: Anatomic study for experimental, surgical and radiological practice. *Int J Morphol.* 23: 37-42.
- Abidu-Figueiredo M, Xavier-Silva B, Cardinot TM, Babinski MA and Chagas MA 2008. Celiac artery in New Zealand rabbit: anatomical study of its origin and arrangement for experimental research and surgical practice. *Pasq. Vet. Bras.* 28: 237-240.
- Ailawadi G, Cowles RA, Stanley JC, Eliason JL, Williams DM, Colletti LM, Henke PK and Upchurch GR Jr. 2004. Common celiacomesenteric trunk: aneurysmal and occlusive disease. *J Vasc Surg.* 40: 1040-1043.
- Araujo Neto and AR and Campos DB 2015. Characterization of the celiac and cranial mesenteric arteries in a dog: Case report of anatomical variation. *Aust J Bas Appl Sci.* 9:30-33.
- Avedillo L, Martin-Alguacil N and Salazar I 2016. Anatomical Variations of the Blood Vascular System in Veterinary Medicine. The Internal Iliac Artery of the Dog. Part Two. *Anat Histol Embryol.* 45: 88-99.
- Awal MA, Asaduzzaman M, Anam MK, Prodhon MA and Kurohmaru M 2001. Arterial supply to the stomach of indigenous dog (*Canis familiaris*) in Bangladesh. *Exp Anim.* 50: 349-352.
- Bednářová Z and Malinovský L 1990. Variability of branching of the a. coeliaca (truncus coeliacomesentericus) in the guinea pig (*Cavia aperea f. porcellus*). *Folia Morphol (Praha).* 38: 382-395.
- Bonakdarpour A, Ming S, Lynch PR, Essa N and Reichle F 1975. Superior mesenteric artery occlusion in dogs: a model to produce the spectrum of intestinal ischemia. *J Surg Res.* 19: 251-257.
- Boonyaparakob U, Homsavart S, Noosud J and Tungtrakanpoung R 2017. Cloning and comparative analysis of zinc-finger protein gene on Y-chromosome (ZFY) between Thai Bangkaew dog and other Thai canids. *Agr Nat Resources.* 51(3): 212-217.
- De Martino RR 2015. Normal and Variant Mesenteric Anatomy. In: *Mesenteric Vascular Disease: Current Therapy* GS Oderich (ed) New York: Springer.
- Dyce KM, Sack WO and Wensing CJG 2010. *Textbook of veterinary anatomy.* 4th ed. Missouri: Saunderv Elsevier. 840pp.
- Estruc TM, Nascimento RM, Siston NM, Mencalha R and Abidu-Figueiredo M 2015. Origin and main branches of the cranial and caudal mesenteric arteries in the New Zealand Rabbit. *J Morphol Sci.* 32: 143-148.
- Evans HE and De Lahunta A 2013. *Miller's Anatomy of the Dog.* 4th ed. Missouri: Elsevier Saunders. 1113pp.
- Federation Cynologique Internationale (FCI) 2004. "Thai ridgeback dog". [Online]. Available: <http://www.fci.be/en/nomenclature/THAI-RIDGEBACK-DOG-338.html>. Accessed Nov 9, 2019.
- Huang Y, Mu GC, Qin XG, Chen ZB, Lin JL and Zeng YJ 2015. Study of celiac artery variations and related surgical techniques in gastric cancer. *World J Gastroentero.* 21: 6944-6951.
- Ichimura K, Koizumi K, Kudoh H, Miyaki T and Sakai T 2001. A novel branching pattern of the superior mesenteric artery found in the bullfrog (*Rana catesbeiana*) amphibian. *J Anat.* 198: 625-633.
- Junius G, Appeldoorn AM and Schrauwen E 2004. Mesenteric volvulus in the dog: a retrospective study of 12 cases. *J Small Anim Pract.* 45: 104-107.
- Kazan V, Qu W, Al-Natour M, Abbas J and Nazzal M 2013. Celiac artery compression syndrome: a radiological finding without clinical symptoms. *Vascular.* 21: 293-299.
- Kennedy HN and Smith AW 1930. An abnormal celiac artery in dog. *Vet Rec.* 10: 751.
- Keskitalo E, Koikkalainen K, Meurala H and Teppo L 1976. Acute coeliac artery occlusion: initial collateral blood flow from the superior mesenteric artery. An experimental study. *Annales Chirurgiae et Gynaecologiae.* 65: 158-161.
- Langenfeld M and Patea E 1977. Anatomical variants of the celiac artery in the sheep, with special reference to the celiacomesenteric arterial trunk. *Anatomischer Anzeiger.* 142: 168-174.
- Larson G, Karlsson EK, Perri A, Webster MT, Ho SY, Peters J, Stahl PW, Piper J, Lingaas F, Fredholm M, Comstock KE, Modiano JF, Schelling C, Agoulnik AI, Leegwater PA, Dobney K, Vigne JD, Vil C, Andersson L and Lindblad-Toh K 2012. Rethinking dog domestication by integrating genetics, archeology, and biogeography. *PNAS.* 109: 8878-8883.

- Le Pommellet HM, Scansen BA, Mathys DA, Mollenkopf DF, Reeves L, Skinas ML and Patel M 2018. Arterial anomalies of the celiac trunk and median arcuate ligament compression in dogs and cats assessed by computed tomography angiography. *Vet Surg*. 47: 252-260.
- Loukas M, Pinyard J, Vaid S, Kinsella C, Tariq A and Tubbs RS 2007. Clinical anatomy of celiac artery compression syndrome: a review. *Clin Anat*. 20: 612-617.
- Mandarray MT, Zhao L, Zhang C and Wei ZQ 2010. A comprehensive review of superior mesenteric artery syndrome. *Eur Surg*. 42: 229-236.
- Ozdemir V, Demirkan C and Akosman MS 2013. Subgross and macroscopic investigation of the coeliac artery in the chinchilla (*Chinchilla lanigera*). *Folia Morphol*. 72: 258-262.
- Petrenko VM 2014. Visceral lymph nodes in abdominal cavity of degus. *Eur J Nat His*. 5: 32-33.
- Pilot M, Malewski T, Moura AE, Grzybowski T, Oleński K, Ruś A, Kamiński S, Ruiz Fadel F, Mills DS, Alagaili AN, Mohammed OB, Kłys G, Okhlopkov IM, Suchecka E and Bogdanowicz W 2015. On the origin of mongrels: evolutionary history of free-breeding dogs in Eurasia. *Proc R Soc Lond B Biol Sci*. 282: 20152189.
- Ravasio G, Carotenuto AM, Roccabianca P, Casati E, Fonda D and Borghi L 2015. Celiac and cranial mesenteric block in dogs: preliminary cadaveric study using a blind technique. *Vet Anaesth Analg*: 42: A23.
- Ricciardi M, Martino R and Assad EA 2014. Imaging diagnosis--celiacomesenteric trunk and portal vein hypoplasia in a pit bull terrier. *Vet Radiol Ultrasound*. 55: 190-194.
- Romano N, Prosperi V, Basili G, Lorenzetti L, Gentile V, Luceretti R, Biondi G and Goletti O 2011. Acute thrombosis of the superior mesenteric artery in a 39-year-old woman with protein-S deficiency: a case report. *J Med Case Report*: 5: 17.
- Roza MS, Marinho GC, Pereira JA, Salvador-Gomes M and Abidu-Figueiredo M 2012. Celiac artery with a pulmonary branch in dog: a rare variation. *J Morphol Sci*. 29: 253-255.
- Sakaguchi S, Minowa K, Shibanushi T, Ichino M, Mitsuoka H, Unno N, Yamamoto N and Nakamura S 2002. Revascularization to prevent postoperative bowel infarction after surgery for acute superior mesenteric artery thromboembolism. *Surg Today*. 32: 243-248.
- Sangster G, Ramirez S, Prevgliano C, Al Asfari A, Hamidian JA and Simoncini A (2014). Celiacomesenteric trunk: a rare anatomical variation with potential clinical and surgical implications. *J Louisiana State Med Soc*. 166: 53-55.
- Santos ALQ, Brito FMM, Bosso ACS, Vieira LG, Silva Junior LM, Kaminishi APS, Silva JMM, Pinto JGS, Moura MS and Rosa MA 2007. Anatomical Behavior of the Celiacomesenteric Artery of Pirarucu *Arapaima gigas* Cuvier, 1817 (Osteoglossiforme, Arapaimidae). *Int. J Morphol*. 25: 683-687.
- Shively MJ and Stump JE 1975. The systemic arterial pattern of the guinea pig: the abdomen. *Anat Rec*. 182: 355-366.
- Schmidt DP and Schoenau LSF 2007. Origin of the celiac and cranial mesenteric arteries by common trunk in a dog. *Ciencia Rural*. 37: 408-411.
- Wang GD, Zhai W, Yang HC, Wang L, Zhong L, Liu YH, Fan RX, Yin TT, Zhu CL, Poyarkov, AD, Irwin DM, Hytönen MK, Lohi H, Wu CI, Savolainen P and Zhang YP 2016. Out of southern East Asia: the natural history of domestic dogs across the world. *Cell Res*. 26: 21-33.
- Yi SQ, Terayama H, Naito M, Hayashi S, Moriyama H, Tsuchida A and Itoh MA 2007. Common celiacomesenteric trunk, and a brief review of the literature. *Ann Anat*. 189: 482-488.