

9-1-2019

The expression of serum lactate dehydrogenase in canine oral tumors

Nan Choisunirachon

Urapa Klansnoh

Panrawee Phoomvuthisarn

Sirinun Pisamai

Chutimon Thanaboonnipat

See next page for additional authors

Follow this and additional works at: <https://digital.car.chula.ac.th/tjvm>



Part of the [Veterinary Medicine Commons](#)

Recommended Citation

Choisunirachon, Nan; Klansnoh, Urapa; Phoomvuthisarn, Panrawee; Pisamai, Sirinun; Thanaboonnipat, Chutimon; and Rungsipipat, Anudep (2019) "The expression of serum lactate dehydrogenase in canine oral tumors," *The Thai Journal of Veterinary Medicine*: Vol. 49: Iss. 3, Article 11.

Available at: <https://digital.car.chula.ac.th/tjvm/vol49/iss3/11>

This Article is brought to you for free and open access by the Chulalongkorn Journal Online (CUJO) at Chula Digital Collections. It has been accepted for inclusion in The Thai Journal of Veterinary Medicine by an authorized editor of Chula Digital Collections. For more information, please contact ChulaDC@car.chula.ac.th.

The expression of serum lactate dehydrogenase in canine oral tumors

Authors

Nan Choisunirachon, Urapa Klansnoh, Panrawee Phoomvuthisarn, Sirinun Pisamai, Chutimon Thanaboonnipat, and Anudep Rungsipipat

The expression of serum lactate dehydrogenase in canine oral tumors

Nan Choisunirachon^{1*} Urapa Klansnoh¹ Panrawee Phoomvuthisarn¹

Sirinun Pisamai¹ Chutimon Thanaboonnipat¹ Anudep Rungsipipat²

Abstract

Lactate dehydrogenase (LDH) has been reported to be a prognostic indicator of human malignant melanoma (MM), lymphoma, renal cell carcinoma and prostate cancer. In veterinary medicine, elevation of serum LDH has been reported in canine lymphoma and mammary gland tumors. However, the expression of the LDH in oral tumor-bearing dogs has not been elucidated. In this study, serum LDH levels were evaluated and compared between healthy dogs (control; n = 20) and oral tumor-bearing dogs (n = 34). Half of the tumor-bearing dogs (17 dogs) had oral MM, followed by 6 dogs with oral squamous cell carcinoma (SCC), 4 dogs with fibrosarcoma (FS), 3 dogs with benign epithelial tumors (BET), and 1 dog each with osteosarcoma, lymphoma, histiocytoma and acanthomatous ameloblastoma. Serum LDH was significantly higher in oral tumor-bearing dogs ($P = 0.0006$). Besides, serum LDH expression of MM, SCC and FS was significantly higher than that of the control group ($P = 0.0078, 0.0030$ and 0.0022 , respectively). The expression of serum LDH did not significantly correlate with the location of the primary tumor or the clinical stage of the disease, the clinical stage II revealed the highest expression of the LDH though. The results indicate that serum LDH might be useful as an indicator for oral tumors but further study examining a larger number of patients with each tumor type would be advantageous.

Keywords: dog, lactate dehydrogenase, oral tumor, serum

¹Department of Veterinary Surgery, Faculty of Veterinary Science, Chulalongkorn University, Bangkok, Thailand, 10330

²Department of Pathology, Faculty of Veterinary Science, Chulalongkorn University, Bangkok, Thailand, 10330

*Correspondence: nan.c@chula.ac.th (N. Choisunirachon)

Introduction

In normal metabolism, cells obtain energy through oxidative phosphorylation, in which pyruvate enters the mitochondrial tricarboxylic acid cycle prior to complete oxidation. In situations of reduced oxygen availability, however, aerobic glycolysis is replaced to some degree by anaerobic glycolysis, in which glucose is converted into lactate (Gao and Chen, 2015). To make the lactate usable as an energy source, lactate dehydrogenase (LDH) catalyses the conversion of lactate to pyruvate concomitant with the NAD⁺ to NADH interconversion. In addition to hypoxic conditions, this LDH-catalysed conversion also occurs at elevated levels in several diseases. Serum LDH has been found to be a sensitive indicator of diseases involving the heart, liver, lungs, and muscles (Draoui and Feron, 2011).

Due to their high energy needs (to fuel growth, including local invasion and metastasis), tumor cells are often modified to use anaerobic glycolysis rather than mitochondrial oxidative phosphorylation (Doherty and Cleveland, 2013). Even in a normoxic condition, high-metabolism cells such as those in tumors obtain energy through glycolysis, especially in deeper tumors with less neovascularization (Sonveaux *et al.*, 2008). This phenomenon has been named the "Warburg effect". LDH, therefore, plays a crucial role in tumor metabolism, by interconversion of lactate and pyruvate, after which the lactate may be transported into the tumor cells for use as a source of energy (Draoui and Feron, 2011). The expression of LDH is thus a signature of the high metabolism of a malignant tumor, making LDH an interesting candidate for a prognostic indicator. In human medicine, LDH has been applied as a biomarker for several types of tumors, including lymphomas, prostate cancer, renal cell carcinomas, and malignant melanomas (MM) (Miao *et al.*, 2013).

In veterinary medicine, among canine tumors, oral masses account for 5–7% (Kafka *et al.*, 2004), which is a high incidence compared to other species (Dorn and Priester, 1976). Oral neoplasms can be found at sites such as the mucosa, gingiva, palate, or tongue (Vos and Gaag, 1987). The primary location of an oral tumor is strongly related to its clinical signs. Primary tumors can cause facial deformity, gagging, difficulty in mastication, or drooling. In advanced cases, primary oral masses can invade adjacent areas such as the retrobulbar region, causing exophthalmos, or the nasal cavity, causing epistaxis (Liptak and Withrow, 2007).

To enable proper treatment planning, including the prognosis of each tumor-bearing patient, the type of oral neoplasm should be clarified. In general, oral neoplasms can be divided into two groups, benign tumors such as epulis, and malignancies. The malignant oral tumors seen in canine patients include MM, squamous cell carcinoma (SCC), fibrosarcoma (FS), osteosarcoma, mast cell tumors, haemangiosarcoma, lymphoma, plasma cell tumors, and multilobular tumors of bone (Todoroff and Broodey, 1979). In addition to the cytological or histopathological results, other methods, such as examination of abnormal cancer-related biological substances found in body fluids such as blood or urine,

provide relatively simple methods for evaluating prognosis. Although previous reports have indicated that LDH could be used as a predictor of recurrence in canine lymphoma (Marconato *et al.*, 2010) and metastatic mammary gland tumors (Campos *et al.* 2012), the evaluation of LDH expression in oral cancer-bearing dogs has not been attempted. Therefore, the purpose of this study was to preliminary compare the serum LDH levels among canine patients with oral tumors, and those of healthy dogs.

Materials and Methods

This study was approved by the Institutional Animal Care and Use Committee (IACUC), Chulalongkorn University, in accordance with university regulations and policies governing the care and use of laboratory animals, and consent was obtained from the dog owners. The animal use protocol number was 1531017.

The canine patients used in this study were divided into 2 groups. The healthy control group (control) consisted of dogs that presented for an annual health check-up, or for castration or ovariohysterectomy. The primary subjects consisted of a group of oral tumor-bearing dogs. In both groups, the patients were examined using a full set of standard tests, such as a physical examination, complete blood count, serum biochemistry, thoracic and abdominal radiography (for the controls), and radiography with abdominal ultrasonography or whole body computed tomography (for the tumor-bearing group). Patients that had any disease involving the liver, heart, or muscles, or any other disease that could interfere with the serum LDH level, were excluded from this study.

In the tumor group, the dogs were examined and all relevant information about their oral masses was recorded, including location; size; shape; invasion of adjacent tissue; metastatic status; observations made through diagnostic imaging such as radiography, ultrasonography or computed tomography; and histopathological results after excisional biopsy. The clinical stage for each dog was classified according to the tumor size as follows: clinical stage I if the primary tumor was less than 2 cm in diameter, clinical stage II if the primary tumor size was between 2 and 4 cm, and clinical stage III if the primary tumor size was greater than 4 cm. If any patient had an oral tumor of any size with bone invasion or metastasis, either at a regional lymph node or a distant location, the dog was classified as clinical stage IV (Liptak and Withrow, 2007).

To investigate the serum LDH level in each patient, blood samples were collected from the cephalic vein with an awareness of hemolysis, placed in a plain tube and left at room temperature for 30 min before separating the serum by centrifugation. For the tumor group, the blood was collected prior to anaesthesia on the day of the excisional surgery and some at one day post-operatively. All serum samples were kept at -20 °C and submitted within 36 hours to the laboratory for LDH level measurement by the ultraviolet kinetic method with Daisy solution (Daisy, Germany) using a blood chemistry analyzer (Sapphire 400, Durai, China). The survival period for each dog was obtained via a telephone interview.

The clinical demographic data including serum LDH expression was presented as a descriptive analysis including the mean and SEM. The difference of serum LDH levels between the control group and the tumor group, or between the control group and each tumor type was analysed using the Mann-Whitney U test. Besides, the difference of serum LDH among tumor group in location and clinical stage were analysed using the Kruskal-Wallis test. All statistical analysis was performed using GraphPad Prism Version 7.0 (GraphPad Software, San Diego, CA, USA). *P* values less than 0.05 were considered statistically significant.

Results

Clinical demographic data: Among the 20 dogs in the control group, 10 were male (all neutered) and 10 were female (8 intact and 2 spayed). The average age was 3.5 ± 0.1 years old. The average body weight was 9.4 ± 1.7 kg. There were 7 mixed breed dogs, 2 poodles, 2 Shih Tzu, 1 German Shepherd, 1 Chow Chow, 1 Thai, 1 Beagle, 1 Boston terrier, 1 Pekinese, 1 Terrier, 1 Pomeranian, and 1 Chihuahua. Of the 34 dogs in the tumor group, 23 were male (16 intact and 7 castrated) and 11 were female (8 intact and 3 spayed). The average age was 9.4 ± 7.1 years old. The average body weight was 14.5 ± 1.89 kg. There were 14 mixed breed dogs, 7 Shih tzu, 5 Poodles, 3 Golden Retriever, 1 German Shepherd, 1 Rottweiler, 1 Siberian husky, 1 Bangkaew, 1 Pomeranian and 1 Pug.

The clinical information for the tumor group is as follows: Among 34 patients, there were 17 dogs with MM, 6 with SCC, 4 with FS, 3 dogs with benign

epithelial tumors (BET), and 1 each with osteosarcoma, lymphoma, histiocytoma and acanthomatous ameloblastoma. The locations of the tumors were predominantly in the gingival area (25/34 dogs), followed by the lip (5/34 dogs), buccal mucosa (2/34), and each of the tonsils and hard palate (1/30 dogs). The clinical stages were stage I for 9 dogs, stage II for 7 dogs, stage III for 13 dogs, and stage IV for 5 dogs. Among the 5 dogs in clinical stage IV, 3 dogs were finally diagnosed with MM with splenic (1 dog) or pulmonary (2 dog) metastases, a dogs affected with FS with pulmonary metastasis and the last dog had osteosarcoma with pulmonary metastasis.

Serum LDH expression: The average serum LDH for the control group was 102.43 ± 16.89 U/l, whereas the average for the tumor group was 378.35 ± 84.24 U/l, which was significantly higher ($P = 0.0006$, Fig. 1). Consideration with out individual patient, SCC revealed the highest serum LDH expression (478.43 ± 240.43 U/l) following by MM (397.29 ± 136.37 U/l), FS (265.85 ± 45.83 U/l) and BET (94.35 ± 64.35 U/l) which SCC, MM and FS had significantly higher serum LDH expression than that of control group ($P = 0.0030$, 0.0078 and 0.0022 , respectively; table.1 and Fig. 2).

In addition, the expression of serum LDH did not significantly correlate with the location of the primary tumor or the clinical stage of the disease (Fig. 3). Clinical stage II affected dogs (733.38 ± 341.75 U/l) had a higher expression of serum LDH followed by clinical stage III (329.26 ± 72.76 U/l), clinical stage IV (315.10 ± 212.06 U/l) and clinical stage I (208.26 ± 43.89 U/l), respectively ($P = 0.4239$; Table. 2).

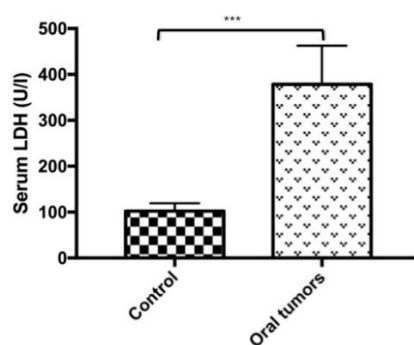


Figure 1 The serum lactate dehydrogenase (LDH) expression between the control dog (control) and the oral tumor-bearing dogs (oral tumors). The serum LDH was significantly higher in the oral tumor gr. than in that of the control gr. ($P = 0.0006$).

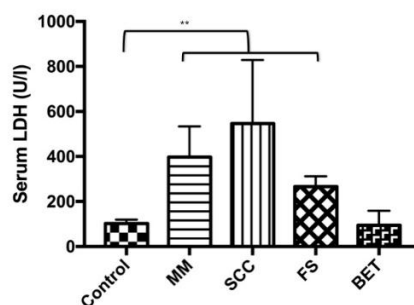


Figure 2 The serum lactate dehydrogenase (LDH) expression in control dogs (control) compared to those of oral malignant melanoma (MM), squamous cell carcinoma (SCC), fibrosarcoma (FS) and benign epithelial tumor (BET). The serum LDH expressions of MM, SCC and FS were significantly higher than that of the normal control dogs ($P = 0.0078$, 0.0030 and 0.0022 , respectively).

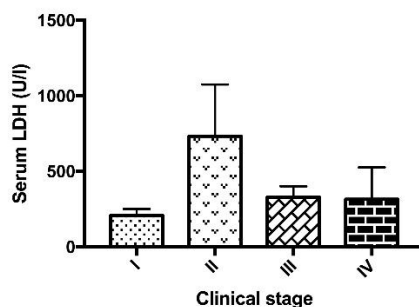


Figure 3 The serum lactate dehydrogenase (LDH) expression among 34 canine oral tumors considered by each group of clinical stages. No statistically significant difference of serum LDH expression among groups.

Table 1 The serum lactate dehydrogenase level (mean ± SEM) among normal control dogs and various canine oral tumor affected dogs

Classified group	Number	Serum LDH level (U/l)
Normal control dogs	20	102.43 ± 16.89
Oral tumor affected dogs	34	378.35 ± 84.24 ^b
Malignant melanoma	10	397.29 ± 136.37 ^a
Squamous cell carcinoma	3	478.43 ± 240.43 ^a
Fibrosarcoma	4	265.85 ± 45.83 ^a
Benign epithelia tumor	3	94.35 ± 64.35
Osteosarcoma	1	1156.00
Lymphoma	1	39.50
Histiocytoma	1	205.00
Acanthomatous ameloblastoma	1	491.90

^a and ^b Significant difference at $p < 0.01$ and 0.001 compared to the normal control group, respectively.

Table 2 The serum lactate dehydrogenase level (mean ± SEM) among various clinical stages of canine oral tumor affected dogs.

Classified group	Number	Serum LDH level (U/l)
Oral tumor affected dogs	34	378.35 ± 84.24
Stage I	9	208.26 ± 43.89
Stage II	7	733.38 ± 341.75
Stage III	13	329.26 ± 72.76
Stage IV	5	315.10 ± 212.06

Discussion

To treat tumors, several processes involving tumor pathophysiology and tumor metabolism have been investigated, both in human and in veterinary medicine. Among these processes, the production of lactate dehydrogenases (LDH), a family of NAD⁺-NADH conversion enzymes that contribute to the cancer-related increase in glycolysis known as the "Warburg effect", are considered to be reliable indicators of several types of human cancer, including malignant melanoma, lymphoma, renal cell carcinoma, and prostate cancer (Miao *et al.*, 2013). The increased LDH is probably a consequence of the fact that tumors have high-energy requirements for utilization of lactate, to fuel their rapid growth (Gao and Chen, 2015).

In canine cancer patients, LDH levels have been reported to be higher than in healthy dogs and dogs without tumors. Among malignancies, LDH expression was highest in lymphoma, histiocytic sarcoma, sarcoma, carcinoma, and mastocytoma, in that order (Marconato *et al.*, 2009). As a result, which matches the findings in human medicine, LDH is an attractive candidate for a predictor of tumor recurrence in canine lymphoma patients (Marconato *et al.*, 2010). In addition, LDH analysis can be applied to evaluate the metastatic status of canine malignant mammary gland tumors (Campos *et al.*, 2012).

The use of serum LDH for canine oral tumors has been reported for a small number of canine patients, which included only 3 dogs with tonsillar carcinoma, 2 with oral FS, and 1 dog each with oral SCC and oral MM (Marconato *et al.*, 2009). Therefore, our study aimed to preliminarily compare serum LDH levels in canine oral-tumor bearing patients and in healthy dogs.

In this study, the ages of the healthy dogs and the oral tumor bearing dogs were different because a higher incidence of the oral neoplasia was found in senile patients. In addition to neoplastic conditions, geriatric patients are prone to several aging maladies that can interfere with the serum LDH level such as heart or liver diseases (Draoui and Feron, 2011). Evaluation of serum LDH as the neoplastic indicator is of more benefit in the young to middle age patients since their health statuses are not concurrent with other LDH interference conditions. Nevertheless, the patient selection in this study attempted to eliminate the interference LDH from other sources through all of the blood work, imaging diagnosis and sample collection procedure. Therefore, the significantly higher serum LDH level in oral tumor affected dogs would come from the intra-oral tumor origin.

The serum LDH was significantly elevated in the oral tumor group compared to those of the control group, however the distribution of serum LDH level in the oral tumor group revealed a wide range. The

variation of the LDH level in the oral tumor group might be due to the composition of serum LDH from both of benign and malignant oral tumor. Although 34 canine oral tumor patients were enrolled, the distribution of various tumor types, including the primary location and clinical stage, resulted in a low number of dogs in each subcategory, which made it difficult to observe statistical differences in LDH levels in some rare types of oral tumor. When comparing the serum LDH level of each tumor to that of the control healthy group, MM which previous study in human medicine had proposed serum LDH as being a useful indicator of staging and prognosis (Bartlett and Karakousis, 2015) revealed significantly higher LDH levels compared to that of the control group. Although, in this study, half of the patients (17/34 dogs) had MM, which is consistent with previous reports that MM shows the highest incidence among canine oral tumors (Niemic, 2008). However, the variation of tumor location and stage of canine oral MM in this study would effect the distribution of LDH level. Since LDH has been applied as the prognostic indicator in various tumor treatment that involve the tumor metabolism such as anti-angiogenesis (Gray *et al.*, 2014) or radiation therapy (Wang *et al.*, 2016), a further study of serum LDH level in a large population with various tumor stages comparing with tumor angiogenesis factor such as vascular endothelial growth factor (VEGF) expression (Kim *et al.*, 2014) could produce valuable information for the evaluation of tumor malignancy and the optimization of the treatment protocol selection.

Interestingly, in malignant tumors, the serum LDH level of the SCC affected dogs was significantly higher than that of the control dogs. In human medicine, it has been reported that LDH level was revealed as the biochemical assessment in SCC (Pereira *et al.*, 2015; Sun *et al.*, 2015). Higher expression of LDH in SCC than those of MM and FS in our study might be due to the individual tumor cell metabolism. In contrast to malignant tumors, benign tumors such as the acanthomatous ameloblastoma revealed high level of the LDH. Although acanthomatous ameloblastoma is a benign oral tumor its characteristic is local invasiveness. Therefore, the local invasion might cause adjacent tissue damage related to LDH expression (Nie *et al.*, 2011).

Due to the limitation by low numbers of each tumor type in the oral tumor group, further prospective study of serum LDH in canine oral tumors, especially MM, SCC, FS and acanthomatous ameloblastoma with a larger number of patients, compared with other oxygenation parameters such as tumor angiogenesis or contrast enhanced imaging diagnosis including treatments, for example anti-angiogenesis or radiotherapy protocols, could show interesting information.

Conflict of interest: There is no conflict of interest on this study.

Acknowledgements

This research was supported by The Grants for Development of New Faculty Staff,

Rachadaphiseksomphot Endowment Fund, and The Research Assistant Scholarships, Graduate School, Chulalongkorn University. Authors would like to thank all supports from Suwannachard Animal Hospital for the research technique.

References

- Bartlett EK and Karakousis GC 2015. Current staging and prognostic factor in melanoma. *Surg Oncol Clin N Am.* 24: 215 - 227.
- Campos LC, Lavallo GE, Estrela-Lima A, Melgaco de Faria JC, Guimaraes JE, Dutra AP, Ferreira E, de Sousa LP, Rabelo EML, Vieira da Costa, AFD and Cassali GD 2012. CA 15.3, CEA, and LDH in dogs with malignant mammary tumors. *J Vet Intern Med.* 26: 1383 - 1388.
- Doherty JR and Cleveland JL 2013. Targeting lactate metabolism for cancer therapeutics. *J Clin Invest.* 123: 3685 - 3692.
- Dorn CR and Priester WA 1976. Epidemiologic analysis of oral and pharyngeal cancer in dogs, cats, horses, and cattle. *J Am Vet Med Assoc.* 169: 1202 - 1206.
- Draoui N and Feron O 2011. Lactate shuttles at a glance: from physiological paradigms to anti-cancer treatments. *Dis Model Mech.* 4: 727 - 732.
- Gao JJ and Chen YG 2015. Natural compounds regulate glycolysis in hypoxic tumor microenvironment. *Biomed Res Int:* 2015: 354143.
- Gray MR, del Campo SM, Zhang X, Zhang H, Souza FF, Carson WE and Smith AD 2014. Metastatic melanoma: lactate dehydrogenase levels and CT imaging findings of tumor devascularization allow accurate prediction of survival in patients treated with Bevacizumab. *Radiology.* 270: 425 - 434.
- Kafka UC, Carstens A, Steenkamp G and Symington H 2004. Diagnostic value of magnetic resonance imaging and computed tomography for oral masses in dogs. *J S Afr Vet Assoc.* 75: 163 - 168.
- Kim HS, Lee HE, Yang HK and Kim WH 2014. High lactate dehydrogenase 5 expression correlates with high tumoral and stromal vascular endothelial growth factor expression in gastric cancer. *Pathobiology.* 81: 78 - 85.
- Liptak JM and Withrow SJ 2007. Cancer of the Gastrointestinal Tract. In: Withrow & MacEwan's Small Animal Clinical Oncology 4th ed DM Vail (ed) Saint Louis: W.B. Saunders 455 - 510.
- Marconato L, Crispino G, Finotello R, Mazzotti S, Salerni F and Zini E 2009. Serum lactate dehydrogenase activity in canine malignancies. *Vet Comp Oncol.* 7: 236 - 243.
- Marconato L, Crispino G, Finotello R, Mazzotti S and Zini E 2010. Clinical relevance of serial determinations of lactate dehydrogenase activity used to predict recurrence in dogs with lymphoma. *J Am Vet Med Assoc.* 236: 969 - 974.
- Miao P, Sheng S, Sun X, Liu J and Huang G 2013. Lactate dehydrogenase A in cancer: a promising target for diagnosis and therapy. *IUBMB Life.* 65: 904 - 910.
- Nie J, Tong TK, George K, Fu FH, Lin H and Shi Q 2011. Resting and post exercise serum biomarkers of

- cardiac and skeletal muscle damage in adolescent runners. *Scand J Med Sci Sport*. 21: 625 – 629.
- Niemiec BA 2008. Oral pathology. *Top in Companion Anim Med*. 23: 59 – 71.
- Pereira T, Shetty S and Pereira S 2015. Estimation of serum lactate dehydrogenase level in patients with oral premalignant lesions/ conditions and oral squamous cell carcinoma: A clinicopathological study. *J Cancer Res Ther*. 11 78 – 82.
- Sonveaux P, Vegran F, Schroeder T, Wergin MC, Verrax J, Rabbani ZN, De Saedeleer CJ, Kennedy KM, Diepart C, Jordan BF, Kelley MJ, Gallez B, Wahl ML, Feron O and Dewhirst MW .1995 Targeting lactate-fueled respiration selectively kills hypoxic tumor cells in mice. *J Clin Invest*. 118: 3930 – 3942.
- Sun W, Zhang X, Ding X, Li H, Gen M, Xie Z, Wu H and Huang M 2015. Lactate dehydrogenase B is associated with the response to neoadjuvant chemotherapy in oral squamous cell carcinoma. *PLOS ONE*. DOI: 10.1371/journal.pone.0125976.
- Todoroff RJ and Brodey RS 1979. Oral and pharyngeal neoplasia in the dog: a retrospective survey of 361 cases. *J Am Vet Med Assoc*. 175: 567 – 571.
- Vos JH and van der Gaag I 1987. Canine and Feline oral-pharyngeal tumours. *J Vet Med Series A*. 34: 420 – 427.
- Wang J, Li L, Dong B, Xu Y, Zheng Y, Sun Z, Yang Y, Chen Y, Chen X and Chen M 2016. Post-treatment serum lactic dehydrogenase as a predictive indicator for distant metastasis and survival of patients with nasopharyngeal carcinoma. *Oncotarget*. 7: 27485 – 27467.