

3-1-2018

ECG Quiz

Chollada Buranakarl

Saikaew Sutayatram

Chutamas Benjanirut

Piyasiri Glangosol

Follow this and additional works at: <https://digital.car.chula.ac.th/tjvm>



Part of the [Veterinary Medicine Commons](#)

Recommended Citation

Buranakarl, Chollada; Sutayatram, Saikaew; Benjanirut, Chutamas; and Glangosol, Piyasiri (2018) "ECG Quiz," *The Thai Journal of Veterinary Medicine*: Vol. 48: Iss. 1, Article 6.

Available at: <https://digital.car.chula.ac.th/tjvm/vol48/iss1/6>

This Other is brought to you for free and open access by the Chulalongkorn Journal Online (CUJO) at Chula Digital Collections. It has been accepted for inclusion in The Thai Journal of Veterinary Medicine by an authorized editor of Chula Digital Collections. For more information, please contact ChulaDC@car.chula.ac.th.

ECG Quiz

Chollada Buranakarl^{1*} Saikaew Sutayatram¹ Chutamas Benjanirut¹ Piyasiri Glangosol²

History

A 3-year-old female domestic shorthair cat was taken to the Small Animal Teaching Hospital, Chulalongkorn University, on March 6th, 2018 with the symptom of sudden inability to use her back legs the day before. The cat was raised outdoor with no clear history of vaccination. Physical exam showed low body temperature of 98 °F, depressed, tachypnea, mild dyspnea, increased lung sound, and no femoral pulse with cold rear limbs. Both front limb systolic blood pressures were approximately 70 mmHg.

Blood profile indicated hyperglycemia (blood glucose 183 mg%), thrombocytopenia, and high SGPT. No blood parasites were found from witness snap test. Blood gas analysis was unremarkable.

Radiographic findings showed cardiomegaly (VHS 8.7) with enlarged left atrium and ventricle. Small amount of pleural fluid was found in left thorax

with mild interstitial peribronchial infiltration of right lung and left caudal lobe. Mild ascites was also detected.

Aortic thromboembolism (ATE) was suspected. The cat was treated with antibiotic, pain killer, positive inotrope and anti-platelet aggregating drug.

On the second day the cat was more depressed and developed anorexia. Further cardiovascular examination including echocardiography and electrocardiogram (ECG) were performed. The ECG was recorded and presented in figure 1. The echocardiography indicated bilateral atrial enlargement. Fibrous band in both ventricles, tricuspid and mitral regurgitation, with spontaneous echo contrast (SEC) in the left heart were seen. Both systolic and diastolic dysfunction were seen. Thus, restrictive cardiomyopathy (RCM) was suspected. Unfortunately, the cat died on the next day.

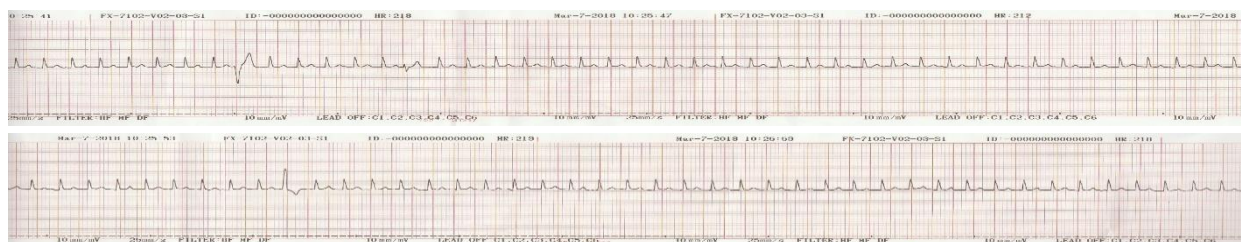


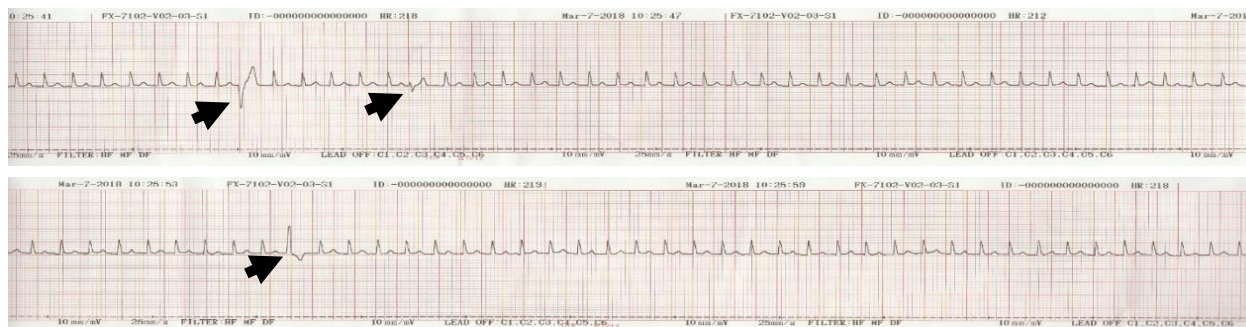
Figure 1 Two consecutive ECG tracing recorded from a cat that was diagnosed of restrictive cardiomyopathy.

Please answer before turning to the next page.

¹Department of Veterinary Physiology, ²Small Animal Teaching Hospital, Faculty of Veterinary Science, Chulalongkorn University

Interpretation

Figure 1 - Sinus rhythm with multiple ventricular premature complexes



These two consecutive ECG tracing showed that the basic rhythm was sinus in origin. The heart rate was approximately 210 beats per minute (bpm). Since the ECG waveforms in cat is much smaller than in dog, thus the P-wave may be invisible. Additionally, pleural effusion may interfere with electrical conduction. The normal heart rate in cats is 180 to 220 bpm. Young cat has higher heart rate than adult. Three abnormal bizarre waveforms were seen in tracing (arrows). All waveforms were suspected to originate from ventricular in origin. The abnormal shape indicates that the impulse did not conduct through His Bundle. These ectopic waveforms occurred without disruption of normal sinus complexes since they occurred as the interpolation beats. No pulse deficit was found. Thus, ectopic beats may not interfere the normal sinus beats. The second ectopic beat may also be a fusion beat in which the impulses originated from the sinus and ventricular origins were combined. Thus, the shape is in between these two.

In cats, ECG could be changed as a results of cardiac disease related to cardiac myocardium itself such as cardiomyopathy. However, other disease that may change the ECG basic waveforms including hyperthyroidism, electrolyte abnormality or hypertension. Cats with cardiomyopathy has clinical signs of exercise intolerance. Opened moth breathing, high respiratory rate and coughing may also be seen. At the final term, the congestive signs such as pulmonary edema, pleural or pericardial effusion and ascites are common. One important finding in cat is a presence of arterial thromboembolism (ATE) due to clot formation that usually obstruct the rear legs leading to paresis and hind limb necrosis. Physical

examination will reveal the pulse deficit and cyanosis with cold skin on that leg.

The common cardiomyopathies in cats are hypertrophic, restrictive and dilated cardiomyopathy. The type of cardiomyopathy are routinely differentiate using echocardiography. In cardiomyopathy with dilated ventricles, the tall R-wave (>0.9 mV) or prolonged QT interval (>0.045 seconds) may be encountered. However, this cat has R wave height only 0.5 mV with QT interval of 0.20 seconds which fell within normal ranges corresponding to non-dilated ventricular chamber on echocardiography. No axis deviation in lead II was found. By rhythm analysis, none of atrioventricular block was seen. Nowadays, the dilate cardiomyopathy causing by taurine deficiency is rare since the taurine is supplemented in to the cats food. Genetic factor may also involve.

In hypertrophic cardiomyopathy heart is characterized with ventricular hypertrophy leading to obstruction of aortic outflow tract similar to aortic stenosis. This type of cardiomyopathy is genetic related especially in Persian and Maine Coon breeds.

Restrictive cardiomyopathy is another form of heart abnormality that the anatomic changes may be intermediate for dilated chamber and hypertrophic muscle. However, the disease is related to severe fibrosis of endocardium of subendocardium causing an impairment diastolic function. The heart has low compliant with stiffness. The causes of the disease may involve inflammation, ischemia or infarction of myocyte from infection or other causes leading to the severe fibrosis of cardiac myocyte. In this case, a non-specific arrhythmia was found which cannot be used as a diagnostic tool for cardiomyopathy.