

9-1-2017

Ophthalmology Snapshot

Nalinee Tuntivanich

Follow this and additional works at: <https://digital.car.chula.ac.th/tjvm>



Part of the [Veterinary Medicine Commons](#)

Recommended Citation

Tuntivanich, Nalinee (2017) "Ophthalmology Snapshot," *The Thai Journal of Veterinary Medicine*: Vol. 47: Iss. 3, Article 16.

Available at: <https://digital.car.chula.ac.th/tjvm/vol47/iss3/16>

This Other is brought to you for free and open access by the Chulalongkorn Journal Online (CUJO) at Chula Digital Collections. It has been accepted for inclusion in The Thai Journal of Veterinary Medicine by an authorized editor of Chula Digital Collections. For more information, please contact ChulaDC@car.chula.ac.th.

Ophthalmology Snapshot

Nalinee Tuntivanich

History

An eleven-year-old, female Golden Retriever had presented to the Ophthalmology Clinic, Animal Teaching Hospital, Faculty of Veterinary Science, Chulalongkorn University with chronic dry eye and slight ocular blepharospasm. The dog had been

receiving artificial tear supplement for several years. However, blepharospasm remained with severe purulent ocular discharge. The owner concerned whether other prescriptions may be additionally considered to relief her ophthalmic discomfort.

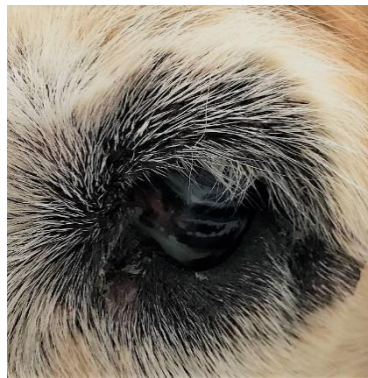


Figure 1 Eye of the Golden Retriever presenting change of skin color around eyelid margin and purulent ocular discharge.
(For better quality of photographs, please visit the TJVM website)

Question

What is the underlying cause of chronic ocular irritation besides of dry eye?

Please turn to next page for the answer.

Answer

Acquired trichiasis

Comments

Trichiasis is a condition that eyelashes or facial hairs grow inward to irritate ocular surface. Not only it causes dogs closing their eyelids involuntarily, epiphora, redness of the eye, keratitis and possibly corneal ulcer can consequently occur. Trichiasis can be diagnosed as congenital or acquired condition. Congenital trichiasis occurs in several dog breeds; such as brachycephalic breeds with obvious skin fold on their faces; Bull dog, Pugs, Pekinese, Cocker spaniel, Shih Tzu, etc. If acquired, trichiasis may appear in aging dogs with loosen eyelid tone resulting in drooping inward of eyelid. Dogs, such as Saint Bernard, Chows or Shar-pei, with large skin folds are prone to have this abnormality as compared to other breeds.

When trichiasis is diagnosed, thorough ophthalmic examinations are recommended to rule out

other concealed causes and their complications. Treatment should be considered to minimize ocular surface irritation. Any surgery, of which marginal part of eyelid is no longer turning inward, is usually preferable option for the treatment. However, surgery to correct trichiasis are somewhat complex, time consuming, unpredictable for optimum correction, and also possible of recurrence.

Reference

- Bowman RJC, 1999. Trichiasis Surgery. Community Eye health. 12(32): 53-54.
- LAUS JL, VICENTI FAM, BOLZAN AA AND GALERA PD, 2000. Stades method for surgical correction of upper eyelid trichiasis-entropion: results and follow-up in 21 cases. Ciencia Rural. 30(4): 651-654.
- Van Der Woerd A, 2004. Adnexal surgery in dogs and cats. Vet Ophthalmol. 7(5): 284-290.