

9-1-2017

Granulomatous Myocarditis in a Toco toucan (*Ramphastos toco albogularis*)

Yen-Li Huang

Shinn-Shyong Tsai

Omir Adrian Castaneda

Supochana Charoensin

Duangstuda Thongchan

See next page for additional authors

Follow this and additional works at: <https://digital.car.chula.ac.th/tjvm>



Part of the [Veterinary Medicine Commons](#)

Recommended Citation

Huang, Yen-Li; Tsai, Shinn-Shyong; Castaneda, Omir Adrian; Charoensin, Supochana; Thongchan, Duangstuda; and Wu, Hung-Yi (2017) "Granulomatous Myocarditis in a Toco toucan (*Ramphastos toco albogularis*)," *The Thai Journal of Veterinary Medicine*: Vol. 47: Iss. 3, Article 14.

Available at: <https://digital.car.chula.ac.th/tjvm/vol47/iss3/14>

This Report is brought to you for free and open access by the Chulalongkorn Journal Online (CUJO) at Chula Digital Collections. It has been accepted for inclusion in The Thai Journal of Veterinary Medicine by an authorized editor of Chula Digital Collections. For more information, please contact ChulaDC@car.chula.ac.th.

Granulomatous Myocarditis in a Toco toucan (*Ramphastos toco albogularis*)

Authors

Yen-Li Huang, Shinn-Shyong Tsai, Omir Adrian Castaneda, Supochana Charoensin, Duangsuda Thongchan, and Hung-Yi Wu

Granulomatous Myocarditis in a Toco toucan (*Ramphastos toco albogularis*)

Yen-Li Huang¹ Shinn-Shyong Tsai¹ Omir Adrian Castaneda² Supochana Charoensin³
Duangsuda Thongchan¹ Hung-Yi Wu^{1*}

Abstract

An uncommon lesion was diagnosed in a 1-year-old female toco toucan (*Ramphastos toco albogularis*) based on microscopic examinations. Necropsy, histopathology and molecular diagnosis were carried out. At necropsy, possible granulomatous myocarditis was diagnosed in the bird and was confirmed as shown by histopathology. Polymerase chain reaction (PCR) revealed an unspecific trematode species as the causative agent. Research on parasitic granulomatous myocarditis in toco toucan has been rarely reported. Therefore, it should be considered during differential diagnosis of avian granuloma cases.

Keywords: granulomatous myocarditis, pathology, parasite disease, *Ramphastos toco*, Taiwan

¹Department of Veterinary Medicine, College of Veterinary Medicine, National Pingtung University of Science and Technology, 1, Shuefu Road, Neipu, Pingtung, Taiwan

²Department of Food Science, College of Agriculture, National Pingtung University of Science and Technology, 1, Shuefu Road, Neipu, Pingtung, Taiwan

³Department of Tropical Agriculture and International Cooperation, College of Agriculture, National Pingtung University of Science and Technology, 1, Shuefu Road, Neipu, Pingtung, Taiwan

*Correspondence: wuhy@mail.npust.edu.tw

Introduction

Toucans (Piciformes, Ramphastidae) are native to South America and the Caribbean region. They generally live in tropical and sub-tropical regions (Patané et al., 2009), and are easily to become captive pet birds due to their attractive appearance. Toucans are not native of Taiwan, hence all toucans found in Taiwan are imported or bred from originally imported birds.

Bacterial (Yersiniosis, Chlamydiosis, Coxiella-like infection), mycotic (Aspergillosis, Candidiasis, *Penicillium* infection), viral (Newcastle disease, Pacheco's disease, Polyomavirus infection), and parasitic (cestode, nematode, trematode, protozoa) infections associated with severe inflammation have been documented as fatal disease in toucans (Pinto et al., 1996; Shin-Ichi et al., 2016; Shivaprasad et al., 2008).

Granulomatous myocarditis, associated with various inflammatory diseases, is a rare disorder of myocardium (Kanchan, 2010). Granulomatous myocarditis caused by bacterial infection, fungal infection, tumor, and gout has been reported (Akanbi, 2008; Dias and Montau, 1994; Schilliger, 2003; Schmidt, 2008). Parasite-caused granulomatous myocarditis is usually diagnosed as *Sarcocystis* (Martin et al., 2004; Prakas and Butkauskas, 2012), however trematode migration to heart, leading to granulomatous myocarditis, is rare in avian species, especially in toucans.

Parasites of toco toucan have not been well documented. This prompted us to investigate granulomatous cases of this entity. Despite the numerous species of parasites reported in birds, comparatively little is known about the prevalence and distribution of these parasites in toucans. Therefore, the current study reports the observation of granulomatous myocarditis in a parasite-infected toco toucan.

Case Description

Many species of pet birds were dead before submission, and histopathology was used to diagnose disease at the Animal Hospital of National Pingtung University of Science & Technology (NPUST), Pingtung, Taiwan. One of the pet birds, an adult, female toco toucan that experienced a sudden death, was sent to the NPUST Animal Hospital for diagnosis. According to the pet owner, no distinct clinical signs were observed prior to the bird's sudden death.

Necropsy with a systematic approach was carried out, and then the samples collected were examined for bacterial testing. Samples from heart and liver were taken using moist sterile swabs and plated on MacConkey's and blood agar plates, respectively. Both agars were incubated at 37°C for 24 hrs. Sections collected from the brain, heart, liver, spleen, lung, kidney, gastrointestinal tract, genitals, eyes, thyroid gland, adrenal gland, skin, and bone were fixed in 10% neutral-buffered formalin for at least 24 hrs. The formalin-fixed samples were microscopically examined after dehydration, paraffin embedding and sectioning at 2-3 µm. All sections were stained with haematoxylin and eosin (H&E).

Materials and Method of PCR

Polymerase chain reaction (PCR) was used for diagnosis of cestode and trematode parasites. It was conducted on DNA extracted from sections of the organs collected. These sections were extracted using EasyPure Genomic DNA Spin Kit (Biomax scientific Co., Ltd., Taipei, Taiwan) according to the manufacturer's instructions. The nucleotide and sequence positions of two pairs of forward and reverse primers, (5'-AATTCGTGCCAGCCATCGCGG-3'/5'-TTCCAGTACATTTACCTTGTACGAC-3') and (5'-TTAAGATATATGTGGTACA-GGATTAGATACCC-3'/5'-AACCGAGGGTGACGGGCGGTGTGTACC-3'), were designated according to a previous report (Von Nickisch-Rosenegk, et al., 1999) for cestodes. The trematode primers were designated as 3S (5'-GGTACCGGTGGATCACTCGGCTCGTG-3') and A28 (5'-GGGATCCTGGTTAGTTTCTTTTCTCCGC -3') according to Bowles et al. (1995). The PCR conditions were set according to Von Nickisch-Rosenegk et al. (1999): denaturing at 94°C for 1 min, annealing at 55°C for 2 min, and extension at 73°C for 2 min for 20 cycles; and Bowles et al. (1995): denaturing at 95°C for 30 s, annealing at 55°C for 45 s, and extension at 72°C for 1 min for 35 cycles.

Positive DNA fragments, which were identified by PCR and electrophoresis after picking up one white clone, were transformed into T&A-vector using the RBC rapid ligation kit (Biomax Scientific Co., Ltd., Taipei, Taiwan) and sent for sequencing (PURIGO Biotechnology Co., Ltd, Taiwan).

Results and Discussion

At necropsy, the heart of the bird exhibited multiple slightly elevated pale-yellow nodules and yellow firm plaques scattered on the heart surface. These nodules were visible as white to yellow 'rice grain' cylindrical lesions in cardiac muscles, with sizes up to 2 to 4 mm in length, 1 to 3 mm in diameter and 0.1 to 0.3 mm in height. The plaque lesion was measured up to 2 × 2.5 cm in size (Figure 1A). Although the worm caused heart disease, it is suspected that the site of origin was the gastrointestinal tract after the host ingested an infective stage parasite which penetrated the stomach wall, and eventually migrated to the heart. Other organ lesions included hemochromatosis in the spleen and liver, and minor lung congestion. However, there was no evidence suggesting that the lesions were caused by trematode.

Examination under light microscope revealed that cross sections of the parasite-infected heart had granulomatous myocarditis (Figure 1B). The lesions revealed a granuloma comprising a central area with a helminth-like structure surrounded by severe inflammatory cell infiltration. The heart lesions involved both the pericardium and the cardiac muscles, which were almost destroyed. The chronic active stages of the lesions found in the heart were represented by massive lymphocytic and mononuclear infiltration, as well as the formation of multinucleated giant cells (Figure 1C), leading to the severe destruction of the parenchyma. The cross sections of the parasite-infected heart showed that the body

structure of the helminth was simple acoelomate with the body wall consisting of the cuticle, subcuticular muscle cells and vitelline follicles in the spongy matrix. The section revealed that the outer covering of the helminth was a faint pink scale-like spiny cuticle with a single layer of cells. A high number of fat droplets were also seen scattered throughout the medullary and

cortical parenchyma (Figure 1D). Moreover, the absence of cestode characteristic calcareous corpuscles confirmed that this parasite was a trematode. Multifocal iron phagocytosis was detectable in the spleen and also discursively in the hepatocytes. The remaining organs had no remarkable changes.

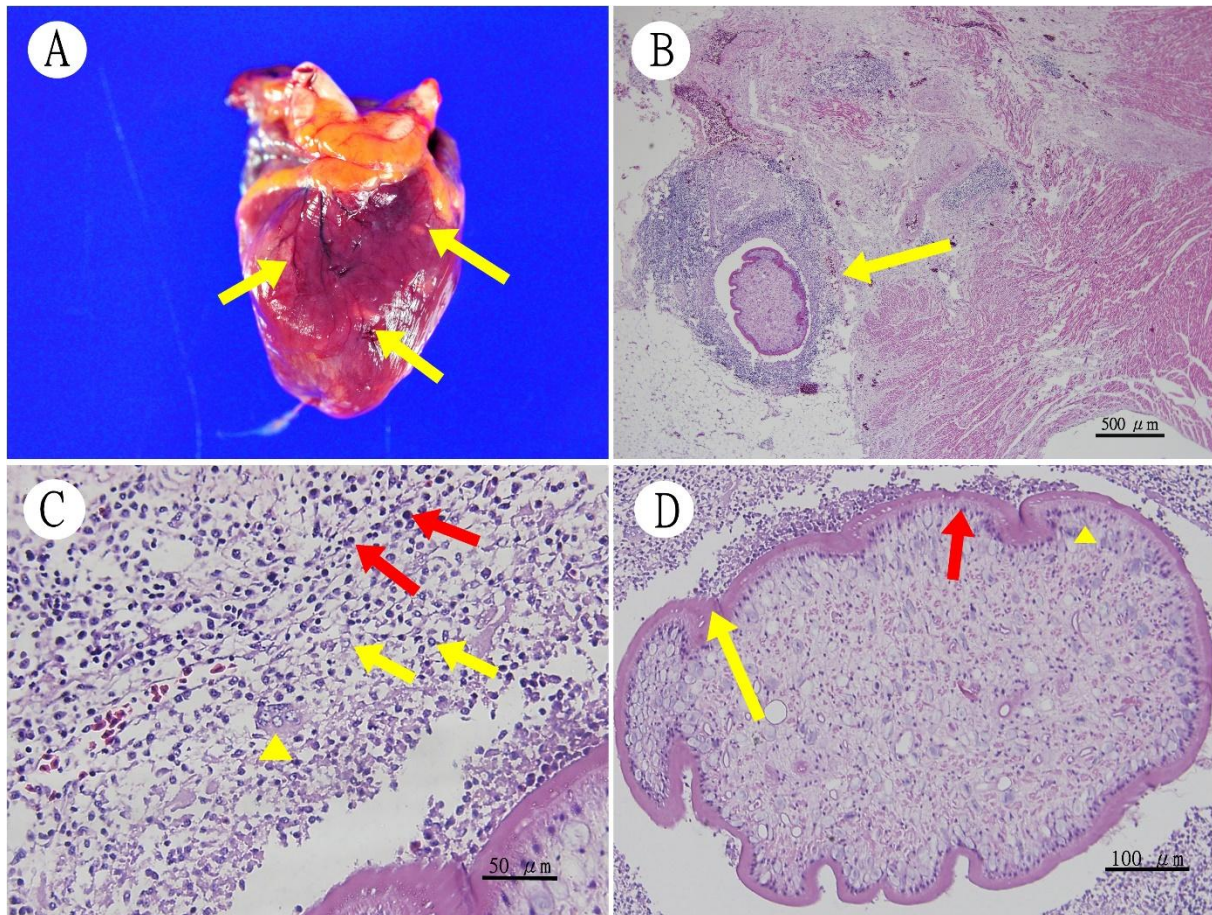


Figure 1 Granulomatous myocarditis with trematode in a toco toucan (*Ramphastos toco*) (A) Multiple pale-yellow nodules and plaques scattered on the heart surface. (B) The cross section of heart tissue infected with parasite (arrow) shows the formation of nodule (H&E, 100x). (C) Presence of a massive lymphocytic (red arrow), mononuclear (yellow arrow) and multinucleated giant cell (arrow head) infiltration in granulomatous inflammation (H&E, 400x). (D) Simple acoelomate body structure of helminth consisting of scale-like spiny cuticle (yellow arrow), a single layer of cells (red arrow) and fat droplets (arrow head) (H&E, 200x).

PCR results using both primer pairs from Von Nickisch-Roseneck et al. (1999) showed multiple bands as indicated in Lane 1 in Figure 2. Sequencing analysis of those bands revealed no compatibility with cestode sequences. Using Bowles et al. (1995) primers to check the trematode, results revealed a gene size of 494 bp as shown in Lane 2 (Figure 2). However, due to the lack of sufficient species-specific genetic database, the larval trematode sequence of the toco toucan obtained in this study could not be fully identified. Nonetheless, the morphological description of the larval parasite strongly suggested it as being a trematode, even though the specific species could not be identified due to lack of characteristic trematode mature structures. There are few published descriptions of granulomatous myocarditis in toco toucan associated with parasitism by trematode. The present study reports a case of granulomatous myocarditis in which parasite was evidenced as the underlying pathogen.

The most common causes of granulomatous inflammation include the infection of Gram-negative bacteria such as *Escherichia coli*, *Salmonella* sp., *Pseudomonas aeruginosa* (Klopfleisch et al., 2005) and Gram-positive bacteria like *Staphylococcus aureus* and *Listeria monocytogenes* (Akanbi et al., 2008). Gram-negative bacteria and Gram-positive bacteria are known to stimulate the formation of acute heterophilic granuloma in avian species that might develop into chronic granuloma with epithelioid cells, lymphocytes and connective tissue elements involved in various organs. In the heart, septic necrotizing myocarditis, vegetative valvular thromboendocarditis as well as granulomatous myocarditis are evident after inflammatory reactions due to bacterial infection (Montau, 1988; Supartika et al., 2006). In this study, based on the MacConkey's and blood agar inspections, bacterial colonies were not found. Hence, lesions of systemic infection with bacteraemia and septicemia

were also absent. These results rule out both the primary and secondary bacterial infection.

Fungal infection may also be associated with granulomatous inflammation. *Cryptococcus* spp., *Blastomyces* spp., *Aspergillus* spp. and *Pneumocystis* spp. cause non-necrotizing granulomatous inflammation with numerous multinucleated giant cells and scattered chronic inflammation (Davies, 1994). The fungal granuloma is always found to be surrounded by a thick fibrous capsule and comprise epithelioid cells, lymphocytes, plasma cells and numerous Langhans' type giant cells in birds when observed under light microscope. Most importantly, fungal granuloma is characterized by the presence of fungal hyphae with distinct structures (Walsh, 2008). In our toco toucan case, no fungal hyphae was observed during the histopathological examination.

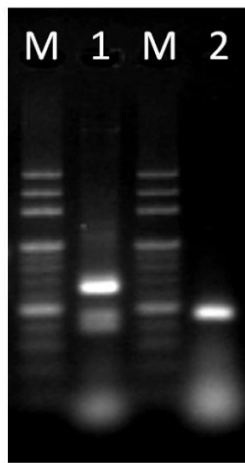


Figure 2 PCR analysis of parasites. Lane M: MWD100 molecular weight marker; Lane 1: multiple bands using Von Nickisch-Rosenegk et al. (1999) primers; Lane 2: 494bp band using Bowles et al. (1995) primers.

Visible gross lesions of the cardiovascular system have been reported in captive parrots, in which myocardial parasites were identified in some of the birds (Krautwald-Junghanns et al., 2004). Visceral helminthic larva migrans, heartworm, disseminated visceral coccidiosis, and *Schistosoma* egg involvement in myocardium may induce granulomatous inflammatory response (Kiyoshi et al., 2004). The helminthic larvae of tapeworm, flatworm, and roundworm incite a brisk lympho-histiocytic response within the myocardium, and myocardial damage may be visible in the early stages of illness characterized by infiltration of plasma cells and lymphocytes (Gemmell and Soulsby, 1968). Cystic structures containing *Sarcocystis* have also been observed within myocardial fibers leading to noncaseating granulomatous inflammation (Martin et al., 2004). Eosinophils may also be present within the inflammatory cell infiltrates in parasite infection (Feldman and McNamara, 2000). A response by the lymphatic and reticulo-endothelial systems following exposure to tapeworm fluid also gives rise to inflammation (Gemmell, 1968; Rakha, 1991), however the presence of parasite is necessary for better diagnosis.

Granulomatous myocarditis is associated with chronic inflammatory response due to persistence

and/or resistance of trematode migration. When acute inflammatory response fails, trematode continually induces the release of inflammatory mediators from indigenous parenchymal cells and T lymphocytes, leading to macrophage and giant cell infiltration and activation. Troglotrematidae, Diplostomidae, and Clinostomidae are strongly suggested trematode Families for differential diagnosis in this study due to their common occurrence in myocarditis. According to our test results, final diagnosis was established as a trematode infection leading to a severe multifocal granulomatous myocarditis. The trematode in our case study was actually visible within the nodule, with characteristic granulomatous inflammatory response.

Although bacterial and fungal infection analysis were negative based on microbiological culture and histopathological analysis, complete ruling out was not confirmed by PCR. Despite the unknown parasite species based on PCR sequencing, trematode larva infection in the toco toucan was suspected as the etiological agent based on the histological features. This case study strongly suggests that avian trematode larva should be considered as a possible pathogen during differential diagnosis for granulomatous myocarditis.

References

- Akanbi OB, Breithaupt A, Polster U, Alter T, Quandt A, Bracke A and Teifke JP 2008. Systemic listeriosis in caged canaries (*Serinus canarius*). Avian Pathol. 37(3): 329-332.
- Bowles J, Blair D and McManus DP 1995. A molecular phylogeny of the human schistosomes. Mol Phylogenet Evol. 4(2): 103-109.
- Davies SF 1994. Fungal pneumonia. Med Clin North Am. 78(5): 1049-1065.
- Dias JL and Montau RJ 1994. Staphylococcosis in captive exotic waterfowl. Avian Pathol. 23(4): 659-669.
- Feldman AM and McNamara D 2000. Myocarditis. N Engl J Med. 343(19): 1388-1398.
- Gemmell MA and Soulsby EJJ 1968. The development of acquired immunity to tapeworms and progress towards active immunization, with special reference to *Echinococcus* spp. Bull World Health Organ. 39(1): 45-55.
- Kanchan T, Nagesh KR, Lobo FD and Menezes RG 2010. Tubercular granuloma in the myocardium: an autopsy report. Singap Med J. 51(1): 15-17.
- Kiyoshi M, Kaoru H, Hiroshi K, Shinichi E, Toshimasa M, Naokki H, Teruhiko I and Yuya Y 2004. A case of parasitic granuloma and inflammatory fibroid polyp of the stomach. J Nara Med Assoc. 55: 323-330.
- Klopfleisch R, Müller C, Polster U, Hildebrandt JP and Teifke JP 2005. Granulomatous inflammation of salt glands in ducklings (*Anas platyrhynchos*) associated with intralesional Gram-negative bacteria. Avian Pathol. 34(3): 233-237.
- Krautwald-Junghanns ME, Braun S, Pees M, Straub J and Valerius HP 2004. Research on the anatomy and pathology of the psittacine heart. J Avian Med Surg. 18(1): 2-11.

- Martin WJ 2nd, Iannuzzi MC, Gail DB and Peavy HH 2004. Future directions in sarcoidosis research: summary of an NHLBI working group. *Am J Respir Crit Care Med.* 170(5): 567-571.
- Montau RJ 1988. Comparative pathology of inflammation in the higher vertebrates (reptiles, birds and mammals). *J Comp Pathol.* 99(1): 1-26.
- Patané JSL, Weckstein JD, Aleixo A and Bates JM 2009. Evolutionary history of *Ramphastos toucans*: Molecular phylogenetics, temporal diversification, and biogeography. *Mol Phylogenet Evol.* 53(3): 923-934.
- Pinto RM, Vicente JJ and Noronha D 1996. Nematode Parasites of Brazilian Piciformes Birds: a General Survey with Description of *Procyrnea anteroovulvata* n. sp. (Habronematoidea, Habronematidae). *Mem Inst Oswaldo Cruz, Rio de Janeiro.* 91(4): 479-487.
- Prakas P and Butkauskas D 2012. Protozoan parasites from genus *Sarcocystis* and their investigations in Lithuania. *Ekologija.* 58(1): 45-58.
- Rakha NK, Dixon JB, Jenkins P, Carter SD, Skerritt GC and Marshall-Clarke S 1991. Modification of cellular immunity by *Taenia multiceps* (Cestoda): accessory macrophages and CD4+ lymphocytes are affected by two different coenurus factors. *Parasitol.* 103(Pt. 1): 139-147.
- Schilliger L, Vanderstylen D, Piétrain J and Chetboul V 2003. Granulomatous myocarditis and coelomic effusion due to *Salmonella enterica arizonae* in a Madagascar Dumerili's boa. *J Vet Cardiol.* 5(1): 43-45.
- Shin-Ichi N, Hideki H, Yukari S and Yumi U 2016. Yersiniosis caused by *Yersinia pseudotuberculosis* in captive toucans (Ramphastidae) and a Japanese squirrel (*Sciurus lis*) in zoological gardens in Japan. *J Vet Med Sci.* 78(2): 297-299.
- Schmidt V, Schneider S, Schlomer J, Krautwald-Junghanns ME and Richter E 2008. Transmission of tuberculosis between men and pet birds: a case report. *Avian Pathol.* 37(6): 589-592.
- Shivaprasad HL, Cadenas MB, Diab SS, Nordhausen R, Bradway D, Crespo R and Breitschwerdt EB 2008. Coxiella-like infection in psittacines and a toucan. *Avian Dis.* 52(3): 426-432.
- Supartika IKE, Toussaint MJM and Gruys E 2006. Avian hepatic granuloma. A review. *Vet Quarter.* 28(3): 82-89.
- Von Nickisch-Rosenegk M, Silva-Gonzalez R and Lucius R 1999. Modification of universal 12S rDNA primers for specific amplification of contaminated *Taenia spp.* (Cestoda) gDNA enabling phylogenetic studies. *Parasitol Res.* 85(10): 819-825.
- Walsh TJ, Anaissie EJ and Denning DW 2008. Treatment of aspergillosis: clinical practice guidelines of the infectious diseases society of America. *Clin Infect Dis.* 46(3): 327-360.

บทคัดย่อ

กล้ามเนื้อหัวใจอักเสบแบบแกรนูโลมาตัสในนกทูแคนดำอกขาว (*Ramphastos toco albogularis*)

เจน หลี ฮวง¹ ชินโงะ ไช¹ โอเมียร์ แอนเดรีย คาสทาเนลซา² สุพจนา เจริญสิน³
ดวงสุดา ทองจันทร์¹ โฮงอี หู^{1*}

นกทูแคนดำอกขาว (*Ramphastos toco albogularis*) อายุ 1 ปี ได้รับการตรวจวินิจฉัยพบโรคที่ไม่ได้พบบ่อย ด้วยวิธีการตรวจด้วยกล้องจุลทรรศน์ การผ่าซาก การตรวจทางจุลพยาธิสภาพ ร่วมกับการตรวจทางโมเลกุลเป็นวิธียืนยันการตรวจวินิจฉัยโรค ผลการผ่าชันสูตรซากซึ่งเป็นการตรวจวินิจฉัยเบื้องต้นพบกล้ามเนื้อหัวใจอักเสบแบบแกรนูโลมาตัสในนก และสามารถยืนยันผลด้วยการตรวจทางวิธีจุลพยาธิวิทยา การตรวจทางวิธีพีซีอาร์พบ พยาธิตัวแบนเป็นสาเหตุของการเกิดโรค การวิจัยเชื้อปรสิตก่อโรคมuscleอักเสบแบบแกรนูโลมาตัสในนกทูแคนดำอกขาวยังไม่มีรายงานมากนัก ดังนั้นควรให้ความสำคัญในการวินิจฉัยแยกโรคของสัตว์ปีกที่มีวิธีการแบบแกรนูโลมาตัส

คำสำคัญ: กล้ามเนื้อหัวใจอักเสบแบบแกรนูโลมาตัส พยาธิสภาพ โรคทางด้านปรสิต *Ramphastos toco* ไต้หวัน

¹ภาควิชาอายุรศาสตร์ทางสัตวแพทย์ คณะสัตวแพทยศาสตร์ มหาวิทยาลัยแห่งชาติด้านวิทยาศาสตร์และเทคโนโลยีผิงตง, 1 เนปู, เมืองผิงตง, ไต้หวัน

²ภาควิชาวิทยาศาสตร์และเทคโนโลยีการอาหาร, คณะเกษตรศาสตร์, มหาวิทยาลัยแห่งชาติด้านวิทยาศาสตร์และเทคโนโลยีผิงตง, 1 เนปู, เมืองผิงตง, ไต้หวัน

³ภาควิชาเกษตรเขตร้อนและความร่วมมือระหว่างประเทศ, คณะเกษตรศาสตร์, มหาวิทยาลัยแห่งชาติด้านวิทยาศาสตร์และเทคโนโลยีผิงตง, 1 เนปู, เมืองผิงตง, ไต้หวัน

*ผู้รับผิดชอบบทความ E-mail: wuhy@mail.npust.edu.tw