

9-1-2017

Prevalence and pathology of bovine coccidiosis in Faisalabad district, Pakista

Riaz Hussain

Fazal Mahmood

Ahrar Khan

Khalid Mehmood

Follow this and additional works at: <https://digital.car.chula.ac.th/tjvm>



Part of the [Veterinary Medicine Commons](#)

Recommended Citation

Hussain, Riaz; Mahmood, Fazal; Khan, Ahrar; and Mehmood, Khalid (2017) "Prevalence and pathology of bovine coccidiosis in Faisalabad district, Pakista," *The Thai Journal of Veterinary Medicine*: Vol. 47: Iss. 3, Article 13.

Available at: <https://digital.car.chula.ac.th/tjvm/vol47/iss3/13>

This Short Communication is brought to you for free and open access by the Chulalongkorn Journal Online (CUJO) at Chula Digital Collections. It has been accepted for inclusion in The Thai Journal of Veterinary Medicine by an authorized editor of Chula Digital Collections. For more information, please contact ChulaDC@car.chula.ac.th.

Prevalence and pathology of bovine coccidiosis in Faisalabad district, Pakistan

Riaz Hussain¹ Fazal Mahmood² Ahrar Khan^{2*} Khalid Mehmood¹

Abstract

The study aimed to investigate the presence of coccidial oocysts and pathological changes in a dairy herd with the history of coccidial outbreak in Faisalabad District. Fecal samples were collected from 541 animals, including cattle (379) and buffaloes (162), and examined for protozoal infection using flotation techniques. Results revealed 2.9% presence of coccidial oocysts in the samples collected. No significant difference was found in coccidial oocysts count in species of the cattle (2.3%) and buffaloes (4.3%), sex and age group. Necropsy revealed no gross lesions in thoracic organs, however, severe hemorrhages and necrotic ulcers were present in the cecum and colon. The striking features of the findings were transverse zebra striping over the mucosal surface of the large intestine of all dead animals. Histological examination of the large intestine revealed desquamation of epithelial lining, mononuclear cellular infiltration in the lamina propria and mucosal scars with severe hemorrhages. Moreover, a massive number of coccidial cells nested in the lamina propria of all infected animals. The presence of coccidial oocysts in the fecal and tissues suggested that the cattle and buffaloes died of coccidiosis.

Keywords: cattle, buffaloes, coccidiosis, necropsy, pathology

¹University College of Veterinary and Animal Sciences, The Islamia University of Bahawalpur, 63100, Pakistan

²Department of Pathology, Faculty of Veterinary Science, University of Agriculture, Faisalabad, 38000, Pakistan

*Correspondence: ahrar1122@uaf.edu.pk

Introduction

In Pakistan, various diseases badly affect growth and performance of dairy animals as well as poultry birds (Mirani et al., 2012; Bachaya et al., 2015; Khan et al., 2016). Among these, coccidiosis is one of the major and most important threat (Mufti et al., 2015). Coccidiosis, caused by *Eimeria* spp., usually occurs in young animals. There are about 13 species of *Eimeria*, of these *E. bovis* is the predominant causative agent of animal coccidiosis (Khan et al., 2013). Coccidiosis in animals mainly occurs as subclinical disease but may induce huge economic losses due to damage in intestinal tissues, resulting in malabsorption and lowered efficiency of the immune system of infected animals (Bahrami and Alborzi, 2013). The disease is characterized by anemia, depression, high morbidity, watery to bloody diarrhea, weakness and high mortality (Ahmed and Soad, 2007). Coccidiosis spreads from one animal to another and infected animals are more susceptible to various secondary infections such as bacterial enteritis and pneumonia (Oruc et al., 2015). In Pakistan, there is no published literature on pathological lesions induced by *Eimeria* infection in cattle and buffaloes. Therefore, the present study was carried out to determine the presence and pathological changes due to *Eimeria* infection.

Materials and Methods

A total of 541 animals, including 379 cattle and 162 buffaloes kept at a private dairy farm, were included in the study. Infected animals had history of watery diarrhea, anemia, emaciation, severe depression and weight loss. Despite treatment (antibiotic: procaine penicillin and colistin and multivitamins), five animals (one adult bull, two cattle calves, one bull and one buffalo calf) died. The dead

animals were necropsied, gross lesions were recorded and tissue samples from morbid organs were immediately fixed in 10% neutral buffered formalin. The tissue samples were processed for hematoxylin and eosin staining using histopathological techniques (Zubair et al., 2016).

Fresh fecal sample from each animal was collected directly from the rectum. All the samples were screened for oocysts by centrifugal flotation technique (Rehman et al., 2011). Identification of the oocyst was made as per standard procedure. Detailed history of the animals at farm including age and sex were recorded. The collected data were subjected to statistical analysis using Chi-square test. 95% C.I. and odds ratio were also determined.

Results and Discussion

In the present study, out of the 541 fecal samples, 2.9% were positive for coccidial oocysts (Table 1). In the cattle and buffaloes, coccidial oocysts were present in 2.3% and 4.3% of the samples, respectively. Non-significant difference was observed based on sex and different age groups (Table 1). However, these findings are in contrast to the results of previous different studies (Rehman et al., 2011). The findings of our study also indicated that *Eimeria* oocysts were lower in adult animals, which could be due to the stimulation of immune system and capability to control the reoccurrence of infection. Previously, higher prevalence of coccidiosis in young calves (Alemayehu et al., 2013) and dairy cattle has been reported (Dong et al., 2012), which could be related to hygienic conditions of farms, management systems, intense crowding, contamination of feed, nutritional and immune status of the infected animals. Improvement in the hygienic conditions of a farm could reduce the prevalence of coccidial oocysts in feces (Svensson, 1993).

Table 1 Overall and species based presence of coccidial oocytes (%) in animals of both sexes and different age groups having history of diarrhea and mortality

Sex/age	No. of Animals	Positive		95% CI	Odds Ratio/ P value
		n	%		
Overall					
Sex					
Female	478	13	2.7	1.52-4.49	OR = 0.56 [reciprocal = 1.79]
Male	63	3	4.7	1.23-12.41	
Overall	541	16	2.9	1.76-4.66	
Age groups (Years)					
1-2	139	4	2.8	0.92-6.79	Mantel-Haenszel chi-sq P < 0.780
3-5	235	8	3.4	1.59-6.36	
5-8	167	4	2.4	0.77-5.68	
Cattle					
Male	36	2	5.5	0.94-17.16	OR = 2.82 [reciprocal = 0.35]
Female	343	7	2.0	0.90-3.99	
Total	379	9	2.3	1.16-4.31	
Age groups (Years)					
1-2	97	2	2.0	0.35-6.64	Mantel-Haenszel chi-sq P < 0.815
3-5	163	5	3.1	1.13-6.67	
5-8	119	2	1.6	0.28-5.44	
Buffaloes					
Male	27	1	3.7	0.19-16.94	OR = 0.83 [reciprocal = 1.21]
Female	135	6	4.4	1.82-9.01	
Total	162	7	4.3	1.91-8.36	
Age groups (Years)					
1-2	42	2	4.7	0.81-14.85	Mantel-Haenszel chi-sq P < 0.897
3-5	72	3	4.1	1.07-10.92	
5-8	48	2	4.2	0.70-13.09	

Postmortem examination revealed no gross lesions in the abdominal and thoracic visceral tissues. However, the lower digestive tract, particularly the colon and cecum, was severely congested and exhibited massive corrugations with elevated polyp-like necrotic lesions of about 5 mm in size with sharp and demarcated hyperemic margins (Fig. 1a). Mucosa of the descending colon exhibited severe ulceration, the ulcer margins were severely hemorrhagic and the centers were necrotic and yellowish in color (Fig. 1b). The microvascular bed was severely engorged with erythrocyte and there were extensive transverse hemorrhagic streaks or zebra striping in the colon (Fig.

1c). In contrast to these findings, Friend and Stockdale (1980) reported granular mucosae of the colon and cecum covered by diphtheritic membranes along with marked edema of mucosa as well as submucosa. Fibrous tissue proliferation was also observed in the form of fibrin strands admixture having small amount of blood and casts among schizonts population in the gut lamina. The gross lesions observed in the present study such as corrugated colon, folded mucosa of the ascending and descending colon have not been previously reported in cross-bred cattle and buffaloes in association with coccidiosis.

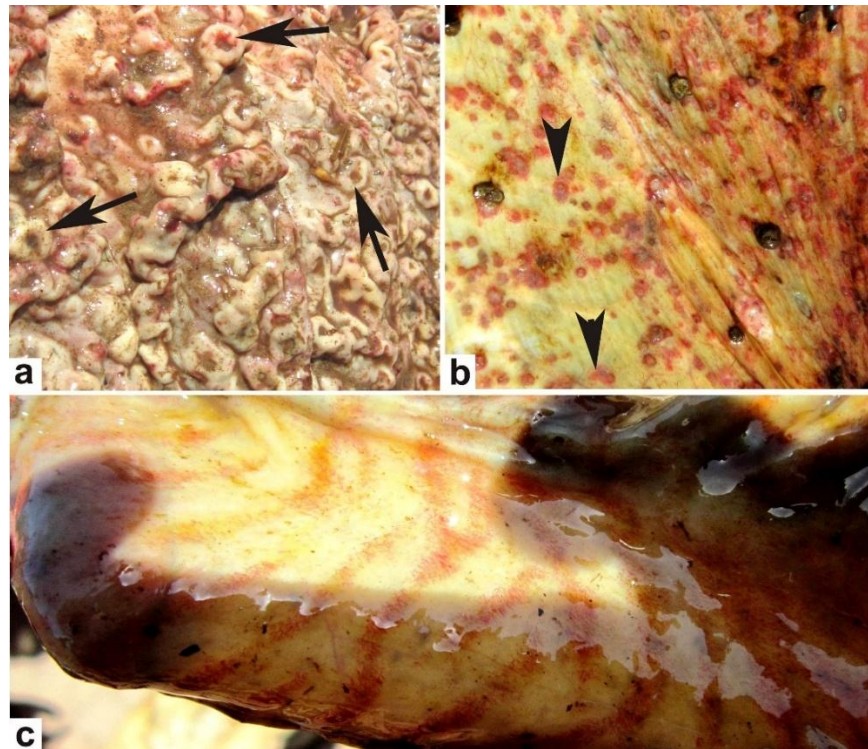


Figure 1 a) Intestine of buffalo showing massive corrugations with elevated polyp-like necrotic lesions (arrows), b) descending colon of cow exhibiting severe ulceration (arrow heads), hemorrhages and necrotic lesions, and c) colon of cow showing extensive transverse hemorrhagic streaks or zebra striping.

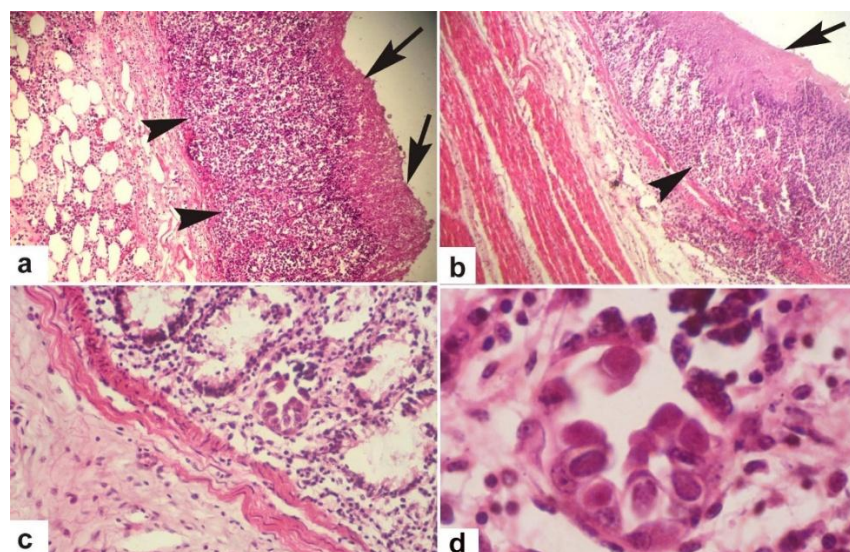


Figure 2 Photomicrograph of intestine. a and b) mucosa is covered with thick mucous (arrows), lamina propria infiltrated with macrophages, lymphocytes, polymorphonuclear and plasma cells (arrow heads), X100; c) crypts of the intestinal villi showing cogwheel formation of epithelial cells infected with coccidia, X200; and d) higher magnification of coccidal cysts, X 400. H&E stain.

Microscopically, the intestinal mucosal linings were covered with thick mucous (Figs. 2a and 2b). The mucosa was eroded and ulcerated, and the center of the ulcers was necrotic and occupied the predominantly healing granulation tissue, although the edges were heavily infiltrated with inflammatory cells, particularly mononuclear cells (Figs. 2a and 2b).

The intestinal villi were small, blunt, ulcerated and destructed, and the intervillus spaces were infiltrated with leukocytes. The lamina propria was also infiltrated with macrophages, lymphocytes, polymorphonuclear (PMNs) and plasma cells (Fig. 2b). These inflammatory changes in the lamina propria could be due to massive damage to the apical cells through migration and division of oocysts that led to the production of some intra and extra cellular molecular DAMPS including interleukin. As well as specific stimuli characteristic of coccidian invasion trigger type 2 immune response. Induction of tissue injury by oocytes induces the release of cytokine alarmins (IL-33, IL-25 and TSLP), which are responsible for the recruitment of lymphoid progenitor origin cells, including TH2, TH9, MPP type2 cells and ILC2 from common lymphoid defensive cells from the general circulation to the invasion site (Bachaya et al., 2015; Khan et al., 2016). Similar degenerative and inflammatory changes in the mucosae have also been reported in experimentally infected Holstein calves with *E. zuernii* (Mundt et al., 2005). In the present study, the highest concentration of schizonts was observed in the ileo-cecal junction. These results agree with the observations of Friend and Stockdale (1980).

Histologically, the schizonts, trophozoites and degenerating macrogametes in colonic glands were not observed in the present study. However, the characteristic cogwheel formation of epithelial cells infected with coccidian parasite was frequently observed within the crypts of the intestinal villi (Figs. 2c and 2d). Previously, infected cecal epithelial cells in syncytial formation have been reported in the *Eimeria* infection. Microabscesses were observed in deeper part of the mucosa of intestine as a result of occlusion of crypts of Lieberkühn due to massive division of the oocysts as previously reported (Hammond et al., 1973; Bachaya et al., 2015), which were not observed in our study. Moreover, heavy infiltration of chronic inflammatory cells, connective tissue proliferation in lamina muscularis and submucosa of both the large and small intestines have been reported in experimentally infected Holstein calves with *Eimeria bovis* (Mundt et al., 2005).

From the results of the present study, it can be concluded that bovine coccidiosis is a serious threat to the livestock sector in this region. The gross and histological observations of our study can be a valuable tool for early diagnosis to reduce considerable economic losses due to this deadly infestation.

References

- Ahmed MW and Soad EH. 2007. Applied studies on coccidiosis in growing buffalo calves with special reference to oxidant/antioxidant status. *World J Zool.* 2(2): 40-48.
- Ahmed MW and Soad EH. 2007. Applied studies on coccidiosis in growing buffalo calves with special reference to oxidant/antioxidant status. *World J Zool.* 2(2): 40-48.
- Alemayehu A, Nuru M and Belina T. 2013. Prevalence of bovine coccidia in Kombolcha district of South Wollo, Ethiopia. *J Vet Med Anim Health.* 5: 41-45.
- Bachaya HA, Abbas RZ, Raza MA, Iqbal Z, Rehman TU, Baber W and Hussain R. 2015. Existence of coccidiosis and associated risk factors in broiler chickens in Southern Punjab, Pakistan. *Pak Vet J.* 35(1):81-84.
- Bahrami S and Alorzi AR. 2013. Prevalence of subclinical coccidiosis in river buffalo calves of southwest of Iran. *Acta Parasitol.* 58(4): 527-530.
- Dong H, Zhao Q, Han H, Jiang L, Zhu S, Li T, Kong C and Huang B. 2012. Prevalence of coccidial infection in dairy cattle in Shanghai, China. *J Parasitol.* 98(5): 963-966.
- Friend SCE and Stockdale PHG. 1980. Experimental *Eimeria bovis* infection in calves: A histopathological study. *Canadian J Comp Med.* 44(2): 129-140.
- Hammond DM. 1973. Life cycles and development of coccidia. In: *The Coccidia. Eimeria, Isospora, Toxoplasma and Related Genera.* Baltimore, Maryland: University Park Press, pp: 48.
- Khan JM, El-Ashram S, Liu HB, Khan SH, Ayan A, Liu XY, Wang H, Tang XM, Suo X and Hassan MF. 2016. Transgenic *Eimeria mitis* expressing chicken IL-4 mediated decrease in pathogenicity compared to wild type *Eimeria mitis* strains in broiler chickens. *Pak Vet J.* 36(4): 415-420.
- Khan MN, Rehman TU, Sajid MS, Abbas RZ, Zaman MA, Sikandar A and Riaz M. 2013. Determinants influencing prevalence of coccidiosis in Pakistani buffaloes. *Pak Vet J.* 33(3): 287-290.
- Mirani AH, Shah MGU, Mirbahar KB, Khan MS, Lochi GM, Khan IU, Alam F, Hasan SM and Tariq M. 2012. Prevalence of coccidiosis and other gastrointestinal nematode species in buffalo calves at Hyderabad, Sindh, Pakistan. *Afr J Microbiol Res.* 6(33): 6291-6294.
- Mufti S, Kiran A, Khan IA, Irum S, Qureshi IZ, Rizvi SSR, Mukhtar M, Mushtaq M, Iqbal Z and Qayyum M. 2015. Serological and coprological studies of bovine fasciolosis in the Pothwar Region, Pakistan. *Pak Vet J.* 35(2): 178-182.
- Mundt HC, Bangoura B, Rinke M, Rosenbruch M and Dauschies A. 2005. Pathology and treatment of *Eimeria zuernii* coccidiosis in calves: investigations in an infection model. *Parasitol Int.* 54(4): 223-230.
- Oruc E, Saglam YS, Sozdutmaz I, (Kapakin KAT, Temur A and Altun S. 2015. The investigation of bovine viral diarrhoea virus antigens with immunofluorescence and immunohistochemical methods in bovine abortions. *Pak Vet J.* 35(4): 426-429.
- Rehman TU, Khan MN, Khan IA and Ahmad M. 2011. Epidemiology and economic benefits of treating goat coccidiosis. *Pak Vet J.* 31(3): 227-230.
- Svensson C. 1993. Peripartur excretion of *Eimeria* Oocyst by cows on Swedish dairy farms and the

age of calves at first excretion. *Acta Vet Scand.* 34(1): 77-81.

Zubair M, Ahmad M, Jamil H and Deeba F. 2016. Dietary vitamin E supplementation: A strategy to combat arsenic induced toxicity in teddy bucks. *Pak Vet J.* 36(4): 455-459.

บทคัดย่อ

ความชุกและพยาธิวิทยาของโรค Coccidiosis ในโค ในเขตไพศาลาบาด ประเทศปากีสถาน

รืออาช ฮัสเซน¹ ฟาซาล มานฮูต² อาหารา ข่าน² คาลิต เมห์มูด¹

การศึกษานี้มีวัตถุประสงค์เพื่อศึกษา oocysts ของเชื้อ coccidia และการเปลี่ยนแปลงทางพยาธิวิทยา ในฝูงโคนมที่มีประวัติของการระบาดของโรค Coccidiosis ในเขตไพศาลาบาด โดยเก็บตัวอย่างอุจจาระจาก สัตว์จำนวน 541 ตัวอย่าง แบ่งเป็น โค 379 ตัว และกระบือ 162 ตัว และตรวจหาเชื้อโปรโตซัวโดยใช้เทคนิค flotation ผลการศึกษาพบ oocysts ของ coccidia 2.9% แต่ไม่พบความแตกต่างอย่างมีนัยสำคัญ ระหว่างโค (2.3%) และกระบือ (4.3%) รวมทั้งเพศและกลุ่มอายุ ผลการผ่าซากสัตว์ไม่พบรอยโรคขั้นต้นในอวัยวะทรวงอก อย่างไรก็ตามพบแผลหลุม และเลือดออก ในลำไส้ใหญ่ส่วน cecum และ colon โดยมีรอยโรคที่สำคัญคือ แผลขาวขวางบนพื้นผิวเยื่อเมือกของลำไส้ใหญ่ของสัตว์ ผลการตรวจสอบทางจุลพยาธิวิทยาของลำไส้ใหญ่พบเยื่อแบบ desquamation และมีการแทรกของ mononuclear cell ใน lamina propria และรอยแผลเป็นของเยื่อเมือกที่มีเลือดออกอย่างรุนแรง นอกจากนี้ยังพบเซลล์ coccidia จำนวนมากใน lamina propria ของสัตว์ที่ติดเชื้อ โดยสรุปการพบ oocysts ของ coccidia ในอุจจาระและเนื้อเยื่อ บ่งบอกถึงการติดเชื้อและเสียชีวิตของสัตว์จากโรค coccidiosis

คำสำคัญ: โค กระบือ coccidiosis การผ่าซาก พยาธิวิทยา

¹วิทยาลัยสัตวแพทยศาสตร์และสัตวศาสตร์ มหาวิทยาลัยอิสลาม แห่งบาชาวัลเปอร์, 63100, ประเทศปากีสถาน

²ภาควิชาพยาธิวิทยา คณะสัตวแพทยศาสตร์ มหาวิทยาลัยเกษตรศาสตร์, ไพศาลาบาด, 38000, ประเทศปากีสถาน

*ผู้รับผิดชอบบทความ E-mail: ahrar1122@uaf.edu.pk