

3-1-2017

What is Your Diagnosis?

Chutimon Thanaboonnipat

Nan Choisunirachon

Follow this and additional works at: <https://digital.car.chula.ac.th/tjvm>



Part of the [Veterinary Medicine Commons](#)

Recommended Citation

Thanaboonnipat, Chutimon and Choisunirachon, Nan (2017) "What is Your Diagnosis?," *The Thai Journal of Veterinary Medicine*: Vol. 47: Iss. 1, Article 9.

Available at: <https://digital.car.chula.ac.th/tjvm/vol47/iss1/9>

This Other is brought to you for free and open access by the Chulalongkorn Journal Online (CUJO) at Chula Digital Collections. It has been accepted for inclusion in The Thai Journal of Veterinary Medicine by an authorized editor of Chula Digital Collections. For more information, please contact ChulaDC@car.chula.ac.th.

What is Your Diagnosis?

Chutimon Thanaboonnipat Nan Choisunirachon

Signalment

A fourteen-kilogram, 8 year-old, intact female, mixed breed dog.

History

The patient was a stray dog that showed up to the Small Animal Teaching Hospital, Chulalongkorn University by an adoptive owner with traumatic history due to the car accident since 4 days prior the presentation. Other chief complains from owner were lameness of the right hind limb and a small amount of bleeding from the genital organ.

Clinical examination

After the physical examination, especially palpation, pain at the right hip area and right hip joint instability in according to the suspected pelvic bone fracture and dislocation was found. In addition, on the auscultation, cardiac murmur was noted.

Radiographic examination

In according to the suspected pelvic bone fracture and heart murmur sound, the thoracic radiographic examination was assigned for examining the intra-thoracic organs as the screening data prior the anesthetic procedure and pelvic fracture immobilization.

What is your diagnosis?
Please turn to next page for the answer.

Radiographic findings

On both thoracic radiographs, diaphragmatic lines, both of right and left sides, were found at different areas. By the lateral radiographic projection, the diaphragmatic lines were parallel but that of the right side was obviously cranially displaced (arrow) comparing to the left side (Fig.1). On the ventrodorsal view, the tip of right diaphragmatic crus was at the 8th vertebral level whereas that of the left side was at the 11th vertebrae. In addition to the diaphragm, the enlarged cardiac silhouette by the increase of the cardiothoracic ratio (80 percentage, approximately) and vertebral scale system (12 vertebra) was suggested. The cardiac shape revealed the bulging of craniodorsal cardiac quadrant with losing of cranial cardiac waist

and the bulging of the 3, 5 and 10 O'clock areas on the ventral dorsal view. Besides, the tracheal alignment was elevated at the caudal thoracic area, especially at the tracheal bifurcation. Both radiographic findings of the heart and trachea might indicate bilateral cardiac enlargements, especially the left sided-heart area. Pulmonary parenchyma showed that there was a small amount of interstitial lung infiltration at the perihilar area on lateral radiograph whereas that of the right radiographic view was detected only at the right lung lobes. Furthermore, small interlobar signs were detected at the caudoventral area of the lateral thoracic view and right middle and caudal areas of the ventrodorsal view.

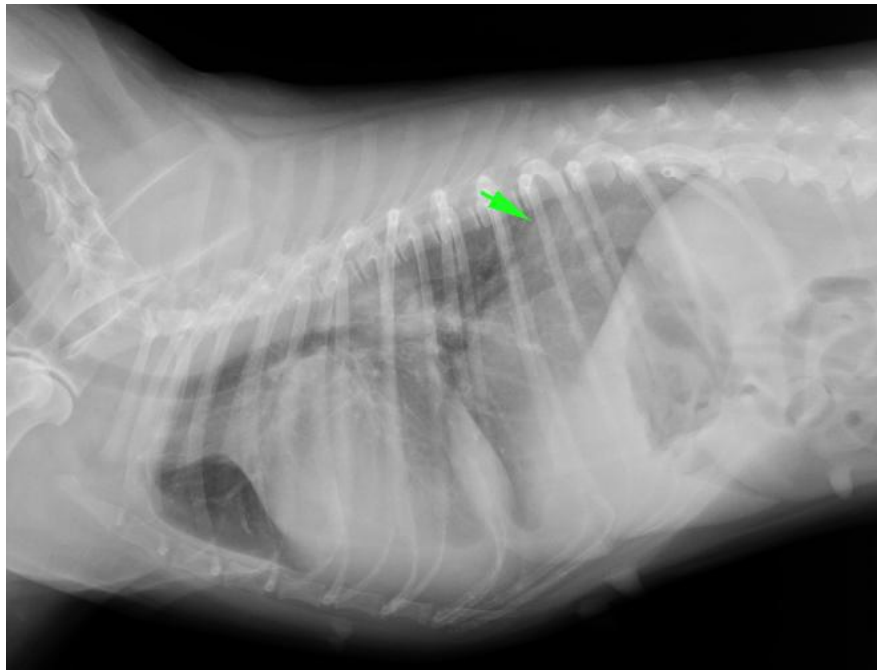


Figure 1 The right lateral view of thoracic radiograph showed that the diaphragmatic lines were parallel but the right diaphragmatic crus was distinctively displaced to the cranial area (arrow) comparing to that of the left. Other intra-thoracic radiographic signs were a moderate degree of whole heart enlargement with elevated trachea, interstitial lung pattern at the perihilar area and suspected interlobar fissure between the left cranial and left caudal lung lobes.

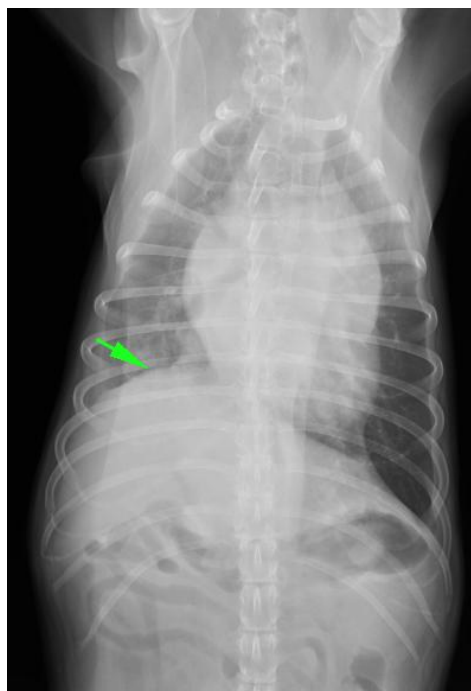


Figure 2 The ventrodorsal view of thoracic radiograph revealed the cranial displacement of the right diaphragmatic crus cranially to the 8th vertebral area (arrow) whereas that of the left side was at the 11th vertebrae. In addition, the cardiac shape was bulged at the 3, 5 and 10 O'clock areas. Besides, the right lung lobes were increased in soft tissue density with interstitial pattern and small interlobar fissures were seen at the right middle and caudal hemithorax.

Radiographic diagnosis

Diaphragmatic paralysis.

Discussion

There were several of diseases or conditions that effected to the shape of diaphragm in dogs and cats; for example, the thoracic mass pushing the diaphragmatic line, hiatal hernia, diaphragmatic neoplasia, unilateral tension pneumothorax, diaphragmatic eventration, and hemiparalysis of the diaphragm (Randal and Park, 2013). Contrary to the diaphragmatic eventration that usually found as the congenital anomaly and coincidence with other congenital defects, the etiology of hemiparalysis of the diaphragm could be the idiopathic condition but most of the cases showed up due to the traumatic causes, especially the trauma of the caudal thoracic-proximal rib areas. The rib fracture might induce the injury of phrenic nerve that subsequently causes the diaphragmatic paralysis. To confirm the diaphragmatic paralysis, there are several modalities could be applied such as comparing thoracic radiograph, both of the inspiration and expiration phases, the fluoroscopy and ultrasonography using the motion scan mode (Choi et al., 2014).

Reference

- Randall EK and Park RD 2013. The Diaphragm. In: Textbook of Veterinary Diagnostic Radiology. 6thed. ED Thrall(ed). Elsevier, Missouri. 535 - 549.
- Choi M, Led N, Kim A, Keh S, Lee J, Kim H and Choi M 2014. Evaluation of diaphragmatic motion in normal and diaphragmatic paralyzed dogs using M-mode ultrasonography. Vet. Radiol and Ultrasound. 55 (1): 102 - 108.