

12-1-2016

What is Your Diagnosis?

Chutimon Thanaboonnipat

Nan Choisunirachon

Follow this and additional works at: <https://digital.car.chula.ac.th/tjvm>



Part of the [Veterinary Medicine Commons](#)

Recommended Citation

Thanaboonnipat, Chutimon and Choisunirachon, Nan (2016) "What is Your Diagnosis?," *The Thai Journal of Veterinary Medicine*: Vol. 46: Iss. 4, Article 27.

DOI: <https://doi.org/10.56808/2985-1130.2797>

Available at: <https://digital.car.chula.ac.th/tjvm/vol46/iss4/27>

This Other is brought to you for free and open access by the Chulalongkorn Journal Online (CUJO) at Chula Digital Collections. It has been accepted for inclusion in The Thai Journal of Veterinary Medicine by an authorized editor of Chula Digital Collections. For more information, please contact ChulaDC@car.chula.ac.th.

What is Your Diagnosis?

Chutimon Thanaboonnipat Nan Choisunirachon

Signalment

A nineteen-kilogram, 14 year-old, intact male, English Cocker Spaniel.

History

The patient was presented to the Diagnostic Imaging Unit of the Small Animal Teaching Hospital, Chulalongkorn University due to anxious and restless. Besides, the dog was previously showed the clinical signs of vomiting and diarrhea.

Clinical examination

On the physical examination, the dog was slightly obese with 4/5 body condition score. In

addition to normal hydration, heart rate, heart sound and lung sound, pale mucus membrane was detected at gingival area. After laboratory examination of hematology and serum biochemistry, severe anemia with mild leukocytosis and azotemia were detected

Radiographic examination

Due to the gastrointestinal signs both of vomiting and anemia, the dog was subjected for abdominal radiographic screening. Therefore, right lateral and ventrodorsal radiographic views of abdomen were taken.

What is your diagnosis?
Please turn to next page for the answer.

Radiographic findings

Both abdominal radiographs revealed the increased soft tissue opacity with less distinction of intra abdominal serosal peritoneum (Fig.1 and 2). In addition to those radiographic signs, there were evidences of a small amount of gas accumulated in the stomach and descending colon. On the lateral radiographs, narrowing intervertebral disc spaces were clearly seen between the L2 - L3 and L3 - L4. Moreover, there was evidence of the central bone

erosive lesion with adjacent bone sclerosis at the vertebral end plates of L2 - L3 (Fig.1, arrow). On the ventrodorsal view of abdomen, in addition to the less distinction of peritoneum, there was evidence of a 7 x 7 mm, well defined, round to oval shape, radiodense material at the right cranio-paramedial abdomen with superimposed on the right renal pelvis area (Fig.2, arrow head).

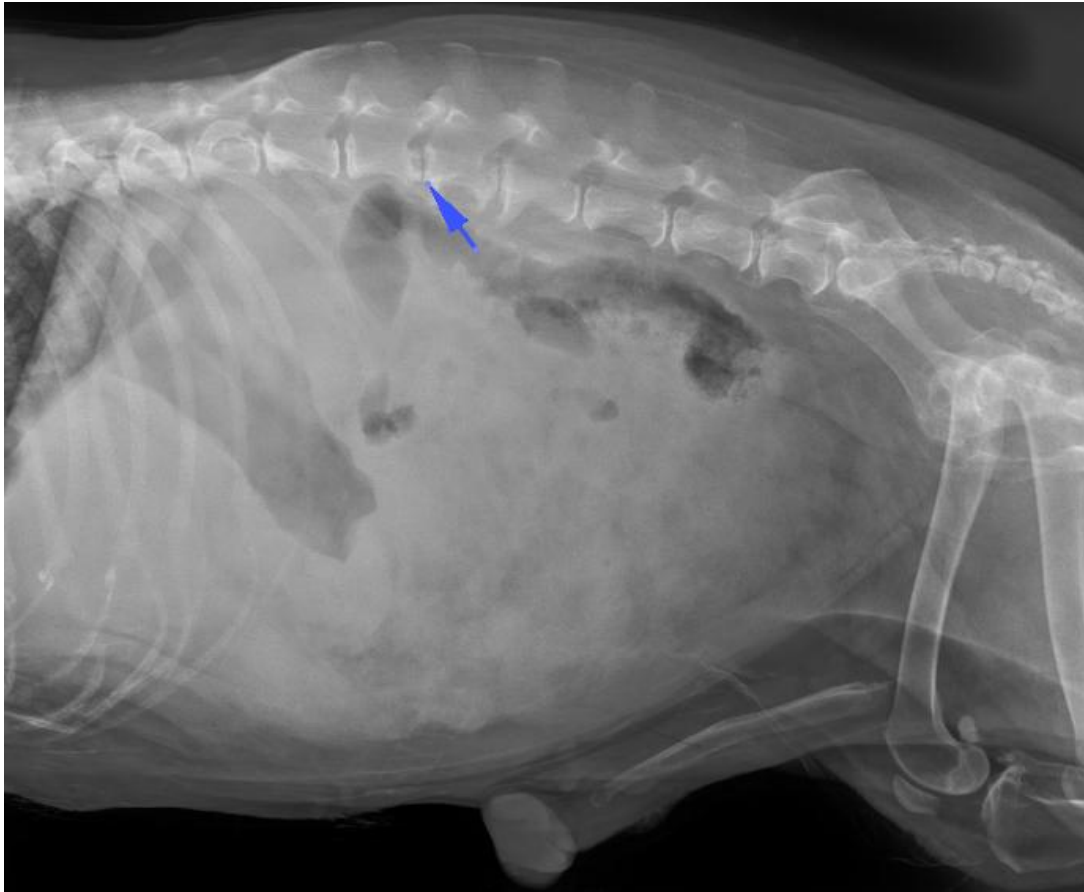


Figure 1 The right lateral projection of abdominal radiograph revealed the increased soft tissue opacity at the intra-abdominal area with less distinction of abdominal serosal peritoneum. There was a small amount of gas accumulation in the gastrointestinal tract, especially at the stomach and descending colon. In addition to the intra-abdominal lesion, there were narrowing intervertebral disc space with ventral bone spurs between L2 - L3 and L3 - L4. There was evidence of the central osteolysis between the L2 - L3 vertebral end plates (arrow).

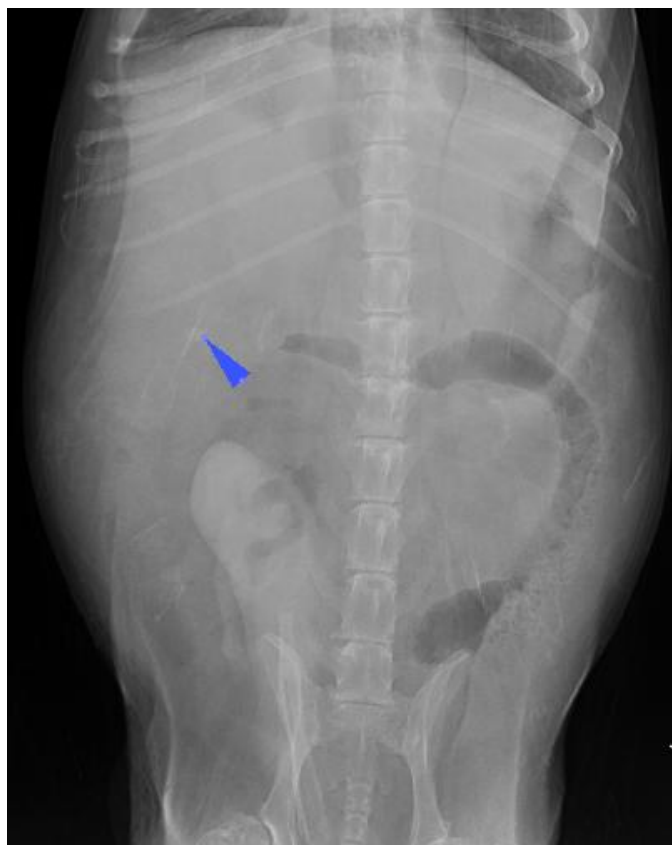

Figure 2 The ventrodorsal projection of abdominal radiograph revealed a well defined, round to oval shape, radiodense material (7 x 7 mm, arrow head) at the right cranio-paramedial abdomen which the same area of the right renal pelvis. In addition, the intervertebral space with osteosclerosis and lateral bone spurs were detected between the intervertebral disc space of L2 - L3 and L3 - L4.

Radiographic diagnosis

Discospondylitis and peritonitis.

Discussion

Discospondylitis is an infection condition of the intervertebral disc space. The source of infection usually comes from the hematogenous route (Kinzel et al., 2005), mostly originated from urinary system such as urinary bladder or prostate gland of genital system. In present patient, intra-peritoneal infection might be the primary cause of hematogeneous infection. The microorganisms that have been reported to induce discospondylitis were bacteria (Schwartz et al., 2009) (mostly the *Staphylococcus* spp.) or fungus (Butterworth et al., 1995). The onset of neurologic signs of discospondylitis could be depended on the severity of spinal involvement. The affected patients might show the signs ranging from hyperesthesia to paralysis. To detect the discospondylitis, radiographic lesion usually revealed after weeks of the primary infection. The lesion generally revealed as the osteolysis of central intervertebral end plates with adjacent bone sclerosis that have seen in this patient. Besides, spondylosis with new bone formation may also be detected. In severe case, the collapse vertebral column with subluxation of vertebral body could be possible (Davis et al., 2000).

Reference

Butterworth SJ, Barr FJ, Pearson GR and Day MJ 1995. Multiple discospondylitis associated with *Aspergillus* species infection in a dog. *Vet Rec.* 136 (2): 38 - 41.

Davis MJ, Dewey CW, Walker MA, Serwin SC, Moon ML, Kortz GD, Koblik PD, Mahaffey MB, Budsberg SC and Slater MR 2000. Contrast radiographic findings in canine bacterial discospondylitis: a multicenter, retrospective study of 27 cases. *J Am Anim Hosp Assoc.* 36 (1): 81 - 85.

Kinzel S, Koch J, Buecker A, Krombach G, Stopinski T, Afify M and Kupper, W 2005. Treatment of 10 dogs with discospondylitis by fluoroscopy-guide percutaneous discectomy. *Vet Rec.* 156: 78 - 81.

Schwartz M, Boettcher IC, Kramer S and Tipold A 2009. Two dogs with iatrogenic discospondylitis caused by methicillin-resistant *Staphylococcus aureus*. *J Small Anim Pract.* 50 (4): 201 - 205.