

12-1-1989

MeduUoepithelioma : Unsuspected intraocular tumor in children

Krailert Thiennukul

Vira Kasantikul

Pornsawat Nantawan

Follow this and additional works at: <https://digital.car.chula.ac.th/clmjournal>



Part of the [Medicine and Health Sciences Commons](#)

Recommended Citation

Thiennukul, Krailert; Kasantikul, Vira; and Nantawan, Pornsawat (1989) "MeduUoepithelioma : Unsuspected intraocular tumor in children," *Chulalongkorn Medical Journal*: Vol. 33: Iss. 12, Article 10. DOI: 10.58837/CHULA.CMJ.33.12.10
Available at: <https://digital.car.chula.ac.th/clmjournal/vol33/iss12/10>

This Case Report is brought to you for free and open access by the Chulalongkorn Journal Online (CUJO) at Chula Digital Collections. It has been accepted for inclusion in Chulalongkorn Medical Journal by an authorized editor of Chula Digital Collections. For more information, please contact ChulaDC@car.chula.ac.th.

Medulloepithelioma : Unsuspected intraocular tumor in children.

Krailert Thiennukul*

Vira Kasantikul** Pornsawat Nantawan*

Thiennukul K, Kasantikul V, Nantawan P. Medulloepithelioma : Unsuspected intraocular tumor in children. Chula Med J 1989 Dec; 33(12): 955-960

Two cases of medulloepithelioma of the eye are described. Both patients presented with leukocoria, endophthalmitis, and intraocular mass. The lesions were mistaken as retinoblastoma on clinical grounds. Clinicians should be aware of this unusual tumor when children, particularly those in the first decade of life, present with such clinical symptoms.

Reprint request : Thiennukul K, Department of Ophthalmology, Faculty of Medicine, Chulalongkorn University, Bangkok 10330, Thailand.

Received for publication. October 9, 1989.

* Department of Ophthalmology, Faculty of Medicine, Chulalongkorn University.

** Department of Pathology, Faculty of Medicine, Chulalongkorn University.

ไกรเลิศ เชียร์นุกูล, วีระ กสานครีกุล, พรสวรรค์ นันทวัน. เมดัลโลอีพิเธลิโอมา: เนื้องอกในลูกตาเด็กที่ไม่คาดคิด. จุฬาลงกรณ์เวชสาร 2532 ธันวาคม; 33(12): 955-960

รายงานผู้ป่วยเด็ก 2 ราย ซึ่งมาพบจักษุแพทย์ด้วยเรื่อง *leukocoria*, *endophthalmitis*, และ *intraocular mass* ผู้ป่วยดังกล่าวได้รับการวินิจฉัยตามประวัติและลักษณะการตรวจพบต่างๆ ว่าเป็น *retinoblastoma* ซึ่งเป็นเนื้องอกในตาที่พบบ่อยในเด็ก ผลการตรวจทางพยาธิวิทยาของตาในผู้ป่วยทั้งสองรายที่ได้รับการรักษาโดยวิธีผ่าตัดตาออก (*enucleation*) พบว่าเป็น *medulloepithelioma* ซึ่งเป็นเนื้องอกชนิดไม่ร้ายแรงที่พบในลูกตา จากการทบทวนวารสารพบเนื้องอกชนิดนี้เพียง 3 รายในประเทศไทย ผู้ป่วยมักเป็นเด็กอ่อน หรือเด็กเล็กที่มีอายุเฉลี่ยประมาณ 5 ปี จักษุแพทย์จึงควรนึกถึงเนื้องอกชนิดนี้ด้วย โดยเฉพาะในผู้ป่วยเด็กที่มาด้วยปัญหาดังกล่าว

Medulloepithelioma or diktyoma of the eye is an uncommon neoplasm usually occurring in young children.^(1,2) To our knowledge only one example has been recorded previously in Thailand.⁽²⁾ In this communication we have encountered two additional cases. The related medical literature is reviewed.

CASE REPORT

CASE 1

A 15-month-old girl was hospitalized in August 1984 because of endophthalmitis and leukocoria in the right eye. Her mother had observed that the baby developed a red eye and a white spot in the pupil for 2 months. She received antibiotic and steroid drugs from the ophthalmologists without clinical improvement. The patient was then referred to Chulalongkorn Hospital for further management.

Examination revealed conjunctivitis, corneal edema, flat anterior chamber, rubeosis iridis, seclusio pupil, yellow and opaque lens of the right eye. Tactile tension was normal. The left eye was unremarkable.

Routine laboratory data were within normal

limits. Roentgenograms of the chest, skull, and long bones showed no evidence of metastases. Ultrasonogram of the right eye disclosed a retrolental high density mass of 5 mm. in axial length, not connected to the retina or choroid. The vitreous was clear and the thickening choroid was 2 mm. The clinical diagnosis was retinoblastoma. The child underwent an enucleation of the right eye. The postoperative course was uncomplicated. The patient had been followed up for 6 months and remained clinically silent.

The specimen of the tissue in this case as well as in the other (case 2) were fixed in 10% formalin, embedded in paraffin and stained with hematoxylin and eosin. A small 0.7 cm. gray-white nodule was located in the retrolental space of the enucleated eyeball (Fig.1A). Microscopically, the lesion consisted of columnar cells with oval nuclei. The tumor cells were arranged in tubular and papillary pattern with distinct limiting membrane resembling the medullary epithelium of embryonic non-pigmented ciliary epithelium (Fig.1B). Mitotic activity was absent.

Figure 1A. Macrophotomicrograph of retrolental medulloepithelioma (case 1).

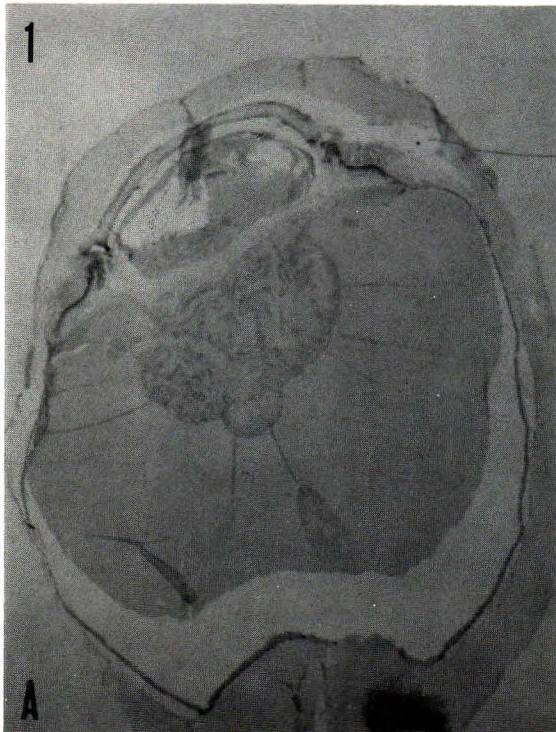
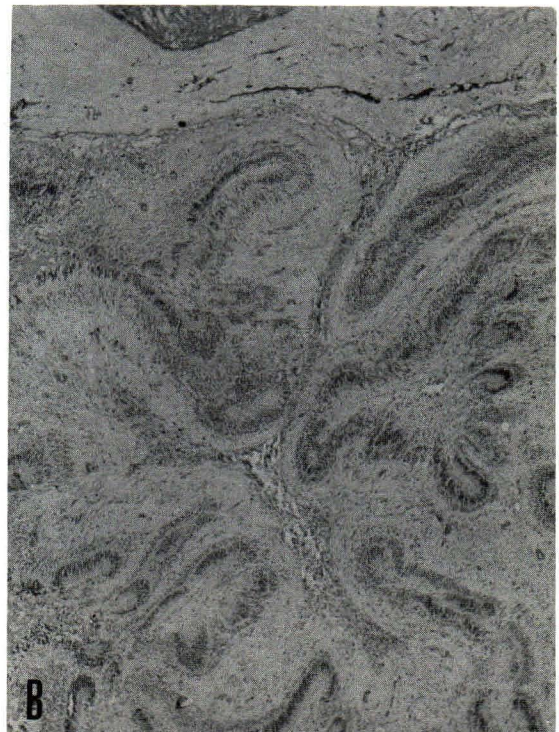
Figure 1B. A complex convolution of columnar epithelium with distinct limiting membrane. (H&E × 100)



The pathologic diagnosis was benign non-teratoid medulloepithelioma of the right eye.

CASE 2

A 30-month-old girl presented with redness in the right eye, lid edema, and fever for 2 months following a history of trauma to the right eye. She received medications with some clinical improvement. Two weeks later, a small nodule was noted in the pupil of the right eye. The lesion was slowly enlarging. A computed tomographic (CT) scan disclosed increased density and enhancement of the ciliary muscle, anterior chamber and lens of the right globe. The patient was referred to Chulalongkorn Hospital in April 1989 for further management of endophthalmitis and intraocular mass of her right eye.

Examination revealed posterior synerchia of the iris, leukocoria and a mass of 10 disc in diameter

which was seen on the optic disc of the right eye. The left eye was normal.

Routine laboratory data were unremarkable. Ultrasonogram demonstrated thickened retina and choroid with calcification. The clinical diagnosis was retinoblastoma. An enucleation of the right eye was performed. The postoperative course was uneventful.

The enucleated eyeball showed a 1.5 cm. grayish white irregular nodule in the retrolental space (Fig 2). A 0.5 cm. optic nerve was found without gross abnormalities. Microscopically, the tumor displayed a complex convolution of columnar epithelium similar to the lesion in case 1 (Fig.3). The inner free surface of the tubules was bounded by a limiting membrane while on the opposite surface, the cells rested on the supporting stroma. Rossette formation and mitoses were absent.

Figure 2. Gross appearance of diktyoma (case 2). The growth appears as an irregular grayish white mass in the retrolental space. The optic nerve is unremarkable.

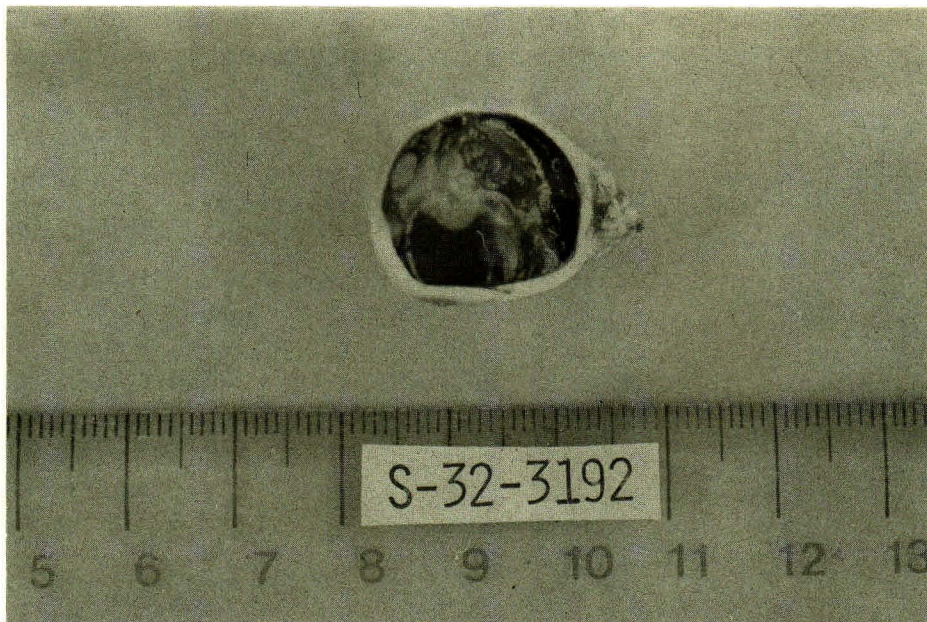
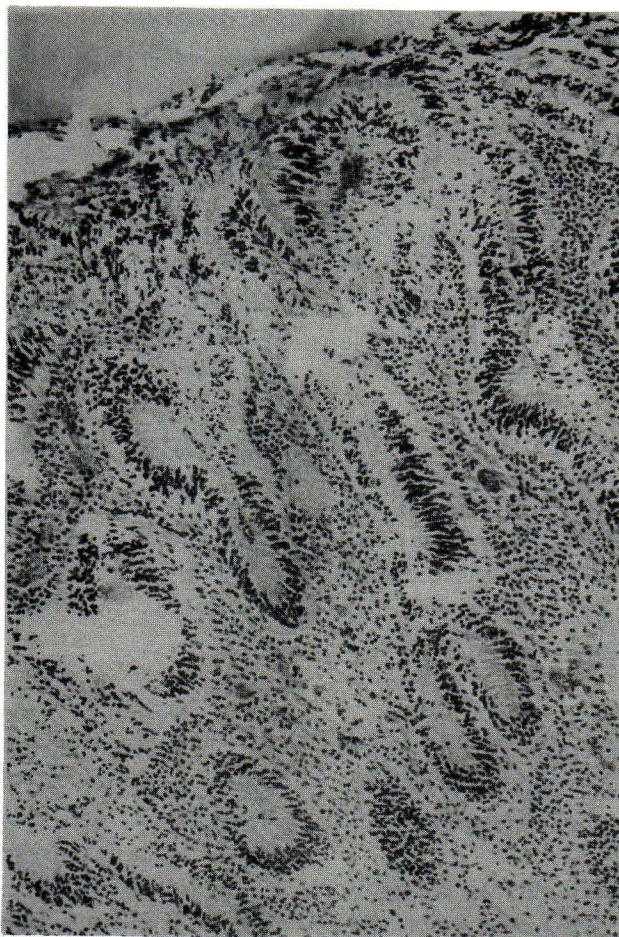


Figure 3. Layer of columnar cells with oval nuclei presenting a tubular arrangement. (H&E \times 100)



The pathologic diagnosis was benign non-teratoid medulloepithelioma of the right eye.

DISCUSSION

Medulloepithelioma has been recognized as a distinctive entity. Diagnosis rests on the characteristic morphological features including the pattern of papillary and tubular arrangement of the primitive non-pigmented ciliary epithelium with a distinct limiting membrane. In the cases presented, the histopathological findings conform in every detail with this unusual neoplasm.

Medulloepithelioma more commonly has been referred to as "diktyoma" which means net-like. The latter term was introduced by Fuchs in 1908.⁽³⁾ Grinker proposed the term "medulloepithelioma" because the author considered that this tumor arises from non-pigmented ciliary epithelium which persisted in an undifferentiated form resembling medullary epithelium throughout adult life.⁽⁴⁾ According to

Zimmerman, medulloepithelioma was a congenital tumor which developed from the immature ciliary epithelium, either during embryonic development in utero or from a persistent anlage of this undifferentiated epithelium during the early postnatal period.⁽⁵⁾ The symptoms and signs may not appear until long after birth. Diktyoma may arise from various parts of the eye including the iris, optic nerve, and retina.⁽⁶⁻⁸⁾ The tumor has been classified into teratoid and nonteratoid types and each further divided into benign or malignant varieties.⁽⁹⁾ Teratoid group contains one or more heteropic tissues that are not normally present in the eyes such as hyaline cartilage, rhabdomyoblasts and cerebral tissues. Nonteratoid group has tissue that resemble the medullary epithelium as in our cases but may contain tissue derived from secondary optic vesicle such as retinal pigmented epithelium, ciliary epithelium, vitreous, and neuroglia.⁽²⁾ Malignant transformation should be considered when local invasion, frequent

mitoses, and distant metastases are identified.

To date more than 100 cases of diktyoma have been published, the majority being in the infants and children with an average age of 5 years.^(1,8) In Thailand there are only 3 cases, including our 2 examples, in which medulloepithelioma has been described.⁽²⁾ Both cases in our studies were well within the age range reported by others. There is no sex predilection although our patients were both girls.

The tumor is often congenital and occurs spontaneously without any predisposing factors. On reviewing the literature, only 2 cases including our (case 2) had been found after trauma.⁽¹⁰⁾ The relation between medulloepithelioma and trauma is unclear and could be a coincidental finding.

Clinically, most patients presented with leukocoria, decrease visual acuity, signs of severe inflammation and intraocular mass as noted in our examples. Clinicians should keep this unusual tumor in mind when children present with such clinical

manifestations.

The ultrasonographic findings and CT features were nondiagnostic in our cases. However Orellana et al have reported the correct pre-enucleation diagnosis of medulloepithelioma in a case of an 8-year-old boy, using ultrasonography and cytologic examination of the vitreous aspirate.⁽¹¹⁾ It should be noted that the diagnosis is usually established histologically after the eye is enucleated and our cases are unexceptional. Only infrequently has this neoplasm been diagnosed before surgery.^(11,12) Tissue examination thus is essential for proper diagnosis and also assists the surgeons and the family to predict the prognosis. Enucleation is curative for this benign non-teratoid tumor.

ACKNOWLEDGEMENT

Dr.Vira Kasantikul is in receipt of fund from Chulalongkorn Faculty of Medicine-China Medical Board Scholar Development Fund.

References.

1. Broughton WL, Zimmerman LE. A clinico-pathologic study of 50 cases of intraocular medulloepitheliomas. *Am J Ophthalmol* 1978 Mar;85(3):407-18
2. Kasantikul V, Vatanatumruk B, Rutnin U. Medulloepithelioma (Diktyoma) with Glial differentiation. *J Med Assoc Thai* 1984 Oct;67(10):580-83
3. Fuchs E. Wucherungen und Geschwulste des Ciliarepithels: Albrecht von Graefes. *Arch Ophthalmol* 1908;68:534-87
4. Grinker RR. Gliomas of the retina including the results of studies with silver impregnations. *Arch Ophthalmol* 1931;5:920-35
5. Zimmerman LE. Verhoeff's "terato-neuroma"; a critical reappraisal in light of new observation and current concepts of embryonic tumors. *Am J Ophthalmol* 1971 Dec;72(6):1039-57
6. Anderson SR. Medulloepithelioma of the retina. *Int Ophthalmol Clin* 1962;2(2):483-506
7. Morris AT, Garmer A. Medulloepithelioma involving the iris. *Br J Ophthalmol* 1975 May; 59(5):276-8
8. Reese AB. Medulloepithelioma (Diktyoma) of the optic nerve. *Am J Ophthalmol* 1957 Jul; 44(1):4-6
9. Zimmerman LE, Sobin LH. Histological Typing of Tumors of the Eye and its Adnexa. Geneva:World Health Organization, 1980. 59-60,68-71
10. Shivde AV, Kher A, Jannarkar RV. Diktyoma. *Br J Ophthalmol* 1969 May;53(5):352-3
11. Orellana J, Moura RA, Font RL, Boniuk M, Murphy D. Medulloepithelioma diagnosed by ultrasound and vitreous aspirate: electron microscopic observation. *Ophthalmology* 1983 Dec; 90(12):1531-39
12. Apt L, Heller MD, Moskovitz M, Foos RY. Diktyoma (embryonal medulloepithelioma) : recent review and case report. *J Pediatr Ophthalmol* 1973 Feb;10(1):30-8