

9-1-2016

Ichthyosis congenita in a calf: Case report

Saeed Azimpour

Farhang Sasani

Parham Mottaghian

Amin Anoushepour

Follow this and additional works at: <https://digital.car.chula.ac.th/tjvm>



Part of the [Veterinary Medicine Commons](#)

Recommended Citation

Azimpour, Saeed; Sasani, Farhang; Mottaghian, Parham; and Anoushepour, Amin (2016) "Ichthyosis congenita in a calf: Case report," *The Thai Journal of Veterinary Medicine*: Vol. 46: Iss. 3, Article 20. Available at: <https://digital.car.chula.ac.th/tjvm/vol46/iss3/20>

This Report is brought to you for free and open access by the Chulalongkorn Journal Online (CUJO) at Chula Digital Collections. It has been accepted for inclusion in The Thai Journal of Veterinary Medicine by an authorized editor of Chula Digital Collections. For more information, please contact ChulaDC@car.chula.ac.th.

Ichthyosis congenita in a calf: Case report

Saeed Azimpour^{1*} Farhang Sasani² Parham Mottaghian³ Amin Anoushepour⁴

Abstract

The purpose of this report was to present the clinical and pathological features of ichthyosis congenital observed in a cross-bred Holstein calf. The calf showed regions of alopecia and moderately thickened, fissured skin at birth. The major dermatopathological feature was diffuse lamellar orthokeratotic hyperkeratosis with severe multiple follicular keratosis along with mild acanthosis. The definitive diagnosis was based on history, physical examination, and dermatopathological findings.

Keywords: ichthyosis congenita, orthokeratotic hyperkeratosis, calf

¹Department of Clinical Science, Faculty of Veterinary Medicine, Babol Branch, Islamic Azad University, Babol, Iran

²Department of Pathology, Faculty of Veterinary Medicine, University of Tehran, Tehran, Iran

³DVM, DVSc, Faculty of Veterinary Medicine, University of Tehran, Tehran, Iran

⁴Department of Clinical Science, Faculty of Veterinary Medicine, Science and Research Branch, Islamic Azad University, Tehran, Iran

*Correspondence: saeed.azimpour@gmail.com

Introduction

Ichthyosis consists of a heterogeneous group of hereditary disorders of keratinization. The name is derived from the Greek word for fish because of the fish scale-like appearance of the hyperkeratotic skin. Ichthyosis in animals is a rare congenital condition that has been reported in cattle, dogs, pigs, chickens, laboratory mice, and a llama (Ginn et al., 2007; Scott, 2007).

Two forms of ichthyosis have been described in various breeds of cattle, ichthyosis fetalis and ichthyosis congenita. Both are caused by single autosomal recessive genes. However, the underlying molecular defect(s) is unknown, and it is uncertain whether the forms are distinct diseases or merely represent variations in expression of a single abnormality. Ichthyosis fetalis is the more severe and lethal form. Affected calves are dead at birth or die shortly after birth. Ichthyosis congenita is the milder form of the disease and lesions are more localized (Ginn et al., 2007; Scott, 2007; Raoofi et al., 2001; Testoni et al., 2006; Molteni et al., 2006).

In this report, the clinical and pathological features of ichthyosis congenita in a clinical field case were described.

Case History

In June 2015, a three-day-old Holstein native cross female calf with diffuse hyperkeratosis was presented to the Veterinary Educational Hospital of Islamic Azad University of Karaj, Alborz province, Iran. The calf was full-term and had been born to a normal first-calf heifer with a degree of dystocia. The calf was laterally recumbent and unable to stand, but the vital signs were in normal ranges. Except for the presence of regions of alopecia and moderately thickened and fissured skin, no other gross anatomical abnormality was observable. The clinical signs were progressive. The severity of skin lesions increased significantly in two weeks. The skin covering the limbs, ventral body parts, face, eyelids and pinnae was affected. However, the face, eyelids and pinnae were the most severely affected areas. The skin of affected areas was severely inelastic; restricted the normal movements of the calf (Fig 1).

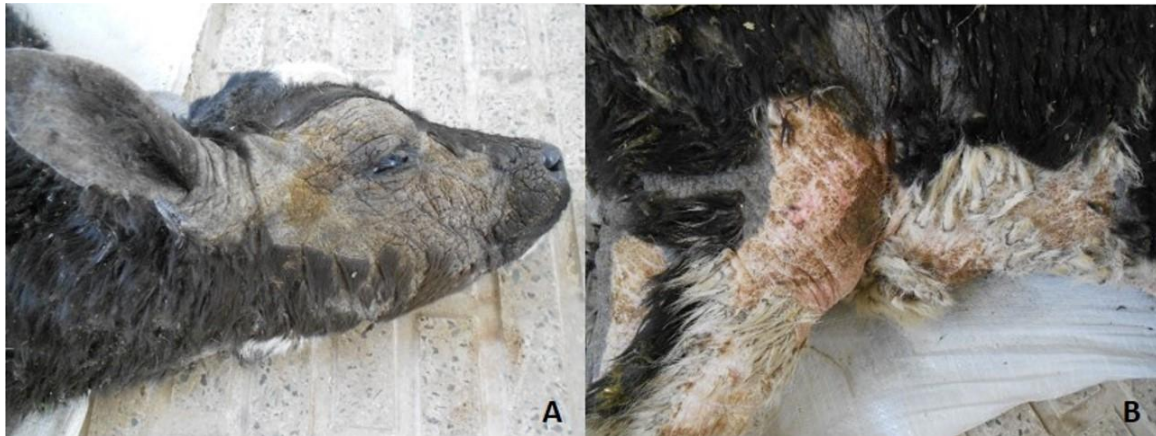


Figure 1 Alopecia, thickening and fissuring of skin covering **A.** face and auricle. **B.** limbs and ventral abdomen

The lesions should have been differentiated from vitamin C responsive dermatosis, hereditary zinc deficiency (hereditary parakeratosis), and skin lesions associated with hypothyroidism.

Blood samples were taken from jugular vein. Complete blood count, total plasma protein, plasma levels of ascorbic acid (vitamin c), and serum zinc concentration were assessed. Serum concentrations of Thyroid hormones (total T4 and T3) were also evaluated. Skin biopsy specimens were also obtained surgically from different affected regions.

As a result, the complete blood count values and WBC differentials were normal. The total plasma protein, plasma levels of ascorbic acid (vitamin c), and serum zinc concentration were in normal range (6.2 g/dL, 16 μ mol/L (reference interval: 9-18 μ mol/L) and 0.29 mg/dL (reference interval: 0.24-0.38 mg/dL), respectively). The total T4 and T3 measured 53 nmol/L (normal range: 55 \pm 7.7 nmol/L) and 1.8 nmol/L (normal range: 1.6 \pm 0.7), respectively. Results of yeast and mold cultures, along with direct microscopic examination of the skin scrapings, were negative.

Finally, due to poor prognosis for recovery and improvement, the calf was humanely euthanized. Necropsy examination revealed no gross anatomical malformation of internal organs. Samples from the skin, thyroid gland, and other internal organs were obtained, formalin-fixed and prepared for light microscopic examination.

The major histopathological feature was severe diffuse lamellar orthokeratotic hyperkeratosis with severe multiple follicular keratosis, mild acanthosis, alopecia with many small-sized hairless follicles or follicles with very small diameter of hairs (Fig 2). No important inflammatory cells were observed. The skin was infiltrated with a rare number of lymphocytes and histocytes, but there was no pattern of dermatitis. However, some parts of the epidermis indicated secondary bacterial pustule formation. Sebaceous glands were low in number and size. Number of sweat glands was more than normal. Dermis and hypodermis were not normal in their tissue structures.

Grossly, the thyroid gland was normal in appearance, size and weight. Microscopically,

although the thyroid follicles were of variable sizes and shapes containing varying amounts of colloids, in general the thyroid structure was normal. A few number of follicles showed purulent inflammation. Gross appearance of all the internal organs was normal. Microscopically, the liver showed very mild

vascular degeneration, which might be a result of fatty change. Tissue structure of other internal organs was normal.

Final diagnosis of this case was "ichthyosis congenita" which was made based on the history, clinical presentation, histopathological findings.

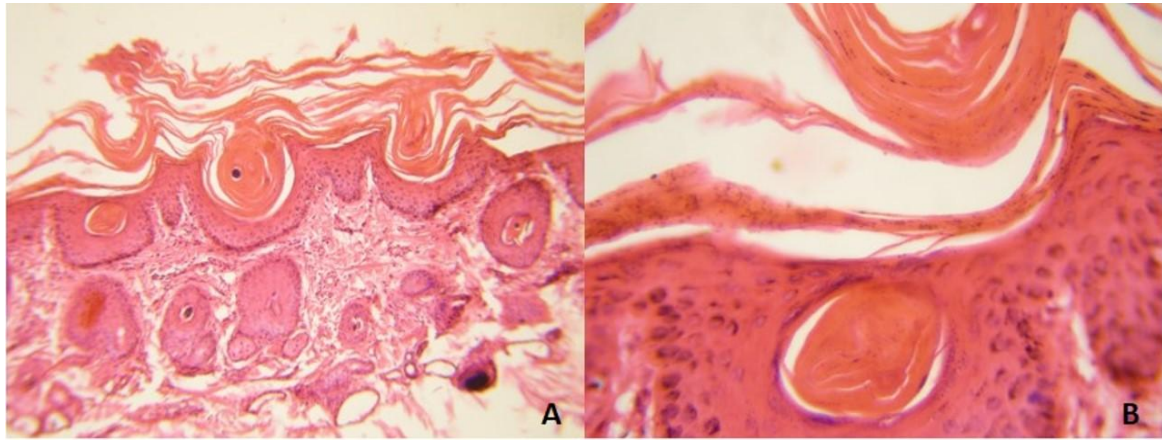


Figure 2 Severe lamellar orthokeratotic hyperkeratosis in the epidermis. **A.** Low magnification **B.** High magnification

Discussion

The definitive diagnosis of ichthyosis congenita in this case was based on the history, physical examination, and dermatopathological findings. Ichthyosis congenita has been reported in Jerseys, Pinzgauer, Chianina and Holstein-Friesians. Hyperkeratosis is present at birth or develops in the first week of life, and is mainly restricted to some particular areas such as the abdomen, the inguinal region, the muzzle and joints. Hairlessness is not an initial feature, but alopecia may develop. The basic defect is increased adherence of keratinocytes, which prevents normal desquamation. The condition is characterized histologically by prominent laminated orthokeratotic hyperkeratosis of the epidermis and superficial portion of hair follicles. The epidermal surface is wrinkled or folded, and acanthosis is variable. There is diffuse sebaceous gland atrophy. Many apocrine glands are ectatic and lined by attenuated epithelium. This condition may be associated with microtia, cataracts and thyroid abnormalities (Baker and Ward, 1985; Hargis and Ginn, 2007; Raoofi et al., 2001; Testoni et al., 2006; Molteni et al., 2006).

Biopsies offer the most valuable information in alopecic diseases if clinical findings are not sufficient to pinpoint the disease. The major histopathological feature in this case was diffuse lamellar orthokeratotic hyperkeratosis (thickening of the cornified layer without retained nuclei). The sebaceous glands were also atrophic (low in number and size). The number of sweat glands was more than usual. The condition should be differentiated from vitamin C responsive dermatosis, hereditary zinc deficiency, and skin lesions associated with hypothyroidism.

Dermatopathological findings of vitamin C responsive dermatosis include orthokeratotic hyperkeratosis, curled hairs, vascular dilation and congestion, and periaxial hemorrhage. The disorder is seen in dairy calves 2 to 10 weeks of age. Affected

calves show moderate to severe scaling, alopecia, occasional crusts, and easy epilation of hairs beginning on the head or limbs. Pruritus and pain are absent and the extremities are usually erythematous and purpuric (Anooshepour et al., 2013; Ginn et al., 2007; Scott, 2007). The most important pathological features in hereditary zinc deficiency are marked diffuse parakeratotic hyperkeratosis (thickening of the cornified layer by retention of nuclei) and lymphoeosinophilic inflammatory. In addition, the condition normally begins with depression, diarrhea, and skin lesions when calves are 4-8 weeks of age. Conjunctivitis, rhinitis, bronchopneumonia, and other infections are common because of immune dysfunction. Untreated calves usually die 4-8 weeks after the onset of clinical disease (Anand et al., 2005; Ginn et al., 2007; Scott, 2007). In the case presented in this study, the major histopathological finding, as mentioned earlier, was diffuse lamellar orthokeratotic hyperkeratosis. The skin lesions were apparent at birth, progressive and not pruritic. The calf was also not deficient in vitamin C and zinc. Consequently, C-responsive dermatosis and zinc-responsive dermatitis were ruled out in this case.

Orthokeratotic hyperkeratosis, follicular keratosis, diffuse dermal mucinous degeneration (myxedema) and dermal thickening were reported in hereditary hypothyroidism in Afrikaner cattle and merino sheep which produced symmetric hypotrichosis and thick, myxedematous, wrinkled skin (Ginn et al., 2007). Thyroid abnormalities were also reported in cases of ichthyosis in calves (Raoofi et al., 2001; Testoni, 2006). In the presented case, variable sizes and shapes of the thyroid follicles were microscopically observed, however, the general thyroid structure was normal. The total T4 and T3 were also within the normal range. Reference intervals for T4 and T3 have not been reported for neonatal calves. However, based on the results obtained by a recent study, mean \pm standard deviations of T4 and T3 in healthy newborn calves were 55 ± 7.7 nmol/L and 1.6 ± 0.7 nmol/L, respectively (Hajimohammadi et al.,

2015). Therefore, based on the histopathological findings and hormone levels, thyroid gland function abnormality was not confirmed in the presented case.

References

- Anand KJ, Srinivas CL, Sing D, Kumar H, Dhoolappa SM. 2005. Zinc deficiency in two calves. *Indian Veterinary Journal*. 82(7): 768-769.
- Anoushepour A, Sakha M, Mortazavi P. 2013. Vitamin C-responsive dermatosis in a Holstein native cross bull calf. *Turk J Anim Sci*. 37: 234-237.
- Baker JR, Ward WR. 1985. Ichthyosis in domestic animals: a review of the literature and a case report. *Br Vet J*. 141: 1-8.
- Ginn PE, Mensett JEKL and Rukich PM. 2007. Skin and appendages. In: Jubb, Kennedy and Palmer's *Pathology of Domestic Animals: 3-Volume Set (Vol. 1)*. 5th ed. M. Grant Maxie (ed). Saunders Ltd. 556-780.
- Hargis AM, Ginn PE. 2007. The integument. In: *Pathologic Basis of Veterinary Disease*. 4th ed. MD McGavin, JF Zachary (eds). St. Louis, MO: Mosby Elsevier 1229-1230.
- Hajimohammadi A, Roshan-Ghasrodashti A, Forouzes M, Saeb M. 2015. A survey on relationships between thyroid hormone levels and clinical findings in dairy calf diarrhea. *Veterinary Science Development* 5: 5835.
- Raofi A, Mardjanmehr SH, Nekoei SH. 2001. Ichthyosis in a calf in Iran. *Vet Rec*. 149: 563.
- Scott WD. 2007. Congenital and Hereditary Skin diseases. In: *Color Atlas of Farm Animal Dermatology*. WD Scott (ed) Ames, Iowa: Blackwell 60-68.
- Testoni S, Zappulli V, Gentile A. 2006. Ichthyosis in two Chianina calves. *Dtsch Tierarztl Wochenschr*. 113: 351-354.

บทคัดย่อ

รายงานสัตว์ป่วย: ภาวะ Ichthyosis congenita ในลูกวัว

ซาอิด อาซิมพัว^{1*} ฟาแหง ซีซานี² ปาหาม มอทธาเกียน³ อมิน อนูชาพัว⁴

รายงานสัตว์ป่วย ลักษณะทางคลินิกและพยาธิวิทยาของภาวะ ichthyosis congenital ในลูกวัวพันธุ์ผสมโฮสไตน์ ลูกวัวแสดงอาการขนร่วง ผิวหนังหนาตัวและย่นแตก ผลทางจุลพยาธิวิทยาของผิวหนัง พบการกระจายตัวของ lamellar orthokeratotic hyperkeratosis ร่วมกับ follicular keratosis ชนิดรุนแรงเป็นจุดและ acanthosis ระดับอ่อน สรุปลผลการวินิจฉัยโรคอาศัยข้อมูลจากประวัติ การตรวจร่างกายและผลทางจุลพยาธิวิทยา

คำสำคัญ: Ichthyosis congenital orthokeratotic hyperkeratosis ลูกวัว

¹ภาควิชาคลินิกวิทยา คณะสัตวแพทยศาสตร์ มหาวิทยาลัยอิสลามอาซาด เมืองแบโบ ประเทศอิหร่าน

²ภาควิชาพยาธิวิทยา คณะสัตวแพทยศาสตร์ มหาวิทยาลัยเตหะราน เมืองเตหะราน ประเทศอิหร่าน

³นักศึกษาคณะสัตวแพทยศาสตร์ มหาวิทยาลัยเตหะราน เมืองเตหะราน ประเทศอิหร่าน

⁴ภาควิชาคลินิกวิทยา คณะสัตวแพทยศาสตร์ แผนกวิทยาศาสตร์และวิจัย มหาวิทยาลัยอิสลามอาซาด เมืองเตหะราน ประเทศอิหร่าน

*ผู้รับผิดชอบบทความ E-mail: saeed.azimpour@gmail.com