

6-1-2016

Urethral Rupture and Leakage Following Prolonged Surgical Removal of Urethral and Bladder Stones by Episiotomy and Urethrotomy in Female Asian Elephant (*Elephas Maximus*) : A Case Report

Nikorn Thongtip

Benchapol Lorsunyaluck

Manakorn Sukmak

Sirinart Chaichanathong

Pornchai Sunyathiseree

Follow this and additional works at: <https://digital.car.chula.ac.th/tjvm>



Part of the [Veterinary Medicine Commons](#)

Recommended Citation

Thongtip, Nikorn; Lorsunyaluck, Benchapol; Sukmak, Manakorn; Chaichanathong, Sirinart; and Sunyathiseree, Pornchai (2016) "Urethral Rupture and Leakage Following Prolonged Surgical Removal of Urethral and Bladder Stones by Episiotomy and Urethrotomy in Female Asian Elephant (*Elephas Maximus*) : A Case Report," *The Thai Journal of Veterinary Medicine*: Vol. 46: Iss. 2, Article 18.

Available at: <https://digital.car.chula.ac.th/tjvm/vol46/iss2/18>

This Report is brought to you for free and open access by the Chulalongkorn Journal Online (CUJO) at Chula Digital Collections. It has been accepted for inclusion in The Thai Journal of Veterinary Medicine by an authorized editor of Chula Digital Collections. For more information, please contact ChulaDC@car.chula.ac.th.

Urethral Rupture and Leakage Following Prolonged Surgical Removal of Urethral and Bladder Stones by Episiotomy and Urethrotomy in Female Asian Elephant (*Elephas Maximus*) : A Case Report

Nikorn Thongtip^{1,2,4,5*} Benchapol Lorsunyaluck¹ Manakorn Sukmak³

Sirinart Chaichanathong^{4,5} Pornchai Sunyathitiseree^{1,2}

Abstract

A 46-year-old female Asian elephant (*Elephas maximus*) with an abnormal ballottement mass in the perineal area was presented. The elephant was unable to urinate via the normal tract. Previously, this elephant was treated for urethral and bladder obstruction caused by stones by episiotomy and urethrotomy. Eight months later, post-operative care was completed. At this point, the incision wound completely closed and the elephant could urinate through the normal tract. However, the elephant was then mated with an adult male elephant. Three weeks later, the female showed signs of the perineal ballottement mass and was unable to urinate. Episiotomy and urethrotomy were performed following the previous incision line. After resectioning through the urethra, urine from the urinary bladder flowed through the incision wound and urine scalding was found. Then, daily wound cleaning was conducted for two months. Finally, the surgical wound completely closed and a new urinated tract behind the vulva opening was completely formed.

Keywords: elephant, surgery, urethral rupture

¹Wildlife Unit, Veterinary Teaching Hospital, Kasetsart University, Kamphaeng Saen, Nakorn Pathom 73140, Thailand

²Department of Large Animal and Wildlife Clinical Sciences, Faculty of Veterinary Medicine, Kasetsart University, Kamphaeng Saen, Nakorn Pathom 73140, Thailand

³Department of Farm Resources and Production Medicine, Faculty of Veterinary Medicine, Kasetsart University, Kamphaeng Saen, Nakorn Pathom 73140, Thailand

⁴Center for Agricultural Biotechnology, Kasetsart University, Kamphaeng Saen, Nakorn Pathom 73140, Thailand

⁵Center of Excellence on Agricultural Biotechnology, Science and Technology Postgraduate Education and Research Department Commission on Higher Education, Ministry of Education (AG-BIO/PERDO-CHE), Bangkok 10900, Thailand

*Correspondence: foetnit@ku.ac.th, nthongtip@yahoo.com

Introduction

In elephants, the process of secondary intention healing in the post-operative care of episiotomy wounds is well understood. Almost all elephant episiotomy cases are performed for dystocia correction, and most cases are managed by secondary intention healing (Schaftenaar, 2013; Hermes et al., 2008). However, in one dystocia case in Thailand, the suturing allowed the closing of all layers and led to successful primary intention healing (Thitaram et al., 2006). Our previous report revealed the use of episiotomy and urethrotomy for the removal of stones (Thongtip et al., 2013). In that report, suturing for the closure of all layers was attempted. However, urine obstruction was found few hours following the operation. The elephant showed signs of urine accumulation around the sutures and was restless. Following this, it was decided that all sutures should be cut to allow urine flow. Urine passed through this wound and the elephant recovered from signs of restlessness. After that, the wound was allowed to heal by secondary intention healing and this process took a total of eight months. Finally, the episiotomy wound completely closed and the elephant could urinate via the normal tract. Several factors influence the recurrence of urethral rupture and leakage, including the formation of new stones (Smeak, 2000), urethral infections (Kieves et al., 2011) and stricture of urethra structures (Hawthorne et al., 1998; Stone et al., 1997). Correction is based on the resection of episiotomy, urethrotomy and urethrostomy for urine flow out (Smeak, 2000). However, there have been no reports concerning the correction of urethral rupture and leakage in female Asian elephants (*Elephas maximus*) by using episiotomy and urethrotomy. Therefore, this report described the diagnosis, surgical procedure and post-operative care.

Animal signalments, history taking and physical examination: A 46-year-old female Asian elephant showed signs of an abnormal mass at the perineal area. The elephant was unable to urinate via the normal tract. Estimated weight of the elephant was 3,000 kg. The elephant's body temperature was 99°F. Pulse rate was 35 beats per minute. Respiratory rate was 8 times per minute. The elephant was admitted to Kasetsart University, Kamphaeng Saen Veterinary Teaching Hospital on April 23, 2014. The perineal mass was separated into two parts along the perineal line. The size of each part was around 20x20 cm. From skin palpation, both masses were ballottement. The masses continued to increase in size and flowed into the lower part (Fig 1). Upon history taking it was found that, previously, in September 2012, this elephant had a urethral stone obstruction removed by episiotomy and urethrotomy. Eight months later, in March 2013, post-operative care was completed. The wound completely closed and the elephant could urinate through the normal tract. However, early in April 2013, the elephant was mated with an adult male elephant. Three weeks later, the female showed signs of perineal ballottement mass and inability to urinate.

Laboratory tests: Pre-operative blood examination via auricular vein puncture was conducted. Hematological profiles, liver enzyme and kidney function were within normal limits.



Figure 1 Perineal urine ballottement after urethra rupture and leakage at the episiotomy and urethrotomy wound

Ultrasonography: Trans-skin ultrasonography (ALOKA; SSD 500 with convex transducer probe; 3.5 MHz) at the abnormal mass was performed. The ultrasound image revealed subcutaneous fluid-like accumulation.

Clinical diagnosis: Clinical diagnosis was based on history background, physical examination and ultrasonography. The urethrotomy wound under the skin rupture was assumed to be a clinical case.

Treatment plans: Due to the lack of information about recurrence of Urethrotomy wound rupture and leakage, an episiotomy for exploration was performed. Then, complete urethrotomy for urine flow was done. Finally, secondary intention wound healing was performed.

Sedation and surgical procedure: An intravenous catheter No. 18, 1.5 inch (NIPRO IV Catheter, Phra Nakhon Si Ayutthaya, Thailand) was inserted into the auricular vein and NSS (Normal Saline 0.9%, General Hospital Products Public Co., Ltd., Pathumthani, Thailand) was given through it. The flow rate was around 2 liters per hour. Sedation was done by administering xylazine hydrochloride 0.04 mg/kg intravenously (Ilium Xylazil-100®, Troy Lab PTY Ltd, Smithfield NSW, Australia). Local anesthetic, sixty ml of 2% lidocaine hydrochloride (Lidocaine 2%, Union Drug Laboratories Ltd., Bangkok, Thailand), was administered by infiltration at the previous incision area, 1 ml per 1 cm². The surgical procedure was started with a 15-cm episiotomy incision. The fusion of

skin-vestibulo-urethral muscles was resected. Urethrotomy towards the releasing of urine was performed. Some released urine was absorbed into subcutaneous tissue and combined with the previous mass. After the operation, the elephant was given yohimbine hydrochloride (Reverzine®, Parnell Lab Pty Ltd, NSW, Australia) 0.125 mg/kg intravenously. Secondary intention wound healing without suturing was applied.

Post-operative care: Daily wound cleaning was done using chlorhexidine scrub (O.R. Scrub, Sinopharm Co. Ltd., Bangkok, Thailand) on the skin and subcutaneous tissue. The urethra was lavaged with clean tap water and 10 liters of NSS using equine stomach tube. Topical nitrofurazone ointment (Bactacin®, Osoth Inter Lab, Bangkok, Thailand) and insect repellent (Negazun®, Bayer CropScience Ltd.) were applied. Systemic control of bacterial infection was also performed by using long acting amoxicillin (Longamox®, Vetoquinol, Lure, France) at a total dose of 7,500 mg/day for 30 days intramuscularly. The total course of antibiotic injections was one month. Phenylbutazone (Butasyl®, Novartis Animal Health, Australia) at a total dose of 9000 mg daily was injected intramuscularly for 5 days. An injectable supplement containing butaphosphan and cyanocobalamin

(Catosal®, Bayer Health Care, Kansas, USA) at a total of 50 ml was intramuscularly administered every 2 days over a 30-day period. The accumulation of urine under the subcutaneous tissue and the urine scalding led to pustular exudates and necrotic tissues around the surgical wound. The necrosis covered the base of the incision line through umbilicus (Fig 2). The wound was then cleaned and the necrotic tissues were removed daily. Then, both necrosis points were pierced through skin in the same way behind the vulva opening and all urine flowed out this way. After the operation, the elephant had good appetite and was able to defecate normally. Two months of wound cleaning and trimming were performed. During the early phases of healing, the elephant urinated through the episiotomy wound. However, the wound healing increased daily. New urine subcutaneous tract under the surgical wound was formed behind the vestibule and vulva. Finally, the surgical wound completely closed and the new tract was completely formed (Fig 3). At present, like other female elephants, the elephant could urinate via the new tract with large amount of urine (Fig 4). However, sometimes, urinary incontinence still occurred and stained the hind limbs of the elephant. Fortunately, her overall health was not affected.



Figure 2 Necrosis following urine scalding through umbilicus

In this report, the rupture and leakage of urethral wound occurred and was corrected. The cause might result from inflammation after natural copulation. However, the inside anatomy and mechanism remain unclear. The attack during breeding might have ruptured the urethral wall. Then, the leaked urine could have accumulated through subcutaneous tissues. The incision through the previous wound line was a benefit to this operation as the urethrotomy leakage area was easily found. In the previous study, urethral canula modified from reused elephant endotracheal tube was inserted to the urethra canal. Although the elephant could urinate via the canula, the fitting of the canula on the perineum was not entirely secured and was later removed unintentionally on the first day when the elephant wagged its tail on the canula. Then, secondary

intention healing without the canula was chosen. Daily wound cleaning and trimming of the necrotic tissues were the key to success of this treatment. Due to the fact that the elephant could not urinate via the normal tract, the formation of new urine tract was initiated. Surprisingly, the control of urination improved and the urinary incontinence was not frequently found. Therefore, the bladder sphincter might not have been affected. However, the monitoring of her condition still continues.

In conclusion, this study has improved our knowledge of the performance and care in the processes of elephant episiotomy and urethrotomy surgery. It is important to protect elephants during the early stage of urinary system wound healing. Moreover, mating could negatively impact this wound healing.

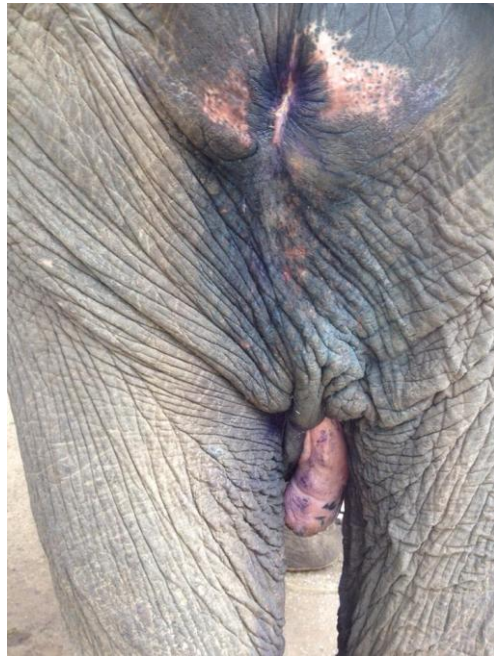


Figure 3 Healing of the episiotomy wound and the new urine tract behind the vulva canal




Figure 4 Urination with large amount of urine via the new tract

Acknowledgement

We would like to thank Mr. Alongkot Chukaew for technical assistance and Dr. Hannah Mumby for editing this manuscript.

References

- Kieves NR, Novo RE and Martin RB 2011. Vaginal resection and anastomosis for treatment of vestibulovaginal stenosis in 4 dogs with recurrent urinary tract infections. *J Am Vet Med Assoc.* 239(7):972-80.
- Hawthorne JC, deHaan JJ, Goring RL, Randall SR, Kennedy FS, Stone E, Zimmerman KM and McAbee SW 1998. Recurrent urethral obstruction secondary to idiopathic renal hematuria in a puppy. *J Am Anim Hosp Assoc.* 34(6):511-4.
- Stone WC, Bjorling DE, Trostle SS, Hanson PD and Markel MD 1997. Prepubic urethrostomy for relief of urethral obstruction in a sheep and a goat. *J Am Vet Med Assoc.* 210(7):939-41.
- Smeak DD 2000. Urethrotomy and urethrostomy in the dog. *Clin Tech Small Anim Pract.* 15(1):25-34.
- Schaftenaar W 2013. Delayed postpartum fetotomy in an Asian elephant (*Elephas maximus*). *J Zoo Wildl Med.* 44(1):130-5.
- Hermes R, Saragusty J, Schaftenaar W, Göritz F, Schmitt DL and Hildebrandt TB 2008. Obstetrics in elephants. *Theriogenology.* 70(2):131-44.
- Thitaram C, Pongsopawijit P, Thongtip N, Angkavanich T, Chansittivej S, Wongkalasin W, Somgird C, Suwankong N, Prachsilpchai W, Suchit K, Clausen B, Boonthong P, Nimtrakul K, Niponkit C, Siritepsongklod S, Roongsri R, Mahasavangkul S 2006. Dystocia following prolonged retention of a dead fetus in an Asian elephant (*Elephas maximus*). *Theriogenology.* 66(5):1284-91.

- Thongtip N, Lorsanyaluck B, Sukmak M, Chaichanathong S, Thengchaisri N, Sunyathitiseree P and Wajjwalku W 2013. Surgical Removal of Urethral and Bladder Stones in Female Asian Elephant (*Elephas maximus*) by Episiotomy and Urethrotomy *Thai J Vet Med.* 43(3): 375-382
- Yartbantoong N, Thongtip N, and Kongsila A 2002. A case report: Dystocia in two elephant. *Kasetsart Veterinarians J.* 12(3): 32-38.

บทคัดย่อ

การฉีกขาดของท่อปัสสาวะและการรั่วไหลภายหลังการผ่าตัดแก้ไขภาวะนิ้วอูตันทางเดินปัสสาวะ

ในช้างเอเชียเพศเมีย (*Elephas maximus*): รายงานสัตว์ป่วย

นิกร ทองทิพย์^{1,2,4,5*} เบลูจพล หล่อสัญลักษณ์¹ มานะกร สุขมาก³

สิรินารถ ชัยชนะทอง^{4,5} พรชัย สัญญูติเสรี^{1,2}

ช้างเอเชียเพศเมียอายุ 46 ปี ได้เข้ารับการรักษาด้วยอาการมีถุงน้ำผิดปกติที่บริเวณฝีเย็บ และไม่สามารถถ่ายปัสสาวะในช่องทางปกติ ก่อนหน้านั้นในเดือนกันยายน ปี 2555 ช้างมีภาวะนิ้วอูตันทางเดินปัสสาวะและกระเพาะปัสสาวะ และได้รับการรักษาด้วยการผ่าตัด episiotomy และ urethrotomy เพื่อล้างเอาก้อนนิ้วออก จากนั้นได้รับการดูแลหลังผ่าตัดเป็นเวลาแปดเดือนจนแผลผ่าตัดปิดสนิท และช้างสามารถปัสสาวะออกทางช่องปกติ อย่างไรก็ตามความทุกข์ได้นำช้างเพศผู้มาผสมพันธุ์ หลังจากนั้นสามสัปดาห์ช้างเพศเมียได้แสดงอาการผิดปกติดังกล่าว และเข้ารับการรักษาโดยการวางยาซึมและผ่าตัดผ่านแผลผ่าตัดเดิมเพื่อหาจุดที่มีการฉีกขาดและปัสสาวะรั่วไหล หลังจากเจอจุดที่รั่วพบว่าปัสสาวะไหลออกทางแผลผ่าตัด และไม่พบปัสสาวะไหลออกทางช่องเปิด vulva ปัสสาวะที่ไหลออกทางแผลผ่าตัดซึมผ่านชั้นใต้ผิวหนังและไหลไปรวมกับปัสสาวะที่รั่วออกมารวมกันที่บริเวณใต้ท้อง ต่อมาเกิดการกีดของปัสสาวะทำให้เกิดเนื้อตายเป็นเนื้องายาว ทำการรักษาแผลทุกวันด้วยการตัดเนื้อตายและล้างแผลเป็นเวลาสองเดือน โดยในช่วงที่ทำแผลนี้ช้างปัสสาวะผ่านแผลตัดทางเดียว การอักเสบและเนื้อตายที่เกิดขึ้นทำให้ต้องสร้างทางออกของปัสสาวะใหม่ด้านหลังช่อง vestibule และ vulva แบบถาวร ปัจจุบันช้างสามารถควบคุมการปัสสาวะได้ อย่างไรก็ตาม ยังพบอาการปัสสาวะกะปริบะปรอย แต่ภาวะดังกล่าวไม่ส่งผลเสียต่อสุขภาพของช้างโดยรวม

คำสำคัญ: การผ่าตัด ช้าง ท่อปัสสาวะฉีกขาด

¹หน่วยสัตว์ป่า โรงพยาบาลสัตว์มหาวิทยาลัยเกษตรศาสตร์กำแพงแสน คณะสัตวแพทยศาสตร์ มหาวิทยาลัยเกษตรศาสตร์ วิทยาเขตกำแพงแสน จ.นครปฐม 73140

²ภาควิชาเวชศาสตร์คลินิกสัตว์ใหญ่และสัตว์ป่า คณะสัตวแพทยศาสตร์ มหาวิทยาลัยเกษตรศาสตร์ วิทยาเขตกำแพงแสน จ.นครปฐม 73140

³ภาควิชาเวชศาสตร์และทรัพยากรการผลิตสัตว์ คณะสัตวแพทยศาสตร์ มหาวิทยาลัยเกษตรศาสตร์ วิทยาเขตกำแพงแสน จ.นครปฐม 73140

⁴ศูนย์เทคโนโลยีชีวภาพเกษตร มหาวิทยาลัยเกษตรศาสตร์ วิทยาเขตกำแพงแสน จ.นครปฐม 73140

⁵ศูนย์ความเป็นเลิศด้านเทคโนโลยีชีวภาพเกษตร สำนักพัฒนาบัณฑิตศึกษาและวิจัยด้านวิทยาศาสตร์และเทคโนโลยี สำนักงานคณะกรรมการอุดมศึกษา กรุงเทพฯ 10900

*ผู้รับผิดชอบบทความ E-mail: fvetnit@ku.ac.th, nthongtip@yahoo.com