

5-1-1990

Thanatoporic dwarfism

Somchai Suwajanakorn

Hathai Theppisai

Wongkulpat Snidvongs

Follow this and additional works at: <https://digital.car.chula.ac.th/clmjournal>



Part of the [Medicine and Health Sciences Commons](#)

Recommended Citation

Suwajanakorn, Somchai; Theppisai, Hathai; and Snidvongs, Wongkulpat (1990) "Thanatoporic dwarfism," *Chulalongkorn Medical Journal*: Vol. 34: Iss. 5, Article 8.

Available at: <https://digital.car.chula.ac.th/clmjournal/vol34/iss5/8>

This Case Report is brought to you for free and open access by the Chulalongkorn Journal Online (CUJO) at Chula Digital Collections. It has been accepted for inclusion in Chulalongkorn Medical Journal by an authorized editor of Chula Digital Collections. For more information, please contact ChulaDC@car.chula.ac.th.

Thanatoporic dwarfism

Somchai Suwajanakorn*

Hathai Theppisai* Wongkulpat Snidvongs*

Suwajanakorn S, Theppisai H, Snidvongs W. Thanatoporic dwarfism. Chula Med J 1990 May; 34 (5) : 377-382

Thanatoporic dwarfism, a lethal form of neonatal dwarfism is a congenital malformation, the cause of which is still not certain. In the past, many cases of thanatoporic dwarfism were confused with achondroplasia and achondrogenesis. Prenatal diagnosis of thanatoporic dwarfism has been achieved by ultrasonography and radiography in the second or third trimester of pregnancy.

A case of thanatoporic dwarfism diagnosed at the early beginning of the third trimester is presented. Early prenatal diagnosis and elective abortion may avoid problems in obstetric management which may occur later in pregnancy.

Reprint request : Suwajanakorn S, Department of Obstetrics and Gynecology, Faculty of Medicine, Chulalongkorn University, Bangkok 10330, Thailand.

Received for publication. February 23; 1990 .

สมชาย สุวจนกรณ์, หะทัย เทพพิสัย, วงศ์กุลพัทธ์ สนิทวงศ์ ณ อยุธยา. ทารกแคระ ธานาโทพอริค. จุฬาลงกรณ์เวชสาร 2533 พฤษภาคม; 34(5): 377-382

รายงานผู้ป่วยตั้งครรภ์ ทารกแคระ ธานาโทพอริค ซึ่งเป็นความพิการแต่กำเนิดที่รุนแรงชนิดหนึ่ง เกี่ยวข้องกับระบบโครงร่างของทารก โดยเฉพาะกระดูกบริเวณ *metaphysis* สาเหตุของความพิการนี้ยังไม่ทราบแน่ชัด ในอดีตทารกแคระชนิดนี้มักจะได้รับ การวินิจฉัยเป็นภาวะความพิการอื่นๆ ซึ่งมีลักษณะคล้ายคลึงกัน เช่น *achondroplasia* หรือ *achondrogenesis* เป็นต้น ทารกเหล่านี้มักจะเสียชีวิตภายในระยะเวลาไม่นานหลังคลอด การให้การวินิจฉัยภาวะความพิการนี้ได้ตั้งแต่ระยะเนิ่น ๆ จะช่วยทำให้การตั้งครรภสิ้นสุดลงเป็นไปได้อย่างปลอดภัย และหลีกเลี่ยงอันตรายของมารดาต่างๆ ที่อาจเกิดขึ้น เนื่องจากการคลอดทารก ธานาโทพอริค ซึ่งมักจะมีภาวะศีรษะโตร่วมด้วย

Thanatophoric dwarfism is one of the severe types of congenital malformation which occurs in the fetal skeletal system at the metaphysis⁽¹⁾. This malformation was first reported by Maroteaux et al in 1967⁽²⁾ using a term derived from Greek which means "death bearing", because neonates afflicted with this type of malformation died a short time after birth⁽³⁾. In the past, this condition had often been misdiagnosed as achondroplasia since the two conditions share very similar features but recently more studies have classified the differences between the two conditions.

Case report

A 26 year old primigravida who lived in Bangkok first attended the antenatal clinic at a Bangkok Metropolitan Administration's Health Centre when she was approximately 11 weeks pregnant but uncertain of the date of the last menstrual period. Physical examination and results of routine laboratory were within normal limits. She had no family history of congenital malfor-

mation nor had her husband who was a 36 year old taxi driver.

Subsequent 4 visits to the antenatal clinic showed slightly less than average weight gain of 1.5 kg. in 4 weeks but normal increase of uterine size until 28 weeks gestation when uterine fundus was at the level of 3/4 above the umbilicus, larger than gestational age with inaudible fetal heart sound.

She was referred to the antenatal clinic at Chulalongkorn Hospital where her fundus was found to be at the level of 3/4 above the umbilicus with a live fetus as confirmed by fetal heart sound auscultation. Her BP was 120/80 and she had no glucose or albumin in her urine. Since she was uncertain of the date of her last menstrual period, ultrasonographic examination was performed to confirm gestational age. A live fetus was found in cephalic presentation with Enlargement of the cerebral ventricle (Figure 1,2), short arms and legs, polyhydramnios and a posterior placenta. An initial diagnosis of hydrocephalus with short limbs and polyhydramnios was made.

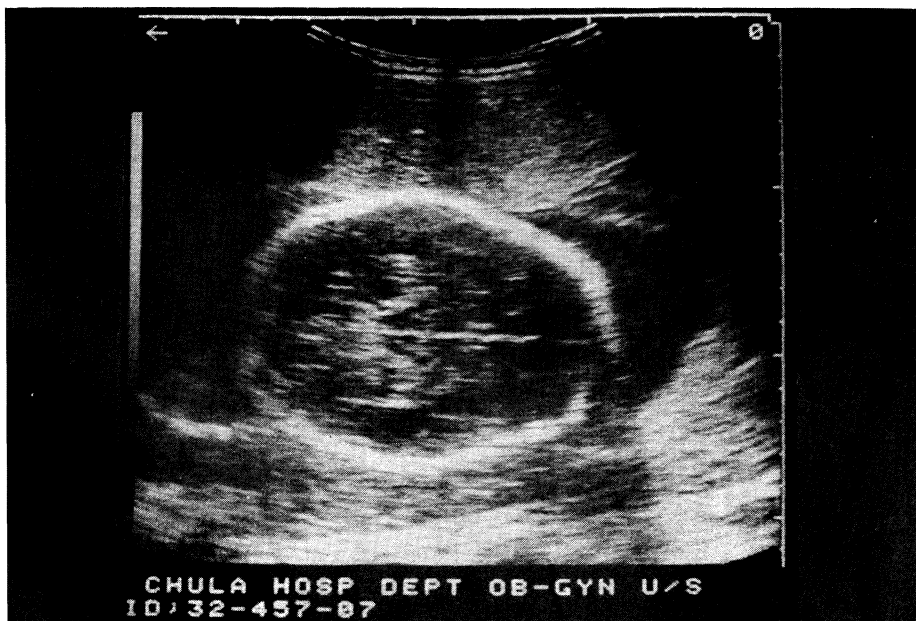


Figure 1. Normal fetal head from ultrasound scanning.

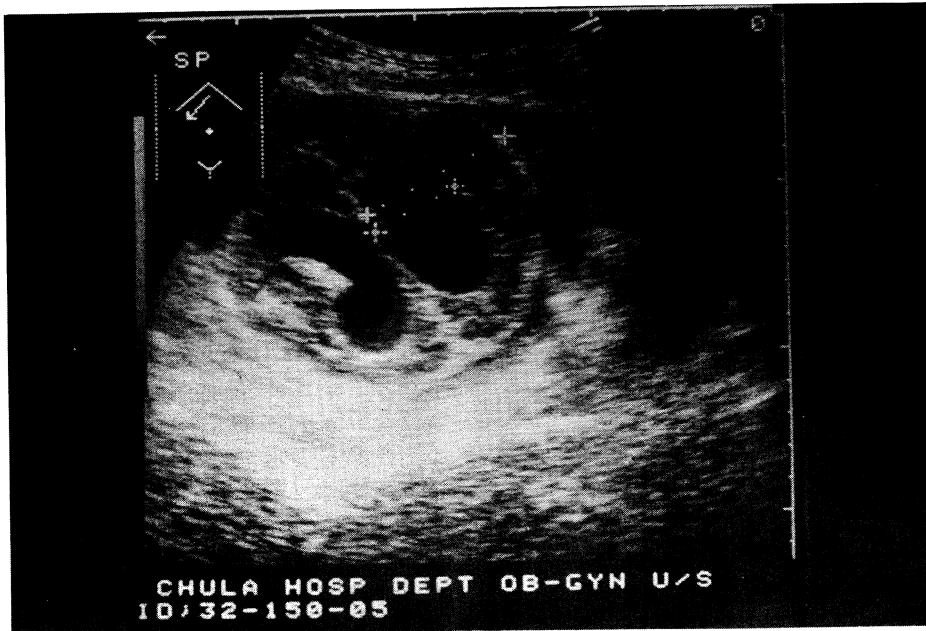


Figure 2. Dilatation of cerebral ventricle in this fetus.

A plain abdomen X-ray 2 weeks later revealed a fetus with short arms and legs and small spinal column (Figure 3). A definitive diagnosis of thanatophoric dwarfism was made. Two weeks later, the patient presented at the labour room with a two hour history of ruptured membrane and one hour later labour occurred spontaneously. Labour progressed uneventfully and she had a normal delivery, of a live female neonate weighing

1,500 G., 8 hours later. The neonate was 34 cm. long with abnormally large head, short arms and legs (Figure 4), a rather small thoracic cage, and survived for only 35 minutes. The normal looking placenta weighed 440 G and the cord was 35 cm. long, unfortunately the placenta and cord were not sent for histopathology. The patient's stay in hospital was uncomplicated and she was discharged 3 days after delivery.

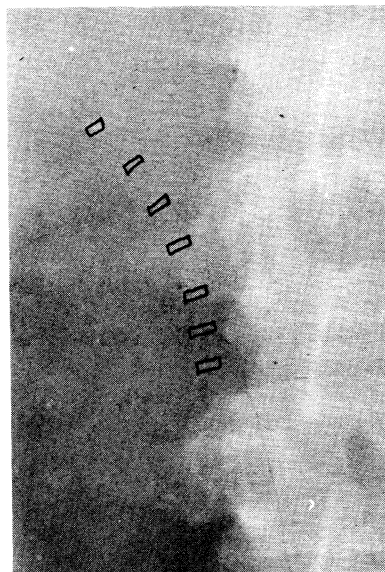


Figure 3. X-ray of fetal spine.

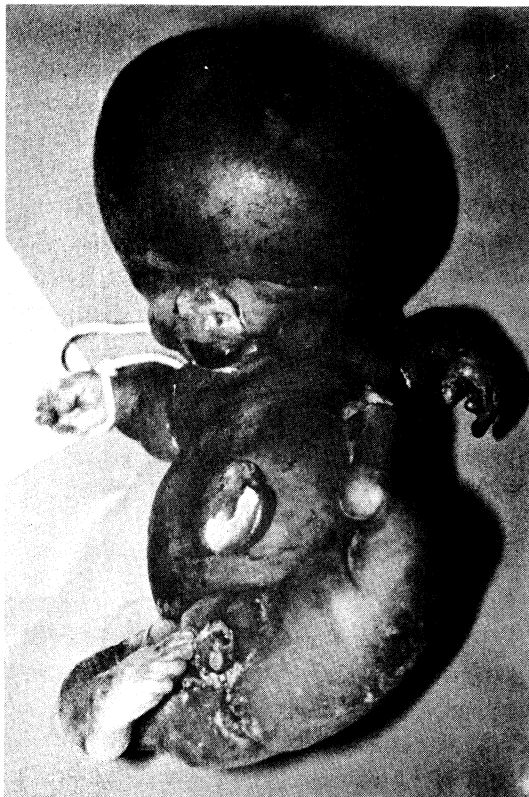

Figure 4. Infant at birth.

Comment

Thanatophoric dwarfism is a type of dwarfism which is incompatible with life and is the most common cause of death in dwarf neonates.⁽⁴⁾ Its aetiology is uncertain and most occurrences are sporadic with male to female sex ratio of 2:1.⁽³⁾ There have, however, been reports of autosomal recessive type of inheritance in 2 offsprings with thanatophoric dwarfism, from consanguineous parents.⁽⁵⁾

Characteristics of thanatophoric dwarfism include micromelia, shortened body, averaging 40 cm. at term. The skull is enlarged with widened fontanelles and small foramen magnum. The skull base is narrow with small face and flattened nasal ridge. The thoracic cage is narrow with short ribs and curved arms and legs. Microscopic examination of the bones reveal that chondrocytes and bony trabeculae alignment are not in an orderly fashion, especially around the central epiphyseal—metaphysis area. The vertebrae are flattened and there are wide intervertebral gaps.^(1,3,4,6)

Prenatal diagnosis can be made using ultrasonography, X-ray, or fetography where some of the above characteristics may be apparent. Occasional difficulties

may be encountered when differentiating this condition from other types of congenital dwarfism such as achondroplasia, achondrogenesis or osteogenesis imperfecta^(1,4) and the final diagnosis will depend on detailed history and above mentioned investigations. In the case of homozygous achondroplasia, both parents will have features of the condition. If one parent is normal, achondroplasia can then be excluded.⁽⁸⁾ In the case of heterozygous achondroplasia, the thoracic cage is not as small and narrow as that of thanatophoric dwarfism whose body is of normal length but with short arms and legs. In the case of achondrogenesis, the body, arms, legs are all short with less than normal ossification in the spinal column, the pelvis and the skull.⁽⁹⁾ In the case of osteogenesis imperfecta, ultrasonography or X-ray will reveal similarly curved arms and legs but there are areas of demineralization of the skull, arms and legs as well as several fracture sites.⁽⁷⁾

Compared with ultrasonography, X-ray has the advantage of more definite imaging of various bones, and ossification centers are better visualized.

Thanatophoric dwarfism is mostly diagnosed during the 3rd trimester⁽¹¹⁾ because the uterine size is larger than average for gestational age, as in this case,

due to the fact that thanatophoric dwarfism is frequently associated with polyhydramnios.⁽¹⁰⁾ Other complications may be found such as abnormal presentation, preterm labour, and cephalopelvic disproportion.

Diagnosis during early pregnancy will mean easy and safe termination of pregnancy by the vaginal route with avoidance of unnecessary abdominal delivery. In a case of near term pregnancy with a breech presentation, the short and rigid neck of thanatophoric dwarfism has limited movement and will lead to difficult delivery of the after coming head with subsequent birth canal injuries if vaginal delivery is attempted.

Prenatal diagnosis of congenital anomalies is therefore advisable especially among those with risk

factors such as history of congenital anomalies in previous pregnancies and elderly gravidae, in order to avoid dangerous complications of pregnancy and delivery as well as psychic trauma to the mothers.

Summary

Thanatophoric dwarfism is a type of congenital malformation which is not compatible with life. Its aetiology is still uncertain, therefore prenatal diagnosis especially using ultrasonography to detect abnormality of fetal limbs, vertebrae and skull in early pregnancy will result in safe and efficient management of these unfortunate gravidae.

References

1. Ghosh A, Woo JSK, Tang LCH, Tang GWK, Wong VCW. Prenatal diagnosis and obstetric management of thanatophoric dwarfism. *Asia-Oceania J Obstet Gynaecol* 1984 Sep; 10(3) : 305-9
2. Maroteaux P, Lamy M, Robert JM. Le nanisme thanatophore. *Presse Med* 1967 Nov 22; 75 : 2519-24
3. Smith DW. *Recognizable Patterns of Human Malformation*. 3rded. Philadelphia : W.B. Saunders, 1982. 242-3
4. Loong EP. The importance of early prenatal diagnosis of thanatophoric dysplasia with respect to obstetric management. *Eur J Obstet Gynecol Reprod Biol* 1987 Jun; 25(2) : 145-52
5. Chemke J, Graff G, Lancet M. Familial thanatophoric dwarfism. *Lancet* 1971 Jun 26; 1(7713) : 358
6. Isaacson G, Blakemore KJ, Chervenak FA. Thanatophoric dysplasia with cloverleaf skull. *Am J Dis Child* 1983 Sep; 137(9) : 896-8
7. Chervenak FA, Romero R, Berkowitz RL. Antenatal sonographic findings of osteogenesis imperfecta. *Am J Obstet Gynecol* 1982 May 15; 143(2) : 228-30
8. Langer LO Jr, Spranger JW, Greinacher I, Herdman RC. Thanatophoric dwarfism. A condition confused with achondroplasia in the neonate, with brief comments on achondrogenesis and homozygous achondroplasia. *Radiology* 1969 Feb; 92(2) : 285-94
9. Smith WL, Breitweiser TD, Dinno N. In utero diagnosis of achondrogenesis, type 1. *Clin Genet* 1981 Jan; 19(1) : 51-4
10. Thompson BH, Parmley TH. Obstetric features of thanatophoric dwarfism. *Am J Obstet Gynecol* 1971 Feb 1; 109(3) : 396-401
11. Fink IJ, Filly RA, Callen PW, Fiske CC. Sonographic diagnosis of thanatophoric dwarfism in utero. *J Ultrasound Med* 1982 Oct; 1(8) : 337-9