

The Thai Journal of Veterinary Medicine

Volume 45
Issue 3 September, 2015

Article 23

9-1-2015

What is Your Diagnosis?

Nan Choisunirachon

Follow this and additional works at: <https://digital.car.chula.ac.th/tjvm>



Part of the [Veterinary Medicine Commons](#)

Recommended Citation

Choisunirachon, Nan (2015) "What is Your Diagnosis?," *The Thai Journal of Veterinary Medicine*: Vol. 45: Iss. 3, Article 23.

Available at: <https://digital.car.chula.ac.th/tjvm/vol45/iss3/23>

This Other is brought to you for free and open access by the Chulalongkorn Journal Online (CUJO) at Chula Digital Collections. It has been accepted for inclusion in The Thai Journal of Veterinary Medicine by an authorized editor of Chula Digital Collections. For more information, please contact ChulaDC@car.chula.ac.th.

What is Your Diagnosis?

Nan Choisunirachon

Signalment

A one-year-old, male, French bulldog.

History

The patient was presented to the Small Animal Teaching Hospital, Chulalongkorn University due to the chief complaint of lameness of both hind limbs for a week. The dog has been given with the parenteral non-steroidal anti-inflammatory drugs and supplementary food; however, the clinical sign was still presented.

Clinical examination

Excepted for the occasionally lameness of the right hind limb, the patient was normal in almost all of

the clinical signs, for example: no evidence of the back pain or the deficit of the urination and defecation, including the absence of spinal reflexes during the physical examination. However, on the orthopedic examination of right hind limb, the grade II - III of medial patella luxation was noted.

Radiographic examination

In addition to the physical and orthopedic examinations which the problem list of the grade II - III of the right medial patella luxation was noted; the patient was additionally subjected to screen the abnormality of lumbar spines by plain radiographs. Both of the ventrodorsal and lateral abdominal radiographic views were taken.

What is your diagnosis?
Please turn to next page for the answer.

Radiographic findings

On the lateral projection of the abdomen (Fig 1), the radiographic silhouette of intra-abdominal organs, for example: gastrointestinal tract, spleen, hepatobiliary system, urinary system and genital system were in the normal limits. However, the osseous structure at the abdomen revealed the congenital extra lumbar spine, the 6th lumbar vertebral

body revealed as the ventral hypoplasia (arrow), and the narrowing intervertebral disc spaces between L5 - L6 and L6 - L7. On the ventrodorsal projection (Fig 2), excepted for the extra lumbar vertebral column, the median hypoplasia of the 6th lumbar vertebral column was detected (arrow).

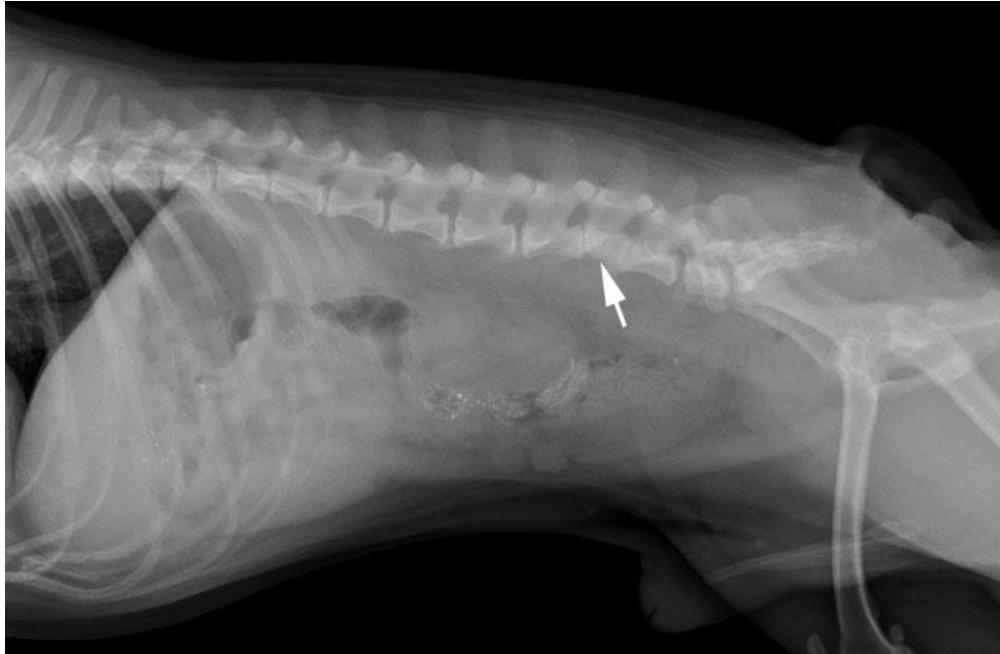


Figure 1 The lateral radiograph of the abdomen revealed that this patient had an extra lumbar vertebral column. Besides, the 6th lumbar vertebral body showed the ventral hypoplasia that caused the ventral wedge shape of the vertebral body (arrow). In addition, there were evidences of the narrowing intervertebral disc spaces between L5 - L6 and L6 - L7.

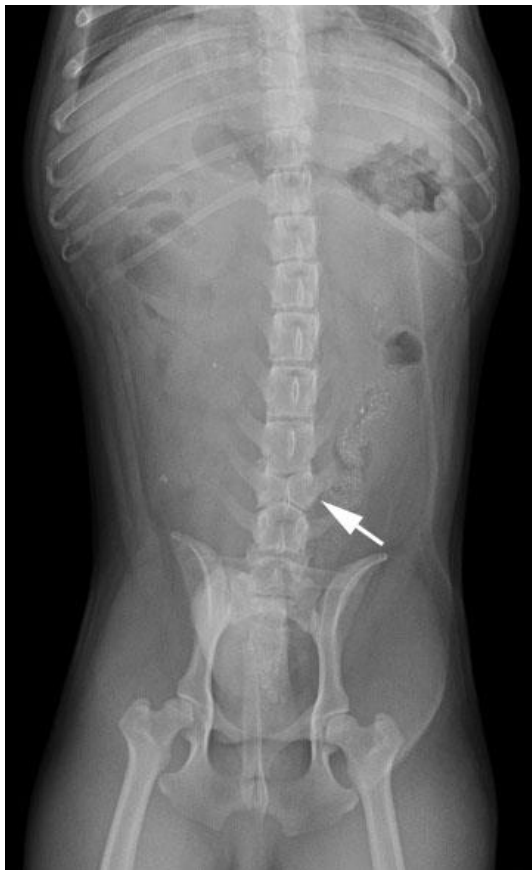

Figure 2 The ventrodorsal abdominal radiograph showed the congenital abnormality of the 6th lumbar vertebral body by the medial hypoplasia that caused that vertebral body represent as the butterfly shape (arrow).

Radiographic diagnosis

Butterfly vertebrae.

Discussion

Congenital vertebral malformations of the spine in dogs were frequently found in the brachycephalic "screw-tailed" dog breeds, for example: English bulldog, French bulldog, Boston terrier or Pug (Gutierrez-Quintana et al., 2014). Besides, it has been reported that the treatment of an infectious-induced struvite urolithiasis by acetohydroxamic acid could cause the teratogenic effects represented by several skeletal anomalies, especially of the spine malformations, in the offspring if the dam has been given the medicine during the onset of proestrus until parturition (Bailie et al., 1986). Congenital vertebral anomalies may appear in various forms, for example: dorsal hemivertebrae (ventral aplasia of the vertebral body), lateral hemivertebrae (lateral aplasia of the vertebral body), dorso - lateral hemivertebrae (ventro - lateral aplasia of the vertebral body), butterfly vertebrae (ventral and medial aplasia of the vertebral body), ventral wedge shape vertebrae (ventral hypoplasia of the vertebral body), and lateral wedge shape vertebrae (lateral hypoplasia of the vertebral body) (Gutierrez-Quintana et al., 2014). Although the radiographic signs were obvious, the evidences of most affected dogs including this patient were reported as the incidental sign without any significantly abnormal

clinical abnormalities. In severe cases, congenital vertebral malformation could cause the stenosis of vertebral canal which resulting in the spinal cord compression. In those cases, the surgical management such as spinal segmental stabilization could provide the satisfactory outcome to patients, especially in the small dogs with hemivertebrae accompanying with mild to moderate neurological deficit (Charalambous et al., 2014).

Reference

- Bailie NC, Osborne CA, Leininger JR, Fletcher TF, Johnston SD, Ogburn PN and Griffith DP 1986. Teratogenic effect of acetohydroxamic acid in clinically normal beagles. *Am J Vet Res.* 47 (12): 2604 - 2611.
- Charalambous M, Jeffery ND, Smith PM, Goncalves R, Barker A, Hayes G, Ives E and Vanhaesebrouck AE 2014. Surgical treatment of dorsal hemivertebrae associated with kyphosis by spinal segmental stabilization with or without decompression. *Vet J.* 202: 267 - 273.
- Gutierrez-Quintana R, Guevar J, Stalin C, Faller K, Yeaman C and Penderis J 2014. A proposed radiographic classification scheme for congenital thoracic vertebral malformations in brachycephalic "screw-tailed" dog breeds. *Vet Radiol Ultrasound.* 55 (6): 585-591.