

9-1-2015

## Case report: Efficacy of Combination of Electroacupuncture and Aquapuncture Using Vitamin B Complex on Promotion of Ambulation Perception in 15 Dogs with Hansen Type I Intervertebral Disc Disease Undergoing Hemilaminectomy

Yu-Chun Cheng

Jian-Liang Lin

Sophia Hsiao-ching Su

Pin-Cheng Shih

Kuan-Sheng Chen

*See next page for additional authors*

Follow this and additional works at: <https://digital.car.chula.ac.th/tjvm>



Part of the [Veterinary Medicine Commons](#)

---

### Recommended Citation

Cheng, Yu-Chun; Lin, Jian-Liang; Su, Sophia Hsiao-ching; Shih, Pin-Cheng; Chen, Kuan-Sheng; Wang, Hsien-Chi; and Lee, Wei-Ming (2015) "Case report: Efficacy of Combination of Electroacupuncture and Aquapuncture Using Vitamin B Complex on Promotion of Ambulation Perception in 15 Dogs with Hansen Type I Intervertebral Disc Disease Undergoing Hemilaminectomy," *The Thai Journal of Veterinary Medicine*: Vol. 45: Iss. 3, Article 18.

Available at: <https://digital.car.chula.ac.th/tjvm/vol45/iss3/18>

This Short Communication is brought to you for free and open access by the Chulalongkorn Journal Online (CUJO) at Chula Digital Collections. It has been accepted for inclusion in The Thai Journal of Veterinary Medicine by an authorized editor of Chula Digital Collections. For more information, please contact [ChulaDC@car.chula.ac.th](mailto:ChulaDC@car.chula.ac.th).

---

**Case report: Efficacy of Combination of Electroacupuncture and Aquapuncture Using Vitamin B Complex on Promotion of Ambulation Perception in 15 Dogs with Hansen Type I Intervertebral Disc Disease Undergoing Hemilaminectomy**

**Authors**

Yu-Chun Cheng, Jian-Liang Lin, Sophia Hsiao-ching Su, Pin-Cheng Shih, Kuan-Sheng Chen, Hsien-Chi Wang, and Wei-Ming Lee

# Case report: Efficacy of Combination of Electroacupuncture and Aquapuncture Using Vitamin B Complex on Promotion of Ambulation Perception in 15 Dogs with Hansen Type I Intervertebral Disc Disease Undergoing Hemilaminectomy

Yu-Chun Cheng<sup>1</sup> Jian-Liang Lin<sup>1</sup> Sophia Hsiao-ching Su<sup>1</sup> Pin-Cheng Shih<sup>1</sup>

Kuan-Sheng Chen<sup>1,2</sup> Hsien-Chi Wang<sup>1,2</sup> Wei-Ming Lee<sup>1,2\*</sup>

## *Abstract*

Fifteen Dachshunds, 6 females and 9 males, aged from 3 to 7.1 years old and weighing from 8.9 to 18.4 kg, were presented with various degrees of paralysis with deep pain on both limbs. The existence of clinical signs was observed by the owners and ranged from 1 to over 7 days. These dogs showed grades of dysfunction ranging from 2 to 5 depending on neurological examination. Hansen type I IVDD was diagnosed in these dogs based on the neurological and imaging examination. Hemilaminectomy was performed on these dogs. Electroacupuncture (using 15-40 Hz on acupoints hua-tuo-jia-ji, GV-14, Bai-hui, KID-1 for 20 mins) was applied 3 days post hemilaminectomy, followed by aquapuncture using vitamin B complex treatment. Five of the fifteen dogs with grade 2 recovered in 7 to 30 days (average 18.6 days) after hemilaminectomy. However, with the combination of hemilaminectomy and electroacupuncture/aquapuncture the recovery time in 3/15 dogs with grade 2 was 12, 18 and 19 days (average 16.3 days), respectively. Therefore, hemilaminectomy combined with electroacupuncture and aquapuncture may be used as a complementary therapy for dogs with IVDD and can shorten the average recovery time, at least, in grade 2 of dysfunction for thoracic and lumbar lesions.

---

**Keywords:** aquapuncture, dog, electroacupuncture, hemilaminectomy, intervertebral disc disease

<sup>1</sup>Veterinary Medical Teaching Hospital, National Chung-Hsing University, 250-1, Kuo Kuang Rd., 402 Taichung, Taiwan

<sup>2</sup>Department of Veterinary Medicine, College of Veterinary Medicine, National Chung-Hsing University, 250, Kuo Kuang Rd., 402 Taichung, Taiwan

\*Correspondence: [wmllee@dragon.nchu.edu.tw](mailto:wmllee@dragon.nchu.edu.tw)

## Introduction

Intervertebral disc disease (IVDD) is caused by degeneration in the cervical or thoracolumbar areas of the spinal column (Schmied et al., 2011). IVDD can be observed from pain during palpation or behavioral change, from back pain to even paralysis of both hind limbs (Sharp and Wheeler, 2005). Apart from neurological examination, the diagnosis of IVDD is based on the observation of image such as myelogram or/and computed tomography (CT) (Schmied et al., 2011; Bibevski et al., 2013). Relief of clinical signs in dogs with IVDD is resort to surgery (Scott, 1997; Scott and McKee, 1999). Acupuncture has been used as a complementary treatment for many years (Buchli, 1975). Recently, electroacupuncture has been used on dogs with intervertebral disc herniation (Han et al., 2010) and aquapuncture has been used on animals such as horses (Luna et al., 2008) and dogs (Shia et al., 2011; Chang et al., 2012). Based on the effect of electroacupuncture and aquapuncture on IVDD, IP maintenance, a combination of the use of

electroacupuncture and aquapuncture, may be beneficial to the recovery time after hemilaminectomy. In aquapuncture, 0.1 ml vitamin B complex is injected into acupoints. Each ml of vitamin B complex consists of thiamine HCl 100 mg, riboflavin 5 mg, pyridoxine HCl 2 mg, niacinamide 50 mg and dexpanthenol 5 mg, and is beneficial to neural activity (Abdollahifard et al., 2014) and myelin formation in nerve cells (Naghashpour et al., 2013). Thus, the purpose of this report was to present the benefit of electroacupuncture/aquapuncture on the promotion of ambulation perception recovery in dogs with IVDD.

## Case History

Fifteen Dachshunds with weakness to paralysis of both hind limbs were presented at Veterinary Medical Teaching Hospital (VMTH), National Chung Hsing University, Taichung, Taiwan. Duration of the occurrence of clinical signs was from 1 day to >7 days (Table 1).

**Table 1** Information, treatment and recovery time of 15 dogs with Hansen Type I IVDD

Dog	Gender (F/M)	BW (Kg)	Age (Years)	Occurrence (Days)	Grade	Treatment	Recovery (Days)
1	F	9.5	7.1	1	3	H+EAQ	30
2	F	13.2	6.5	2	4	H+EAQ	45
3	F	14.2	4.5	3	3	H+EAQ	43
4	F	10.2	4.1	2	2	H+EAQ	18
5	M	12.7	6.3	2	4	H+EAQ	25
6	M	10.5	3.0	1	2	H+EAQ	12
7	M	18.4	6.3	>7	4	H+EAQ	45
8	M	17.5	5.3	2	4	H+EAQ	38
9	M	13.5	6.3	1	2	H+EAQ	19
10	M	17.8	6.1	2	5	H+EAQ	180
11	F	8.9	4.8	2	2	H	21
12	F	16.5	5.2	3	3	H	30
13	F	10.1	6.1	2	2	H	14
14	M	16.7	6.5	2	2	H	7
15	M	17.5	5.7	1	2	H	21

H, hemilaminectomy

EAQ, electroacupuncture and aquapuncture

**Table 2** Grades of dysfunction for thoracic and lumbar lesions\*

Grade	Outcome of neurological examination
1	Pain only
2	Paraparesis-walking
3	Paraparesis-not walking
4	paraplegia
5	Paraplegia with loss of deep pain sensation

\*Small Animal Spinal Disorders, 2<sup>nd</sup> eds, Sharp, N.J.H and Wheeler, S.J. 2005, Elsevier Mosby, USA, 2005, pp. 32.

## Clinical Examination

The dogs presented different degrees of thoracic and lumbar lesions (Sharp and Wheeler, 2005) which were classified as grades 1 to 5 as shown in Table 2. Neurological examination and evaluation were done for each patient before and after hemilaminectomy. Based on confirmed diagnosis (Lorenz et al., 2011<sup>a</sup>), an imaging view of subarachnoid space, for example, was found by x-ray myelogram (Fig 1) or/and computed tomography (CT) (Fig 2). Based on the duration of occurrence, by imaging observation, Hansen type I IVDD was diagnosed in these dogs.

## Methods of Treatment

The dogs received normal procedure of hemilaminectomy as previously described (Seim, 2007). Tramotor<sup>®</sup> (0.2 mg/kg, CRI) was given for pain management for 3 days after the surgery. Three days after the operation, we stimulated acupoints Hua-tuo-jia-ji (located on the dorsal lateral region of the back 0.5 cun lateral to the dorsal spinous process of each vertebrae from T1 to L7), GV-14 (Da-zhui, located on the midline in the depression in front of the dorsal spinous process of the T1 vertebrae), Bai-hui (located

on the dorsal midline between L7 and S1 vertebrae), and KID-1 (Yong-quan, located on the volar side of the pelvic limb between the third and fourth metatarsals underneath the central pad ) by electroacupuncture (low frequency therapeutic device, HC-0601,

HOMETECH®, Taiwan, 15-40 Hz for 20 mins) (Figs 3 and 4). Additionally, aquapuncture was performed by using a 1 ml syringe with a 26G specified needle which was 13 mm in length containing vitamin B complex (Tai Yu®, Taiwan, 0.1 ml/point) every other day.

**Table 3** Comparison of average recovery time between H and EAQ treatment in dogs with different degrees of dysfunction of thoracolumbar lesions

	No	Recovery time (Days)	Mean Recovery time (Days)	No of overall recovery	
H <sup>a</sup>	Grade 2	5	7, 14, 21, 21 and 30	18.6 <sup>c</sup>	5/5
H+EAQ <sup>b</sup>	Grade 2	3	12, 18 and 19	16.3 <sup>d</sup>	3/3
	Grade 3	2	30 and 43		2/2
	Grade 4	4	25 to 45	30.5 <sup>e</sup>	4/4
	Grade 5	1	180		1/1

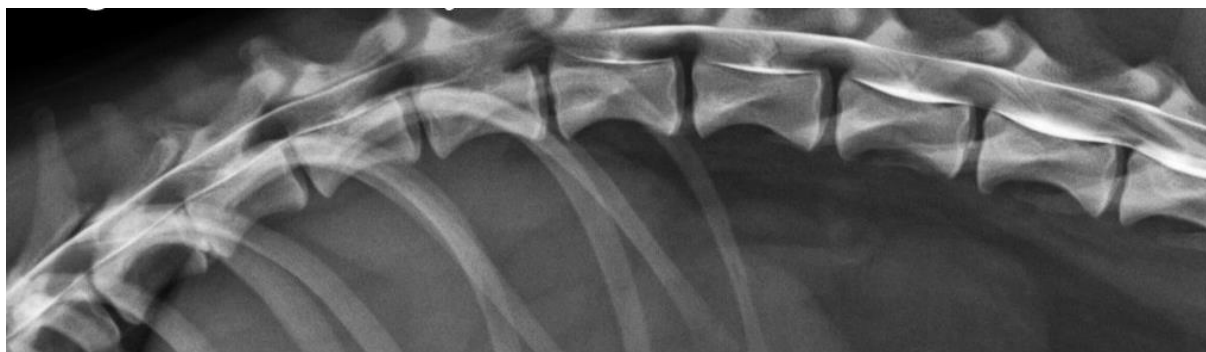<sup>a</sup>hemilaminectomy

<sup>b</sup>hemilaminectomy plus electroacupuncture and aquapuncture

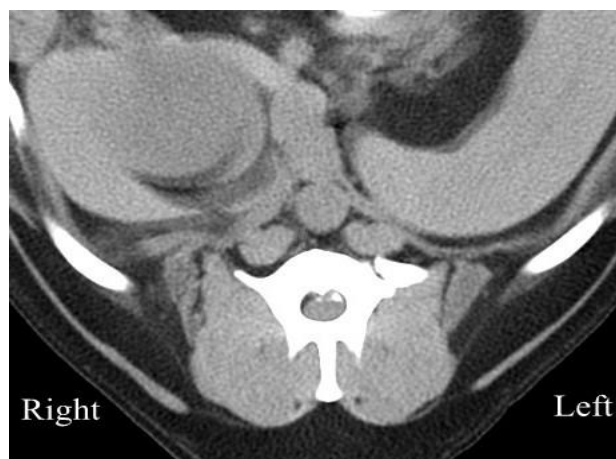<sup>c</sup>average of recovery time of grade 2 after hemilaminectomy treatment

<sup>d</sup>average recovery time of grade 2 after hemilaminectomy plus electroacupuncture and aquapuncture

<sup>e</sup>average recovery time of grades 2, 3 and 4 after hemilaminectomy plus electroacupuncture and aquapuncture



**Figure 1** There is dorsal displacement of the ventral aspect of subarachnoid space, containing contrast medium (white arrow) at T13-L1.



**Figure 2** CT myelography shows the mineralized intervertebral disc herniation (black arrow).

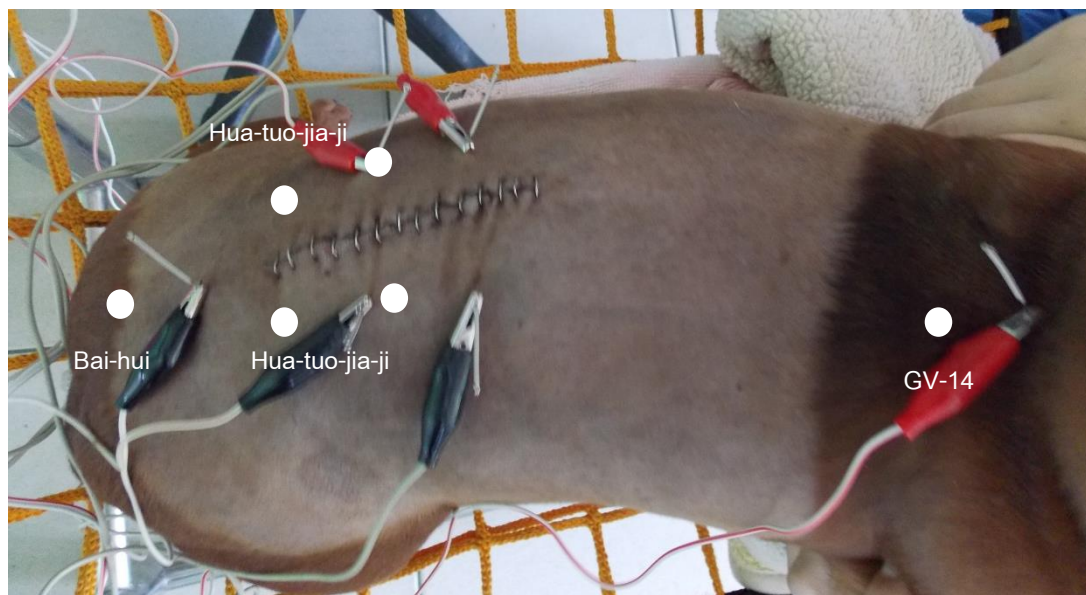
### Results and Discussion

The average number of day for recovery after treatment, the dogs being able to walk on their hind limbs, is shown in Table 3. Results indicated that the average recovery time of the dogs with grade 2 which received hemilaminectomy combined with electroacupuncture and aquapuncture was shorter (16.3 days) than that of the dogs which received only hemilaminectomy treatment (18.6 days). However, there was no significant difference. Normally, the prognosis of hemilaminectomy performance in dogs

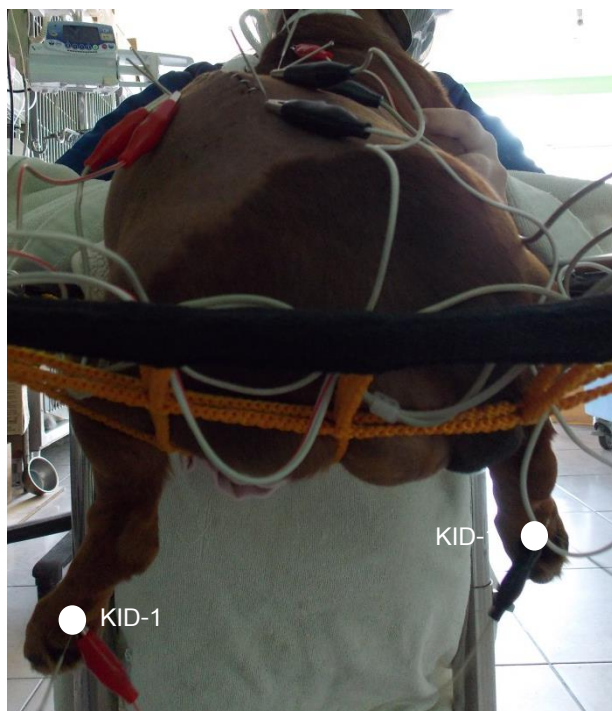with IVDD is based on dogs with or without deep pain (Sharp and wheeler, 2005). Animals should improve within 2 to 3 weeks and significant improvement should be noticed in a month (Lorenz et al., 2011<sup>b</sup>). In this report the length of time for recovery of these dogs positively correlated with the grade; the higher the grade, the longer the time for recovery. In the dogs with grade 4 treated by hemilaminectomy combined electroacupuncture and aquapuncture, the recovery time was 25 to 45 days. In fact, electroacupuncture has been used in dogs with IVDD (Laim et al., 2009; Han et

al., 2010; Shan, 2011). We stimulated acupoints Hua-tuo-jia-ji, GV-14, Bai-hui and KID-1 by electroacupuncture in this report. The attributes and indication of Hua-tuo-jia-ji, GV-1, Bai-Hui and KID-1 have been shown to improve paresis or paralysis of the IVDD by acupuncture (Chrisman and Xie, 2007). After electroacupuncture, vitamin B complex was injected into the acupoints mentioned above. In fact, vitamin B complex has been used in aquapuncture for IOP maintenance (Shia et al., 2011), anus relaxation (Chang et al., 2012) and improvement of unwillingness to walk due to some ingredients of vitamin B complex (Tadano et al., 1995). Each ml of vitamin B complex consists of thiamine HCl 100 mg, riboflavin 5 mg, pyridoxine HCl

2 mg, niacinamide 50 mg and dexpanthenol 5 mg. Thiamine is effective in neural activity (Abdollahifard et al., 2014). Riboflavin is involved in myelin formation in nerve cells (Naghshpour et al., 2013). In addition, positive effect of dexpanthenol on protection of cerebral tissue after ischaemia/reperfusion has been reported (Zakaria et al., 2011). In conclusion, hemilaminectomy combined with electroacupuncture and aquapuncture may be used as a complementary therapy for dogs with IVDD and can shorten the average recovery time, at least, in grade 2 of dysfunction for thoracic and lumbar lesions.



**Figure 3** The view of electroacupuncture used on acupoints GV-14, Hua-tuo-jia-ji and Bai-hui in a Dachshund after hemilaminectomy.



**Figure 4** The view of electroacupuncture used on acupoint KID-1 in a Dachshund after hemilaminectomy.

### Acknowledgements

The authors would like to thank Dr. Chang, Li-Wen for helping us with English critical reading.

### References

- Abdollahifard S, Rahmanian Koshkaki A and Moazamiyanfar R 2014. The effects of vitamin B1 on ameliorating the premenstrual syndrome symptoms. *Glob J Health Sci.* 6(6):144-153.
- Bibeovski JD, Daye RM, Henrickson TD and Axlund TW 2013. A prospective evaluation of CT in acutely paraparetic chondrodystrophic dogs. *J Am Anim Hosp Assoc.* 49(6):363-369.
- Buchli R 1975. Successful acupuncture treatment of a cervical disc syndrome in a dog. *Vet Med Small Anim Clin.* 70(11):1302.
- Chang KM, Chen KS, Wang HC, Lai CH, Hsieh YT, King HH and Lee WM 2012. Combination of acupuncture and aquapuncture using vitamin B complex for treatment of chronic degenerative changes of hip joints and anal relaxation in a dog. *Thai J Vet Med.* 42(1): 387-390.
- Chrisman C and Xie H 2007. Canine classical acupoints. In: *Xie's Veterinary Acupuncture.* H Xie and V Preast (ed) Oxford: Blackwell 217-234.
- Han HJ, Yoon HY, Kim JY, Jang HY, Lee B, Choi SH and Jeong SW 2010. Clinical effect of additional electroacupuncture on thoracolumbar intervertebral disc herniation in 80 paraplegic dogs. *Am J Chin Med.* 38(6):1015-1025.
- Laim A, Jaggy A, Forterre F, Doherr MG, Aeschbacher G and Glardon O 2009. Effects of adjunct electroacupuncture on severity of postoperative pain in dogs undergoing hemilaminectomy because of acute thoracolumbar intervertebral disk disease. *J Am Vet Med Assoc.* 234(9): 1141-1146.
- Lorenz MD, Coates JR and Kent M 2011<sup>a</sup>. Confirming a diagnosis. In: *Handbook of Veterinary Neurology* 5<sup>th</sup> ed MD Lorenz, JR Coates and M Kent (ed) St. Louis: Elsevier 75-94.
- Lorenz MD, Coates JR and Kent M 2011<sup>b</sup>. Pelvic limb paresis, paralysis, or ataxia. In: *Handbook of Veterinary Neurology* 5<sup>th</sup> ed MD Lorenz, JR Coates and M Kent (ed) St. Louis: Elsevier 109-161.
- Luna SP, Angeli AL, Ferreira CL, Lettry V and Scognamillo-Szabó M 2008. Comparison of pharmacopuncture, aquapuncture and acepromazine for sedation of horses. *Evid Based Complement Alternat Med.* 5(3): 267-272.
- Naghashpour M, Majdinasab N, Shakerinejad G, Kouchak M, Haghighizadeh MH, Jarvandi F and Hajinajaf S 2013. Riboflavin supplementation to patients with multiple sclerosis does not improve disability status nor is riboflavin supplementation correlated to homocysteine. *Int J Vitam Nutr Res.* 83(5):281-290.
- Schmied O, Golini L and Steffen F 2011. Effectiveness of cervical hemilaminectomy in canine Hansen Type I and Type II disc disease: a retrospective study. *J Am Anim Hosp Assoc.* 47(5):342-350.
- Scott HW 1997. Hemilaminectomy for the treatment of thoracolumbar disc disease in the dog: a follow-up study of 40 cases. *Journal of Small Animal practice.* 38(11): 488-494.
- Scott HW and McKee WM 1999. Laminectomy for 34 dogs with thoracolumbar intervertebral disc disease and loss of deep pain perception. *Journal of Small Animal practice.* 40(9): 417-422.
- Shan YL 2011. Observation on therapeutic effect of electroacupuncture at Jiaji (EX-B 2) and points of bladder meridian mainly for lumbar disc herniation. *Zhongguo Zhen Jiu.* 31(11): 987-990 (in Chinese).
- Sharp NJH and Wheeler SJ 2005. Thoracolumbar disc disease. In: *Small Animal Spinal disorders* 2<sup>nd</sup> ed NJH Sharp and SJ Wheeler (ed) Elsevier Mosby: 121-159.
- Shia WY, Hsiao YH, Lee MW, Shiu LS, Lin SL and Lee WM 2011. Aquapuncture using vitamin B complex on intraocular pressure in two dogs with cataracts and low intraocular pressure. *Thai J Vet Med.* 41(2): 235-238
- Seim HB 2001. Surgery of thoracolumbar spine. In: *Small Animal Surgery,* TW Fossum (ed) St. Louis: Mosby 1101-1108.
- Tadano T, Asao T, Aizawa T, Sakurada S, Abe Y, Yonezawa A, Ando R, Arai Y, Kinemuchi H and Kisara K 1995. Immunohistochemical determination of rat spinal cord substance P, and antinociceptive effect during development of thiamine deficiency. *Brain Res.* 696(1-2): 21-29.
- Zakaria MM, Hajipour B, Khodadadi A and Afshari F 2011. Ameliorating effects of dexpanthenol in cerebral ischaemia reperfusion induced injury in rat brain. *J Pak Med Assoc.* 61(9):889-892.

## บทคัดย่อ

กรณีศึกษา: ประสิทธิภาพของการฝังเข็มกระตุ้นไฟฟ้าร่วมกับการฉีดวิตามินบีรวมต่อการฟื้นฟูการรับรู้การเคลื่อนไหวในสุนัข 15 ตัวภายหลังการรักษาโรคหมอนรองกระดูกสันหลังแฮนเซนแบบที่ 1 การผ่าตัดตักกระดูกสันหลัง

Yu-Chun Cheng<sup>1</sup> Jian-Liang Lin<sup>1</sup> Sophia Hsiao-ching Su<sup>1</sup> Pin-Cheng Shih<sup>1</sup> Kuan-Sheng Chen<sup>1,2</sup>  
Hsien-Chi Wang<sup>1,2</sup> Wei-Ming Lee<sup>1,2\*</sup>

สุนัขพันธุ์ดัชชุนจำนวน 15 ตัว เพศเมีย 6 ตัว และเพศผู้ 9 ตัว มีอายุระหว่าง 3 ถึง 7.1 ปี และมีน้ำหนักระหว่าง 8.9 ถึง 18.4 กิโลกรัม มาด้วยอาการอัมพาตของสองขาหลังที่ระดับต่างกันและมีความเจ็บปวดแบบลึก เจ้าของสังเกตพบอาการได้ตั้งแต่ 1 วัน หรือมากกว่า 7 วัน สุนัขแสดงความผิดปกติเมื่อทำการตรวจระบบประสาทอยู่ระหว่างระดับ 2 ถึง 5 สุนัขได้รับการวินิจฉัยเป็นโรคหมอนรองกระดูกสันหลังแฮนเซนแบบที่ 1 จากการตรวจระบบประสาทและภาพวินิจฉัย และได้รับการรักษาด้วยการผ่าตัดตักกระดูกสันหลัง ภายหลังการผ่าตัดทำการฝังเข็มกระตุ้นไฟฟ้า (15-40 Hz on acupoints hua-tuo-jia-ji, GV-14, Bai-hui, KID-1 for 20 mins) เป็นเวลา 3 วันและตามด้วยการฉีดวิตามินบีรวม สุนัขจำนวน 5 ใน 15 ตัวซึ่งอยู่ในระดับ 2 พื้นตัวในระยะ 7 ถึง 30 วัน (เฉลี่ย 18.6 วัน) ภายหลังการผ่าตัด อย่างไรก็ตามการผ่าตัดตักกระดูกสันหลังร่วมกับการฝังเข็มกระตุ้นไฟฟ้าและการฉีดวิตามินบีทำให้เวลาฟื้นตัวที่พบในสุนัขจำนวน 3 จาก 15 ตัวซึ่งอยู่ในระดับ 2 เป็น 12 ถึง 19 วัน (เฉลี่ย 16.3 วัน) ดังนั้นจึงอาจใช้การฝังเข็มกระตุ้นไฟฟ้าและการฉีดวิตามินบีเป็นการรักษาเสริมจากการผ่าตัดตักกระดูกสันหลังสำหรับสุนัขที่เป็นโรคหมอนรองกระดูกสันหลัง และสามารถย่นระยะเวลาฟื้นตัว อย่างน้อยสำหรับความผิดปกติระดับ 2 ที่ตำแหน่งอกและเอว

**คำสำคัญ:** การฉีดสารน้ำ สุนัข การฝังเข็มกระตุ้นไฟฟ้า การผ่าตัดตักกระดูกสันหลัง โรคหมอนรองกระดูกสันหลัง

<sup>1</sup>Veterinary Medical Teaching Hospital, National Chung-Hsing University, 250-1, Kuo Kuang Rd., 402 Taichung, Taiwan

<sup>2</sup>Department of Veterinary Medicine, College of Veterinary Medicine, National Chung-Hsing University, 250, Kuo Kuang Rd., 402 Taichung, Taiwan

\*ผู้รับผิดชอบบทความ E-mail: wmllee@dragon.nchu.edu.tw