

1-1-1991

## Acute hemorrhagic pancreatitis due to organophosphate insecticide

Prayong Moolla-or

Teerashoti Chongsakul

Follow this and additional works at: <https://digital.car.chula.ac.th/clmjournal>



Part of the [Medicine and Health Sciences Commons](#)

---

### Recommended Citation

Moolla-or, Prayong and Chongsakul, Teerashoti (1991) "Acute hemorrhagic pancreatitis due to organophosphate insecticide," *Chulalongkorn Medical Journal*: Vol. 35: Iss. 1, Article 6.

DOI: 10.58837/CHULA.CMJ.35.1.6

Available at: <https://digital.car.chula.ac.th/clmjournal/vol35/iss1/6>

This Case Report is brought to you for free and open access by the Chulalongkorn Journal Online (CUJO) at Chula Digital Collections. It has been accepted for inclusion in Chulalongkorn Medical Journal by an authorized editor of Chula Digital Collections. For more information, please contact [ChulaDC@car.chula.ac.th](mailto:ChulaDC@car.chula.ac.th).

## Acute hemorrhagic pancreatitis due to organophosphate insecticide.

Prayong Moolla-or\*  
Teerashoti Chongsakul\*

Moolla-or P, Chongsakul T. Acute hemorrhagic pancreatitis due to organophosphate insecticide. Chula Med J 1991 Jan; 35(1) : 35-41

*A 65 year-old Chinese woman, ingested an unknown amount of Baygon about 2 hours prior to admission. The patient developed anticholinergic inhibitor intoxication which was confirmed by the very low level of exzyme cholinesterase. The organophosphate and carbamate compounds are found in the bile, stomach content and kidneys at necropsy. Acute hemorrhagic pancreatitis was found at necropsy as the very rare complication of organophosphate insecticide.*

Reprint request : Moolla-or P, Department of Forensic Medicine, Faculty of Medicine, Chulalongkorn University, Bangkok 10330, Thailand.

Received for publication. July 13, 1990.

---

\* Department of Forensic Medicine, Faculty of Medicine, Chulalongkorn University.

ประยงค์ มุลลออ, วีระโชติ จองสกุล. ตับอ่อนอักเสบเฉียบพลันแบบมีเลือดออกจากพินัยน้ำแมลง. จุฬาลงกรณ์เวชสาร 2534 มกราคม; 35(1): 35-41

ผู้ป่วยหญิงจีนอายุ 65 ปี มาโรงพยาบาลจุฬาลงกรณ์ โดยมีประวัติว่า ถูกสาวพบว่านอนหมดสติและมีน้ำลายฟูมปาก โดยมีกระป๋องยาฆ่าแมลงใบกอนเขียววางอยู่ข้างๆ ผู้ป่วย ผู้ป่วยได้รับการวินิจฉัยว่าเป็นพิษจากยาฆ่าแมลง และได้รับการยืนยันโดยระดับเอ็นไซม์ *cholinesterase* ในเลือดต่ำมาก ผู้ป่วยได้รับการรักษาตามอาการแต่ถึงแก่กรรมภายหลังอยู่โรงพยาบาลได้ 6 วัน ผลจากการตรวจศพ พบว่าผู้ตายมีตับอ่อนอักเสบแบบมีเลือดออกเฉียบพลัน ซึ่งเป็นผลแทรกซ้อนที่หายากมากของยาฆ่าแมลง *organophosphate* และผลการวิเคราะห์พบยาฆ่าแมลง (*organophosphate* และ *cabamate*) ในน้ำกระเพาะ ไต และน้ำคั่งภายหลังตาย

A 65 year-old Chinese woman, was found unconscious by her daughter about 2 hours prior to admission to emergency room at Chulalongkorn hospital. The daughter also discovered a can of green Baygon beside the patient.

#### Physical examination (Collect from Patient's chart)

A comatose elderly Chinese woman, her pupils

were pinpoint and did not react to light, Doll's eye sign was negative. Pulse rate was 160/min. Her blood pressure was 120/70 mmHg, and her respiration stopped (apnea) few minutes later. The patient also developed diarrhea with watery stool. She did not regain consciousness from the time of her admission until she died 6 days later.

#### Laboratory findings (HD = Hospital day)

	HD1	HD2	HD3
CBC			
Hb (g %)	11.1	16.2	12.9
Hct (vol %)	45	45	60
Wbc (/cumm)	16,700	27,200	10,500
N	70	97	60
band	5	3	36
M	3	-	-
L	22	-	4
platelets	adequate	adequate	adequate

#### Electrolytes

	HD1	HD2	HD3	HD4	HD5	HD6
	4.10 P.M.	8.30 P.M.				
Na (mmol/L)	153	163	168	147	143	140
K (mmol/L)	2.8	4.2	4.3	4.0	3.7	3.5
Cl- (mmol/L)	105	128	135	140	107	108
CO <sub>2</sub>	15	28	16	22	21	20
Blood sugar (mg %)	-	495	346	182	260	165
BUN (mg %)	9	16				
CEA	560/ml					
Ketone	neg					
Serum cholinesterase level (U)	31	-	29	33	56	57

no serum levels of amylase or lipase were done.

#### Arterial blood gases

	pH	pO <sub>2</sub> (mmHg)	pCO <sub>2</sub> (mmHg)	HCO <sub>3</sub> (mmol/L)	CO <sub>2</sub> cont (mmol/L)	BE (mmol/L)	O <sub>2</sub> sat (%)	OCT (vol%)
D2 1.00 am.	7.475	155.2	32.5	15.4	19.4	-5	55	21.1
11.21 am.	7.393	140	33.7	19.9	20.9	35	21	21

### Management in the hospital

The patient was put on Bird's respirator after she began apnea. 2 PAM and atropine as well as Dopamine were also given intravenously. The condition of the patient still deteriorated and she expired after she was in the hospital for 6 days.

Since the patient was dead by violence (suicide or may be accident) the autopsy must be done. (by Law)

### Autopsy findings (performed after death 24 hours)

#### External examination

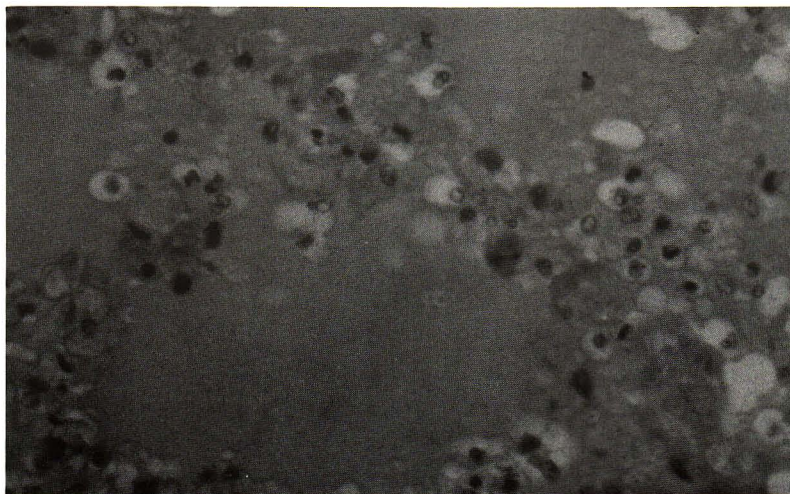
A 65 year old Chinese deceased, her height was 160 centimeters, her weight was 50 kilograms. There was a second degree scalds on the buttocks and tracheotomy on the neck was seen.

#### Internal examination

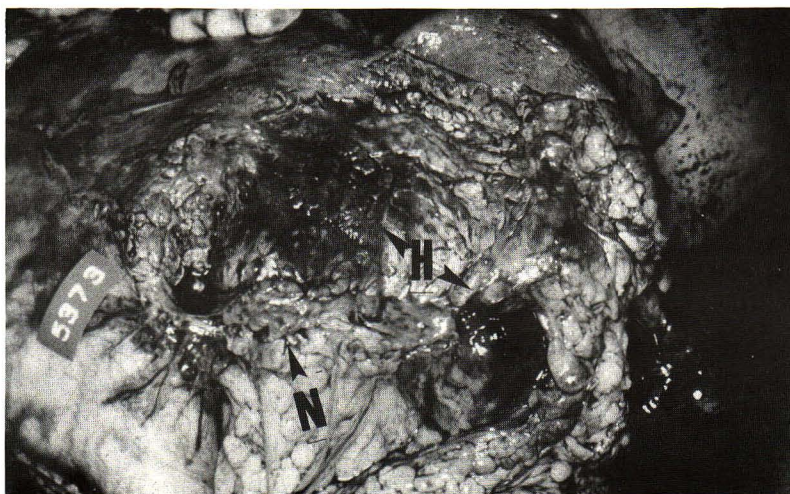Brain weighed 1,330 gm. There were spotty subarachnoid hemeorrhages at the cerebellar region as well as in the pons. The herniations of cerebellar tonsils were also present.

Lungs together weighed 970 grams. There were severe degree of congestions and edema. (Fig. 1)

Abdominal cavity : There was necrosis of mesenteric pad of fat as well as calcium soaps around the pancreatic areas. The pancreas was inflammed; extensive necrotic and frank hemorrhagic areas were present. Also there was about 200 cc. of sero sanguinous fluid in the peritoneum (Fig. 2, 3)

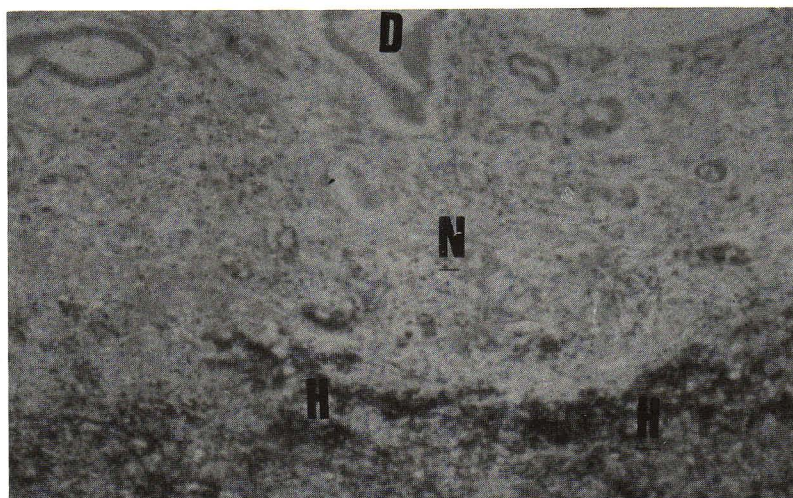


**Figure 1.** Lung shows areas of congestion and edema (H&E  $\times$  400)

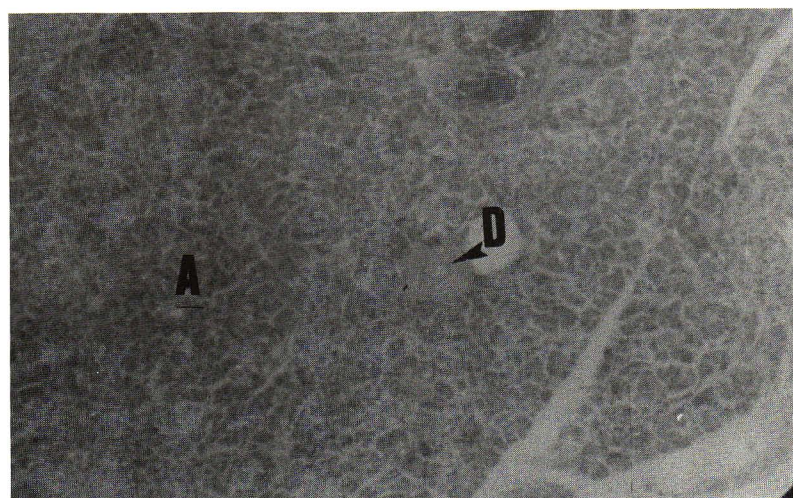


**Figure 2.** Shows gross appearance of the pancreas and tissue around, arrow points at necrotic tissue (N) and hemorrhagic area (H) (extensive)





**Figure 3.** Show microscopic appearance of pancreas, Necrotic area (N) and hemorrhagic area (H) (extensive) (H&E  $\times 100$ ) only ducts remain in the field.



**Figure 4.** Normal microscopic appearance of pancreas pancreatic acini (A), duct (D) is pointed by arrow.

The stomach was dilated and contained coffee-ground color fluid, smelt as insecticide. Similar fluid was found all along the rest of the intestinal tract.

The liver weighed 1480 grams. There was fatty metamorphosis of the liver parenchyma; this was generalized and of moderately severe degree.

Dichlovos (organophosphate) and propoxur (carbamate) were present in the stomach content, kidney and bile on analysis at necropsy.

Blood culture yielded no organism.

## Discussion

Insecticide poisoning, due to ingestion (attempted suicide, homicide, or accident is either by organophosphate compound or carbamate group. The victim or the

patient might show the signs of muscarinic effects, such as profuse sweating, miosis, salivation, respiratory wheezing, stomachache, vomiting and watery diarrhea, bradycardia, blur vision, involuntary urination<sup>(1-13)</sup> etc.

However the nicotinic effects also show, such as fasciculation or cramps then weakness, twitching, finally paralysis of the muscle and respiratory embarrassment, cyanosis and cardiac arrest. This particular case report developed some muscarinic effects such as excessive salivation, miosis, diarrhea and follow by bradycardia, apnea and coma and finally death.

This patient's stomach content smelt of the insecticide following the gastric lavage and also following the necropsy.

Serum cholinesterase level was very low by the

first day (31U.) and still low by the 6th hospital day when she died (57U.). (normal level is 85-135U.). The level of Cholinesterase is used as an indication for the diagnosis and the prognosis of the patient but not for the treatment. (In case the level of serum cholinesterase return to normal the patient might have good prognosis).

Another laboratory finding is hyperglycemia, glycosuria and ketonuria had been reported by Samantray and Permutt,<sup>(14-15)</sup> and they also claimed that anticholinergic agents are effective in the treatment. In this case report, she had hyperglycemia (495-191 mg%) all the time of her hospitalization. They also suggested that it is the direct effect of cholinergic blockade to plasma glucose and insulin response in the normal healthy person.

At the antient time, no body has thought about acute pancreatitis as a complication of the organophosphate insecticide poisoning. The findings of increasing levels of amylase and lipase together with the symptom of muscular cramps were noticed. These findings disappeared after the patient recieved specific and symptomatic treatment for organophosphate insecticide poisoning.

Until the year 1977 Dressel et al<sup>(16)</sup> had reported a first case of acute pancreatitis as a complication of organophosphate insecticide poisoning. Sincethen a few more cases have been reported by Dagli and the other authors<sup>(17-19)</sup>

Later Dressel and other authors<sup>(20-24)</sup> experimented on the effects of atropine on acinar duct together with organophosphate (diazinon) insecticide both of which produced acute pancreatitis in canines. They found pathology of acinar cells of pancreas by light and electron microscope which they can conclude that the pathology occured directly by cholinergic effect and not by ductal hypertension.

Finally Dressel and another authors<sup>(16,22-26)</sup> stated that the cause of acute pancreatitis are many, and not all are well understood, alcoholism, cholelithiasis, hyperparathyroidism, hyperlipidemia, direct trauma, tumors and a growing list of drugs can cause pancreatitis as well as the cholinesterase inhibitors. Even the poison from scorpion can cause acute pancreatitis in man too.<sup>(27-28)</sup> But at least no report about carbamate are associated with acute pancreatitis.

This case report is the first case of acute hemorrhagic Pancreatitis in Thailand (computer searched Medline) and might be the first case in the world which confirmed the diagnosis by autopsy findings. (computer searched Medline)

### Acknowledgements

I wish to thank the ward physicians and the technician (Sirinan) who analyzed the drugs post-mortem.

### References

1. Vale JA, Scott GW. Organophosphorus poisoning. *Guy's Hosp Rep* 1974; 123(1) : 13-25
2. Namba T, Nolte CT, Jackrel J, Grob D. Poisoning due to organophosphate insecticides : acute and chronic manifestation. *Am J Med* 1971 Apr; 50(4) : 475-92
3. Klaassen CD. Non metallic environmental Toxicants : air Pollutants, solvents and vapour and pesticides. In : Gilman AG, Goodman S, Gilman A, eds. *Goodman and Gilman's the Pharmacological Basis of Therapeutics* : 6<sup>th</sup> ed. New York : McMillan Publishing, 1980. 1647-51
4. Haddad LM. The organophosphate insecticides. In : Haddad LM, Winchester JF, eds. *Clinical Management of Poisoning and Drug Overdose*. Philadelphia : W.B. Saunders 1983. 704-40
5. Jiang NS, Fairbanks VF, Hay ID. Pesticided poisoning succinylcholine - induced apnea and pseudocholinesterases. *Mayo Clin Proc Lab Med* 1986; 61 : 750-5
6. Organic phosphorus pesticides. In : Hayes WJ Jr., ed. *Pesticides Studied in Man*. Baltimore : William & Wilkins, 1982. 284-435
7. Davies JE, Barquet A, Freed VH, Haque R, Morgad C, Sonneborn RE, Vaclavek C. Human pesticide poisoning by a fat soluble organophosphate insecticide. *Arch Environ Health* 1975 Dec; 30(12) : 608-13
8. Fiore MC, Anderson HA, Hong R, Golubjatnikov R, Seiser JE, Nordstorm D, Hanrahan L, Belluck D. Chronic exposure to aldicarb-contaminated ground water and human immune function. *Environ Res* 1986 Dec; 41(2) : 633-45

9. Risher JF, Mink FL, Stara JF. The toxicologic effects of the carbamate insecticide aldicarb in mammals : a review. *Environ Health Persp* 1987 Jun; 72 : 267-81
10. Goes EA, Savage EP, Gibbons G, Aaronson M, Ford SA, Wheeler HW. Suspected foodborne carbamate pesticide intoxications associated with ingestion of hydroponic cucumbers. *Am J Epidemiol* 1980 Feb; 111(2) : 254-60
11. Suspected carbamate intoxications - Nebraska Morbid Mortal Weekly Report. *MMWR* 1979 Mar 30; 28(12) : 133-4
12. Baron RL, Casterline JL Jr., Fitzhugh OG. Specificity of carbamate - induced esterase inhibition in mice. *Toxicol Appl Pharmacol* 1964 Jul; 6 : 402-10
13. Haddad LM. The carbamate, organochlorine, and botanical insecticides; insect repellents. In : Haddad LM, Winchester JF eds. *Clinical management of Poisoning and Drug Overdose*. Philadelphia : W.B. Saunders 1983. 711-6
14. Samantray SK. Organophosphate poisoning and remission of diabetes. *Med J Aust* 1978 Apr 22; 1(8) : 443
15. Permutt MA, Keller D, Santiago J. Cholinergic blockade in reactive hypoglycemia. *Diabetes* 1977 Feb; 26(2) : 121-7
16. Dressel TD, Goodale RL Jr., Arneson MA, Borner BA. Pancreatitis as a complication of anticholinesterase insecticide intoxication. *Ann Surg* 1979 Feb; 189(2) : 199-204
17. Dagli AJ, Shaikh WA. Pancreatic involvement in malathion : anticholinesterase insecticide intoxication a study of 75 cases. *Br J Clin Pract* 1983 Jul-Aug; 37(7-8) : 270-2
18. Marsh WH, Yako GA, Corradi EC. Acute pancreatitis after cutaneous exposure to an organophosphate insecticide. *Am J Gastroenterol* 1988 Oct; 83(10) : 1158-60
19. Moore PG, James OF. Acute pancreatitis induced by organophosphate poisoning. *Postgrad Med J* 1981 Oct; 57 : 660-2
20. Dressel TD, Goodale RL Jr, Zweber B, Borner JW. The effect of atropine and duct decompression on the evolution of Diazinon-induced acute canine pancreatitis. *Ann Surg* 1982 Apr; 195(4) : 424-34
21. Singer MV, Solomon TE, Grossman MI. Effect of atropine on secretion from intact and transplanted pancreas in dog. *Am J Physiol* 1980 Jan; 238(1) : G18-22
22. Schmidt DN, Sarles S, Biedzinski TM, Devaux MA. Cholinergic secretory and inhibitory mechanisms in canine pancreatic secretion. *Scand J Gastroenterol* 1981; 16(3) : 341-52
23. Valenzuela JE, Lamers CB, Modlin IM, Walsh JH. Cholinergic component in the human pancreatic secretory response to intraintestinal oleate. *Gut* 1983 Sep; 24(9) : 807-11
24. Valenzuela JE, Weiner K, Saad C. Cholinergic stimulation of human pancreatic secretion. *Dig Dis Sci* 1986 Jun; 31(6) : 615-9
25. Adlakha A, Philli PJ, Dhar KL. Organophosphorus and carbamate poisoning in Punjab. *J Assoc Physicians India* 1988 Mar; 35(3) : 210-2
26. Takahashi M, Maemure K, Sawada Y, Yoshioka T, Sugimoto T. Hyperamylasemia in critically injured patients. *J Trauma* 1980 Nov; 20(11) : 951-4
27. Singer MV, Solomon TE, Grossman MI. Effect of atropine on secretion from intact and transplanted pancreas in dog. *Am J Physiol* 1980 Jan; 238(1) : G18-G22
28. Schmidt DN, Sarles S, Biedzinski TM, Devaux MA. Cholinergic secretory and inhibitory mechanisms in canine pancreatic secretion. *Scand J Gastroenterol* 1981; 16(3) : 341-52