

6-1-2015

## What is Your Diagnosis?

Nan Choisunirachon

Follow this and additional works at: <https://digital.car.chula.ac.th/tjvm>



Part of the [Veterinary Medicine Commons](#)

---

### Recommended Citation

Choisunirachon, Nan (2015) "What is Your Diagnosis?," *The Thai Journal of Veterinary Medicine*: Vol. 45: Iss. 2, Article 22.

Available at: <https://digital.car.chula.ac.th/tjvm/vol45/iss2/22>

This Other is brought to you for free and open access by the Chulalongkorn Journal Online (CUJO) at Chula Digital Collections. It has been accepted for inclusion in The Thai Journal of Veterinary Medicine by an authorized editor of Chula Digital Collections. For more information, please contact [ChulaDC@car.chula.ac.th](mailto:ChulaDC@car.chula.ac.th).

## What is Your Diagnosis?

**Nan Choisunirachon**

### ***Signalment***

A ten-month-old, male, Pit bull dog.

### ***History***

The patient was referred to the Small Animal Teaching Hospital, Chulalongkorn University due to the chief complaints of cruciate ligament rupture induced hind limb lameness for a week since the dog has fallen down from the stairs. The dog has been treated with the parenteral non-steroidal anti-inflammatory drugs, however, the clinical signs were not improved.

### ***Clinical examination***

All clinical signs of the patient were apparently normal. However, the signs of lameness,

swollen of stifle joint and muscle atrophy of the right hind limb were detected. Other orthopedic examinations of the hind limb such as the cranial drawer sign, the tibia compression test, the crepitus sound and ortholani sign were all negative. In addition, all orthopedic examinations of the left hind limb were normal.

### ***Radiographic examination***

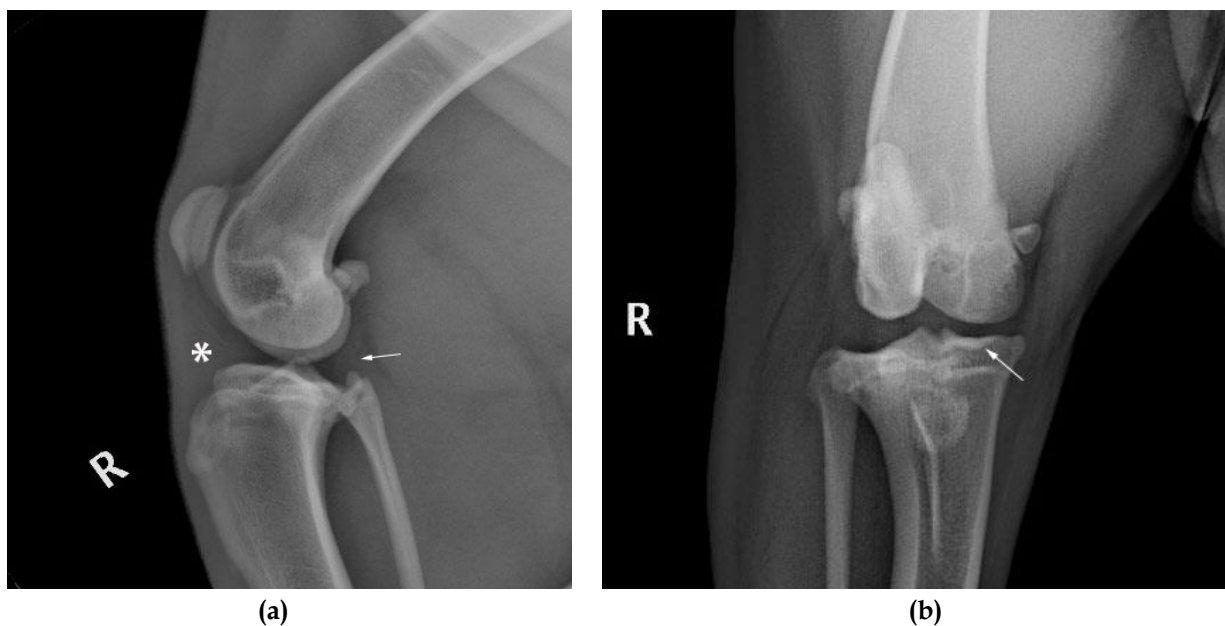
After the clinical and orthopedic examinations, the patient was subsequently subjected to investigate the abnormalities of both stifle joints by plain radiographs. Both of the mediolateral and caudocranial radiographic projections were taken.

What is your diagnosis?  
Please turn to next page for the answer.

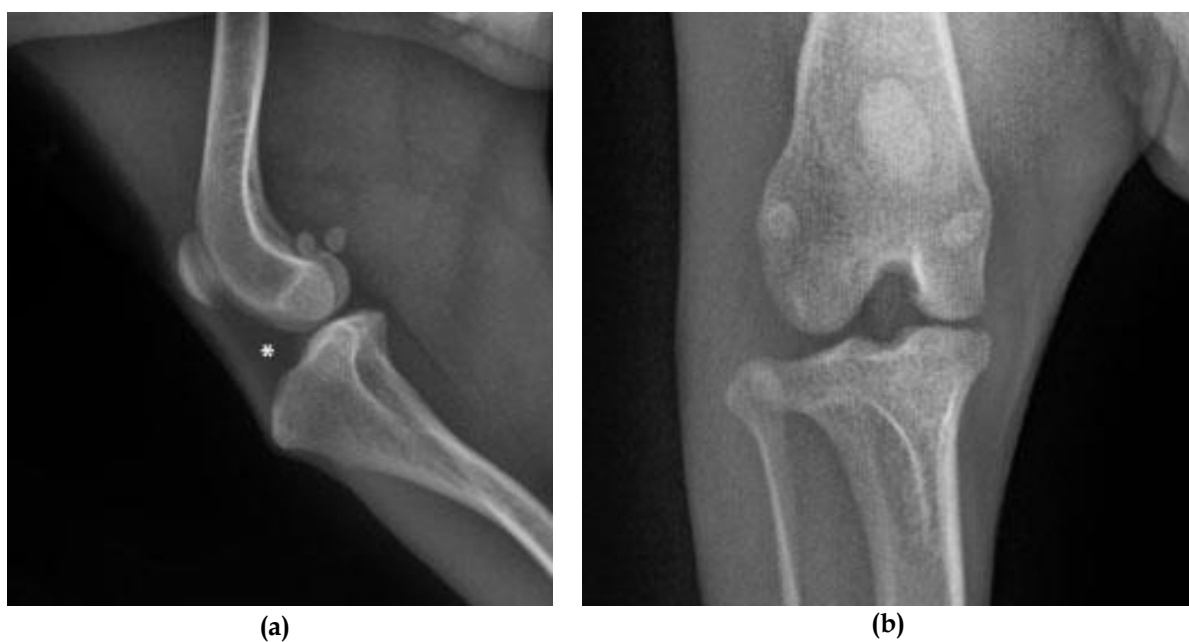
### Radiographic findings

On the mediolateral projection of the right stifle joint (Fig 1a), there was increased soft tissue density in the cranial joint space (asterisk) and compressed the radiolucent dimension of the intra-patella fat pad that normally seen in other normal stifle joints (Fig 2a, asterisk). Besides, at the caudal joint space, the bulging of the caudal joint capsule was detected (arrow). On corresponding caudocranial radiograph, mild degree of bone sclerosis due to the

subchondral bone sclerosis was noted at the medial tibial plateau in this patient (arrow) (Fig 1b), which this radiographic sign should not be detected in the normal dogs (Fig 2b). Interestingly, both mediolateral and caudocranial projections of the left stifle joint revealed alike radiographic signs as the right hind limb; however, the severity was lesser than the contralateral side. (Data did not showed).



**Figure 1** The mediolateral radiograph of the right stifle joint (a) of the lameness patient unveiled the increased soft tissue density, which compressed the intra-patella fat pad at the cranial joint space (asterisk) while the caudal joint space revealed the bulging of the caudal joint capsule (arrow). On the corresponding caudocranial radiograph (b) of the same patient, the subchondral bone sclerosis (the considering bone sclerosis) was detected at the medial tibial plateau (arrow).



**Figure 2** The mediolateral (a) and the caudocranial (b) radiographs of the normal stifle joint. The arrow indicated the normal radiolucent, fat density of the intra-patella fat pad.

## **Radiographic diagnosis**

Joint effusion and early stage of osteoarthritis

## **Discussion**

The effusion of the stifle has been reported to be a radiographic sign of several joint diseases; for example: synovial T-cell lymphoma (Lahmers et al., 2002) or the malignant fibrous histiocytoma (Booth et al., 1998). However, one of the most important diseases that could induce the joint effusion is the injury of the cranial cruciate ligament. As the result of the cranial cruciate ligament abnormalities, either partial or the complete tear, the instability of the stifle joint could be happened that subsequently induced several osteoarthritis signs, which could be normally observed through the plain radiograph. In addition to the joint effusion, other signs would be composed of the periarticular osteophytes, enthesiophytes, joint surface remodeling, subchondral bone sclerosis including cyst formations, intra-articular mineralization, and soft tissue swelling (D'Anjou et al., 2008). Among former signs, joint effusion and soft tissue thickening of the joint capsule have been reported to be the early radiographic signs which the mostly peak at the 8<sup>th</sup> week whereas the osteophytic change could be delayed until the 26<sup>th</sup> week after injury (D'Anjou et al., 2008). In contrary to the effusion that has been reported to be an acceptable reliable parameter, the subchondral bone sclerosis revealed as the poor parameter to indicate the disease progression (Innes et al., 2004). In addition, an

abnormality of the contralateral stifle joint that has been unveiled in this patient, it could be caused by the development of contralateral cruciate ligament injury, which the same radiographic signs might be detected within a year (Chuang et al., 2014).

## **Reference**

- Booth MJ, Bastianello SS, Jiminez M and van Heerden A 1998. Malignant fibrous histiocytoma of the deep peri-articular tissue of the stifle in a dog. *J S Afr Vet Assoc.* 69(4): 163-168.
- Chuang C, Ramaker MA, Kaur S, Csomos RA, Kroner KT, Bleedorn JA, Schaefer SL and Muir P 2014. Radiographic risk factor for contralateral rupture in dogs with unilateral cranial cruciate ligament rupture. *PLoS One.* 9(9): e106389.
- D'Anjou MA, Moreau M, Troncy E', Martel-Pelletier J, Abram F, Raynauld JN and Pelletier JP 2008. Osteophytosis, subchondral bone sclerosis, joint effusion and soft tissue thickening in canine experimental stifle osteoarthritis: comparison between 1.5T magnetic resonance imaging and computed radiography. *Vet Surg.* 37: 166-177.
- Innes JF, Costello M, Barr FJ, Rudorf MB and Barr ARS 2004. Radiographic progression of osteoarthritis of the canine stifle joint: a prospective study. *Vet Radiol Ultrasound.* 45(2): 143-148.
- Lahmers SM, Mealey KL, Martinez SA, Haldorson GJ, Sellon RK and Cambridge AJ 2002. Synovial T-cell lymphoma of the stifle in a dog. *J Am Anim Hosp Assoc.* 38(2): 165-168.