

6-1-1991

ELISA seropositive ocular toxocariasis:a case report

Vilavan Puangsrucharern

Pornsawat Nantawan

Malinee T. Anantaphruti

Follow this and additional works at: <https://digital.car.chula.ac.th/clmjjournal>



Part of the [Medicine and Health Sciences Commons](#)

Recommended Citation

Puangsrucharern, Vilavan; Nantawan, Pornsawat; and Anantaphruti, Malinee T. (1991) "ELISA seropositive ocular toxocariasis:a case report," *Chulalongkorn Medical Journal*: Vol. 35: Iss. 6, Article 7.

Available at: <https://digital.car.chula.ac.th/clmjjournal/vol35/iss6/7>

This Case Report is brought to you for free and open access by the Chulalongkorn Journal Online (CUJO) at Chula Digital Collections. It has been accepted for inclusion in Chulalongkorn Medical Journal by an authorized editor of Chula Digital Collections. For more information, please contact ChulaDC@car.chula.ac.th.

ELISA seropositive ocular toxocariasis: a case report

Vilavan Puangsricharern*
Pornawat Nantawan*
Malinee T. Anantaphruti**

Puangsricharern V, Nantawan P, Anantaphruti MT. ELISA seropositive ocular toxocariasis: a case report. Chula Med J Jun; 35(6): 381-386

*Ocular toxocariasis is an invasion of the eye by the larvae of *Toxocara canis* worm, nematode parasite of dogs. Children and young adults are subject to infestation. A 17-year-old Thai girl with suspected ocular toxocariasis was presented with a history of decreased vision. The retinal lesion was posterior retino-choroiditis type and a positive ELISA titer confirmed the diagnosis. The patient was treated and clinically cured by systemic and topical steroid. Since ocular toxocariasis presents with various ocular entities, clinician should be aware of this disease when children or young adults present with such clinical symptoms.*

Key words: Ocular toxocariasis, Retinochoroiditis, ELISA.

Reprint request : Puangsricharern V, Department of Ophthalmology, Faculty of Medicine, Chulalongkorn University, Bangkok 10330, Thailand.

Received for publication. December 11, 1990.

วิลาวัลย์ พวงศรีเจริญ, พรสวรรค์ นันทวัน, มาลินี ท. อนันตพฤทธิ. อโสภา ศรีโรโปลีฟ อ็อคคิวลาร์ ทอกโซคาเรียซิส: รายงานผู้ป่วย จุฬาลงกรณ์เวชสาร 2534 มิถุนายน; 35(6): 381-386

โรค *TOXOCARIASIS* ของตาเกิดจากไข่พยาธิตัวกลม *Toxocara canis* ของสุนัข เจริญเติบโตเป็นตัวอ่อนแล้วไขเข้าไปทำให้เกิดโรคในตา วัยเด็กและผู้ใหญ่ตอนต้นมักจะได้รับเชื้อนี้มากกว่าในวัยอื่น ได้รายงานผู้ป่วยหญิงไทยอายุ 17 ปีที่มาพบจักษุแพทย์ด้วยเรื่องตามัวลง ตรวจพบมีการอักเสบของจอประสาทตาและผลการตรวจทางห้องปฏิบัติการโดยวิธี *ELISA* พบว่ามีภูมิคุ้มกันต่อเชื้อ *Toxocara* ผู้ป่วยได้รับการรักษาด้วย *steroid* ในรูปของยากินและยาหยอดตาจนอาการหายเป็นปกติ โรค *Toxocariasis* ของตาสามารถทำให้เกิดพยาธิสภาพหลายแบบในตา จักษุแพทย์จึงควรนึกถึงในผู้ป่วยที่มีลักษณะและอาการดังกล่าว

Toxocariasis is the infestation of a dog round worm *Toxocara canis*. Human ingest food contaminated with the ova, and under favourable conditions through intestinal activity, the ova hatch and larvae penetrate the intestinal wall, enter lymphatics, the

portal circulation and migrate to many tissues causing various clinical diseases such as hepatitis, pneumonitis, brain abscess, known as visceral larval migrans (VLM) (Diagram 1)

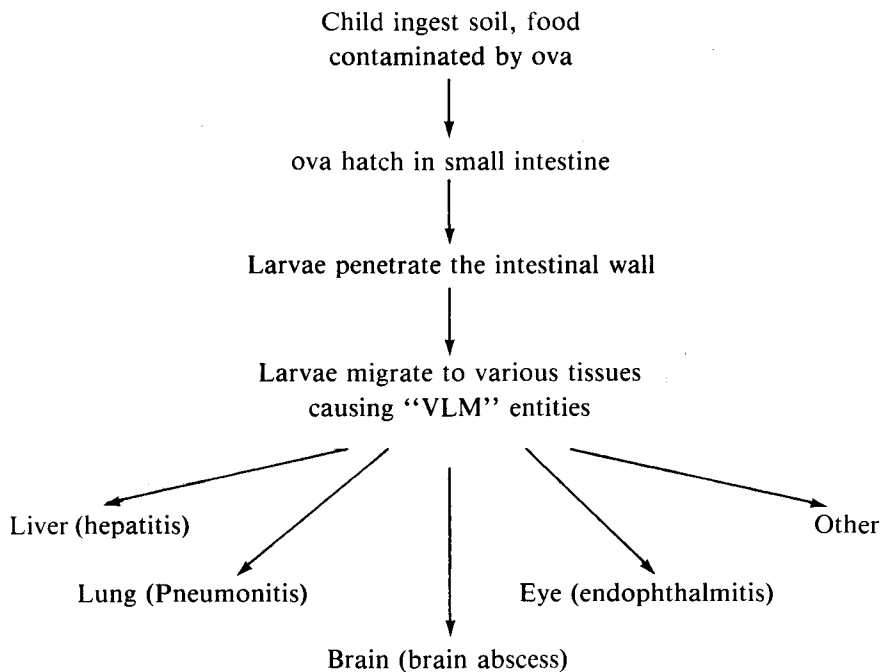


Diagram 1

Most patients are healthy children and young adults⁽¹⁾. The relationship of ocular toxocariasis and VLM is unclear. Patients with VLM may have no evidence of ocular toxocariasis⁽²⁾ while patients with ocular toxocariasis may have no history of VLM. Ocular involvement can assume any of several clinical patterns as reviewed by Shields in 1984.⁽³⁾ These are posterior retinochoroiditis, peripheral retinochoroiditis, optic papillitis, endophthalmitis, motile chorioretinal nematode, diffuse unilateral subacute neuroretinitis (DUSN), keratitis, conjunctivitis and lens involvement.

Patients with ocular toxocariasis may experience unilateral loss of vision. Although the incidence of ocular toxocariasis is not quite clear because of the variation of the disease, the diagnosis is being made with increasing frequency. By the advent of new diagnostic procedures, the enzyme linked immunosorbant assay (ELISA), and therapeutic advances such as vitrectomy techniques, facilitated clinicians to diagnose the disease. The authors report

a case of suspected ocular toxocariasis, supported by positive ELISA. The related medical literatures are reviewed.

Case report

A 17 years old Thai girl was seen at the eye clinic at Chulalongkorn Hospital with a 2 weeks history of decreased vision, redness and pain in the left eye. Her past history was uneventful except a history of exposure to a puppy at home. The physical examination was normal. The vision on the left eye was 20/100 with best correction. Ocular examination revealed ciliary injection of the left eye, anterior chamber cells and flare, normal iris and pupillary reaction and normal lens. The eyeground revealed an ill-defined white retinal lesion with vitreal strands extending from posterior pole to the optic disc. There were some yellowish retinal pigment epithelial (RPE) discolorations under the lesion and around the macular

area. (Fig. 1) When 3-mirror fundus contact lens was performed some vitreal fibril and cells adjacent to the lesion were found. The right eye was unremarkable. The ocular tonometry was normal in both

eyes. The fundus fluorescein angiography (FFA) revealed hyperfluorescent leakage from blood vessels around the lesion and RPE window defect beneath the lesion. (Fig. 2)

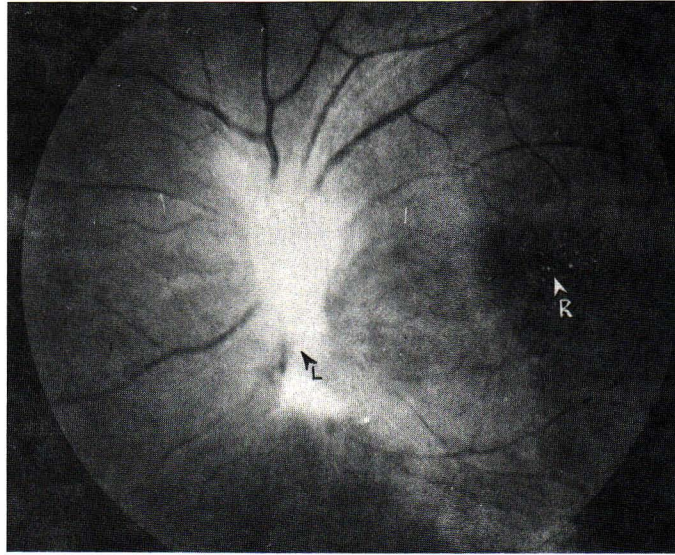


Figure 1. Fundus photography showed ill-defined white retina lesion (L) with vitreal strands extending from posterior pole to optic disc. There were some yellowish RPE discolorations (R) under the lesion and around macular area.

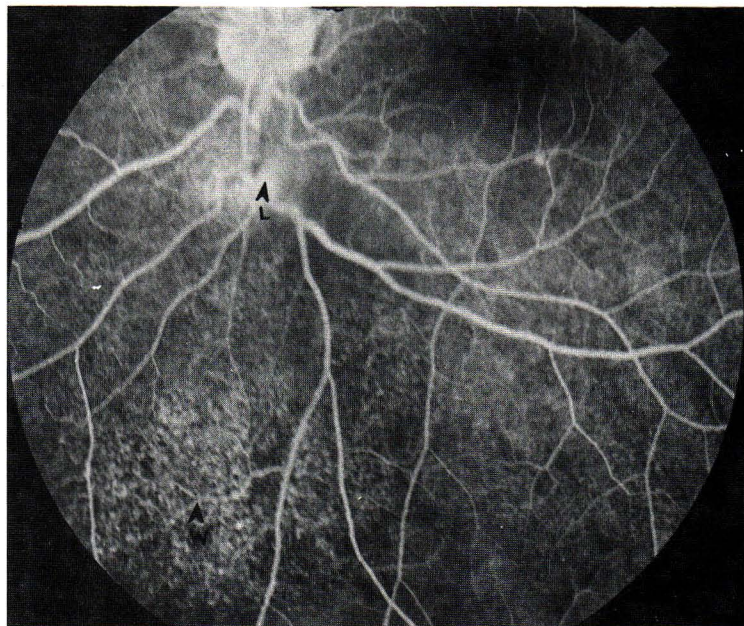


Figure 2. Fundus fluorescein angiography showed hyperfluorescent leakage from blood vessels (L) around the lesion and RPE window defect (W) beneath the lesion.

Complete blood count, showed eosinophilia of 3,872 cell/mm³. There were hook worm and opisthorchis ova in the stool test, done by concentration technique. The ELISA for *Toxocara canis* reported from the Department of Helminthology, Faculty of Tropical Medicine, Mahidol University was positive at the titer of 1:800 with XIN value of 6.2. The patient was treated with oral prednisolone 80 mg/day combined with 0.1% dexamethasone phosphate eye drop four times a day and 1% atropine sulfate eye drop twice a day. The anterior uveitis was cleared within 1 week then oral steroid was reduced and discontinued within 1 month. During the 2 months follow up, the vitreo-retinal lesions remained stable. Her vision returned to 20/20. No surgical intervention was performed.

Materials and Methods used in ELISA TEST

The antibodies in patient's serum were assessed by an enzyme linked immunosorbent assay (ELISA) using *Toxocara cati* antigen. The parasite antigen was prepared as followed, the adult *Toxocara cati* obtained from natural infected cats were ground in distilled water. The homogenated antigen was centrifuged at 10,000 rpm at 4°C for 30 minutes, the supernate was collected used as antigen. The protein content was determined by the method of Lowry et al.⁽¹³⁾ An ELISA was performed in a microtiter plate (Griner). Each well was coated with 100 µl of 25 µg protein per ml antigen diluted in phosphate buffer saline (PBS) pH 7.4. The plate was left in room temperature for 2 hours and kept in 4°C overnight. The wells were washed 3 times with PBS containing 0.05% Tween 20 (PBS-T), soaked in PBS-T containing 1% bovine serum albumin at room temperature for 30 minutes. One hundred µl of duplicated serum samples at 1:800 dilution were added followed by incubation at room temperature for one hour. The plate was washed and 100 µl of 1:800 diluted peroxidase-conjugated antihuman IgG (γ-chains; DAKO, Denmark) was added to each well. After incubation for an hour, the plate was again washed and added 100 µl of 0.05% para-phenylenediamine dihydrochloride in citrate buffer pH 4.5 containing 0.003% H₂O₂. The plate was kept in the dark for 30 minutes and the enzymatic reaction terminated by adding 50 µl of 1 N NaOH. The optical density was read at 492 with an ELISA reader (Titertex Multiskan Plus Mk II). Wells incubated with buffer only were used as background controls. Pooled sera of healthy persons were used as normal controls. The results expressed as optical density of test sample/optical density of

normal control (X/N), the X/N = 2 is the cut off value.

Discussion

The definitive diagnosis of ocular toxocariasis can only be made by the finding of toxocara larva in ocular tissue. Apparently it cannot be obtained in every case, therefore the diagnosis is based upon classical clinical findings and the ELISA titer which is the most reliable laboratory test. According to Shields classification,⁽³⁾ this patient was in the posterior retinochoroiditis category which is typically unilateral. In the acute stage, there were anterior and posterior uveitis. The retinochoroiditis appeared as an ill-defined white lesion with overlying inflammation of the vitreous. As the acute inflammation subsided, there was a vitreal band extending from the lesion to the optic disc.

As in many reports, the patient's blood test showed eosinophilia, though some reports claimed that there may be no eosinophilia at the time of diagnosis.^(3,4,10) Although the stool test revealed hook worm ova and opisthorchis ova, neither related to her clinical findings nor affected the result of ELISA. The presumptive diagnosis of ocular toxocariasis was made by a positive ELISA titer. The introduction of ELISA has created recent enthusiasm among ophthalmologists for the diagnosis. This test was shown experimentally to be the most reliable laboratory test.⁽¹⁴⁾ The serum titer of 1:8 was shown to yield high specificity (91%) and sensitivity (90%).⁽⁵⁾ Therefore, many clinicians consider a 1:8 titer to be positive if the patient had compatible signs and symptoms. The patient's serum showed a high positive titer of 1:800 which provide the authors with more confidence to diagnose the disease. Although crude somatic extract antigen prepared from any adult parasites showed cross-reactivity with hetero-helminthic infections. An assay with a higher dilution of serum samples appeared less cross-reactivity.⁽¹⁵⁾ However, a small percentage of patients may have a lower ELISA titer.⁽⁶⁾ Moreover, a recent paper has shown that when the patients with ELISA titer were followed up, 55% showed a decrease in serum titers, 10% showed an increase, and 5% were stable.⁽⁷⁾ So exact titers should be requested, as any positive titer (even as low as 1:2) with clinical condition, is believed to be significant. The seropositive titer may also be found in young healthy children with no evidence of ocular toxocariasis, and strongly associated with history of both pica and puppy ownership.⁽⁸⁾ Therefore, the definitive diagnosis can only be made

by histologic demonstration of *T. canis* larvae in the ocular tissue.

High ELISA titers can be found in the vitreous humor and the aqueous humor in patients with presumed ocular toxocariasis,^(9,10) so if the serum titer is negative in suspected case, intraocular fluid tapping may yield a positive result. Aqueous and vitreous cytologic examination can also be used and support the diagnosis if eosinophils are revealed in the fluid.^(9,10)

There is no satisfactory medical treatment for ocular toxocariasis.⁽¹⁾ Anthelmintics such as thiabendazole 50 mg/kg/day for 5 days as well as albendazole 10 gm/kg/day for 5 days were shown to reduce mean eosinophilia and cure clinical symptoms and were recommended by some clinicians.⁽¹¹⁾ The mainstay of therapy goes through the use of anti-

inflammatory drugs such as steroid to suppress the inflammation and minimize ocular complications.⁽³⁾ They can be given as topical drops, by subconjunctival or subtenon's injection, or orally depending on the site of the inflammation and its severity. The dose should be tapered and discontinued if the clinical signs and symptoms subsided. This patient was found to be clinically improved after the administration of steroid of both oral and topical forms. Ocular surgery especially vitrectomy has been used to prevent severe complications such as retinal detachment, cyclitic membrane and ultimately phthisis bulbi. Patients with ocular toxocariasis may benefit from subtotal pars plana vitrectomy when chronic inflammation does not respond to medical measures or when such inflammation cause permanent structural changes that threaten or interfere with central vision.⁽¹²⁾

References

- Gass JM. Steroscopic Atlas of Macular Diseases: Diagnosis and Treatment. 3rd ed. St. Louis: C.V. Mosby, 1987. 132-4
- Worley G, Green JA, Frothingham TE, Sturmer RA, Walls KW, Pakalnis VA. *Toxocara canis* infection: clinical and epidemiological associations with seropositivity in kindergarten children. *J Infect Dis* 1984 Apr; 149(4): 591-7
- Shields JA. Ocular toxocariasis: a review. *Surv Ophthalmol* 1984 Mar-Apr; 28(5): 361-81
- Wilkinson CP, Welch RB. Intraocular toxocara. *Am J Ophthalmol* 1971 Apr; 71(4): 921-30
- Molk R. Ocular toxocariasis: a review of the literature. *Ann Ophthalmol* 1983 Mar; 15(3): 216-31
- Kielar RA. *Toxocara canis* endophthalmitis with low ELISA titer. *Ann Ophthalmol* 1983 May; 15(5): 447-9
- Pollard ZF. Long-term follow-up in patients with toxocariasis as measured by ELISA titers. *Ann Ophthalmol* 1987 May; 19(5): 167-9
- Ellis GS Jr, Pakalnis VA, Worley G, Green JA, Frothingham TE, Sturmer RA. *Toxocara canis* infestation: clinical and epidemiological associations with seropositivity in kindergarten children. *Ophthalmology* 1986 Aug; 93(8): 1032-7
- Biglan AW, Glickman LT, Lobes LA Jr. Serum and vitreous *Toxocara* antibody in nematode endophthalmitis. *Am J Ophthalmol* 1979 Nov; 88(5): 898-901
- Felberg NT, Shields JA, Federman JL. Antibody to *Toxocara canis* in the aqueous humor. *Arch Ophthalmol* 1981 Sep; 99(9): 1563-4
- Sturchler D, Schubarth P, Gualzata M, Gottstein B, Oettli A. Thiabendazole VS. albendazole in treatment of toxocariasis: a clinical trial. *Ann Trop Med Parasitol* 1989 Oct; 83(5): 473-8
- Belmont JB, Irvine A, Benson W, O'Connor GR. Vitrectomy in ocular toxocariasis. *Arch Ophthalmol* 1982 Dec; 100(12): 1912-5
- Lowry OH, Rousebrough NJ, Farr AL, Randall RJ. Protein measurement with folin phenol reagent. *J Biol Chem* 1951; 193:265-75
- Cypess RH, Karol MH, Zidian JL, Glickman LT, Gitlin D. Larvaspecific antibodies in patients with visceral larva migrans. *J Infect Dis* 1977 Apr; 135(4) : 633-40
- Inoue H, Tsuji M. Studies on visceral larva migrans: detection of anti-*Toxocara canis* IgG antibodies by ELISA in human and rat sera. *Jpn J Parasitol* 1989 Apr; 38(2) : 68-76