

12-1-2014

## What is Your Diagnosis?

Nan Choisunirachon

Follow this and additional works at: <https://digital.car.chula.ac.th/tjvm>



Part of the [Veterinary Medicine Commons](#)

---

### Recommended Citation

Choisunirachon, Nan (2014) "What is Your Diagnosis?," *The Thai Journal of Veterinary Medicine*: Vol. 44: Iss. 4, Article 21.

Available at: <https://digital.car.chula.ac.th/tjvm/vol44/iss4/21>

This Other is brought to you for free and open access by the Chulalongkorn Journal Online (CUJO) at Chula Digital Collections. It has been accepted for inclusion in The Thai Journal of Veterinary Medicine by an authorized editor of Chula Digital Collections. For more information, please contact [ChulaDC@car.chula.ac.th](mailto:ChulaDC@car.chula.ac.th).

## What is Your Diagnosis?

Nan Choisunirachon

### *Signalment*

A twelve-year-old, spayed female, mixed breed dog.

### *History*

The patient was presented at the Small Animal Teaching Hospital, Chulalongkorn University due to the chief complaints of bloody nasal discharge from the right nasal cavity. The dog has been confirmed to have the nasal adenoma with locally suppurative inflammation.

### *Clinical examination*

The patient was bright and alert. Unless bloody nasal discharge and right nasal swelling, all of the clinical signs; for example: hydration condition, mucous membrane color, heart sound and lung sound, were normal. In addition, all laboratory data were within normal limit.

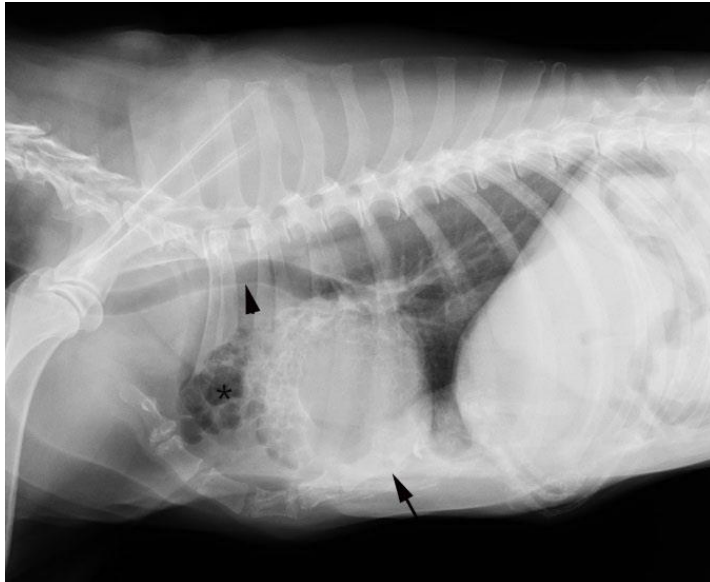
### *Radiographic examination*

Prior to the further investigation of nasal abnormalities that the anesthetic procedure was required; the patient was subjected to perform the thoracic radiography to check the heart and lung condition. Therefore, the ventrodorsal and right lateral projections of thoracic radiographs were obtained.

What is your diagnosis?  
Please turn to next page for the answer.

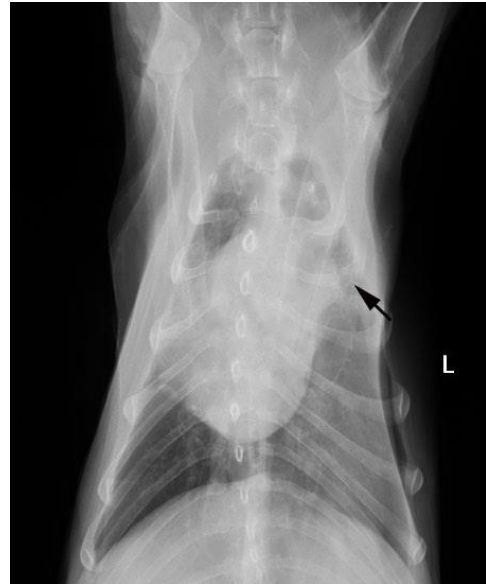### Radiographic findings

On the right lateral projection, the thoracic wall revealed the sternal deformity due to the dorsal displacement of the middle part of the sternum (arrow) that caused the narrowing thoracic height. There was evidence of the dorsal deviation of the thoracic trachea at the cranial mediastinal area (arrow head). In addition, at the cranioventral thoracic area, the lung parenchyma was increased radiolucency with multiple well-circumscribed air pockets in the cranial lung lobe (asterisk)



**Figure 1** Lateral projection of the thoracic radiograph revealed the dorsal displacement of the middle part of the sternum (arrow), the dorsal deviation of the thoracic trachea at the cranial mediastinal area (arrow head) and the multiple well-circumscribed air pockets in the cranial lung lobe (asterisk)

(asterisk) (Fig. 1) whereas other thoracic information, such as cardiac size and the rest of pulmonary parenchyma revealed normal appearances. On the ventrodorsal thoracic radiograph, the sternal deformity was hardly detected in according to the superimposition to the sternum. The pulmonary parenchyma was increased radiopacity on the left hemithorax and superimposed with the skin fold. At the cranial lung lobes, there was evidence of the small, air-filled pockets at the left side (arrow).



**Figure 2** Ventrodorsal projection of the thoracic radiograph showed the small, air-filled pockets at the left side (arrow).

### Radiographic diagnosis

Pectus excavatum and lung emphysema.

### Discussion

Pectus excavatum is a dorsal intrusion of the sternum to the thorax that may induce the respiratory impairment due to the limited lung volume. As the result of thoracic wall condition, the patient might show the clinical signs of tachypnea and weakness (Owen and Biery, 1999). In according to the pectus excavatum, the air-filled cavity as the emphysema in the pulmonary parenchyma may happen due to the chronic obstructive pulmonary diseases. Lung

emphysema is the permanent enlargement of the terminal bronchioles concurrent with the destruction of the alveolar wall. Therefore, the radiographic morphology of emphysema will be the air-filled (radiolucent) spaces with the thin wall. If the emphysema is presented on the radiographs, the rupture of the air-filled spaces that could induce the pneumothorax should be aware.

### Reference

- Owen JM and Biery DN 1999. Thorax (noncardiac). In: Radiographic interpretation for the Small Animal Clinician. 2<sup>nd</sup>ed. JM. Owen and DN. Biery (ed.). Maryland: Williams & Wilkins. 147-184 pp.