

8-1-1991

Partial duodenal obstruction by abdominal aortic aneurysm

Polrat Wilairatana

Boonsong Maturosakul

Wiset Tangchai

Follow this and additional works at: <https://digital.car.chula.ac.th/clmjjournal>



Part of the [Medicine and Health Sciences Commons](#)

Recommended Citation

Wilairatana, Polrat; Maturosakul, Boonsong; and Tangchai, Wiset (1991) "Partial duodenal obstruction by abdominal aortic aneurysm," *Chulalongkorn Medical Journal*: Vol. 35: Iss. 8, Article 7.

Available at: <https://digital.car.chula.ac.th/clmjjournal/vol35/iss8/7>

This Case Report is brought to you for free and open access by the Chulalongkorn Journal Online (CUJO) at Chula Digital Collections. It has been accepted for inclusion in Chulalongkorn Medical Journal by an authorized editor of Chula Digital Collections. For more information, please contact ChulaDC@car.chula.ac.th.

Partial duodenal obstruction by abdominal aortic aneurysm

Polrat Wilairatana*

Boonsong Maturosakul** Wiset Tangchai***

Wilairatana P, Maturosakul B, Tangchai W. Partial duodenal obstruction by abdominal aortic aneurysm. Chula Med J 1991 Aug; 35(8): 515-518

Duodenal obstruction as the initial symptom of an abdominal aortic aneurysm (AAA) is unusual. We report the case of a 71-year-old man who came to the hospital with a history of nausea, vomiting and fainting. Physical examination revealed a pulsatile abdominal mass at the epigastrium. Computerized tomography of the abdomen with dynamic contrast study showed partial obstruction by AAA of the third part of the duodenum.

An aneurysm should be considered in the differential diagnosis of causes of high intestinal obstruction in elderly patients.

Key words : Abdominal aortic aneurysm, Duodenal obstruction.

Reprint request : Wilairatana P, Department of Clinical Tropical Medicine, Faculty of Tropical Medicine, Mahidol University, Bangkok 10400, Thailand.

Received for publication. May 1, 1991.

* Department of Clinical Tropical Medicine, Faculty of Tropical Medicine, Mahidol University.

** Department of Internal Medicine, Faculty of Medicine, Chulalongkorn University.

*** Department of Surgery, Faculty of Medicine, Chulalongkorn University.

พลรัตน์ วิไลรัตน์, บุญส่ง มธุรสกุล, วิเศษ ต่างใจ. การอุดคั้นบางส่วนของคูโอตินัม จากการโป่งพองของหลอดเลือดเออตาในช่องท้อง. จุฬาลงกรณ์เวชสาร 2534 สิงหาคม; 35(8): 515-518

ภาวะคูโอตินัมอุดคั้นจากการถูกกดด้วยหลอดเลือดแดงเออตาที่โป่งพองตรงบริเวณท้องพบได้น้อย บทความนี้เป็นรายงานผู้ป่วยชาย 1 ราย อายุ 71 ปี มาโรงพยาบาลด้วยประวัติคลื่นไส้ อาเจียน 5 วัน และหมดสติ ก่อนญาติพามาโรงพยาบาล ตรวจร่างกายพบว่าผู้ป่วยซึม ความดันโลหิตต่ำมาก พบก้อนที่ท้องส่วนบนซึ่งเด่นตามหัวใจ จากการตรวจท้องด้วยคอมพิวเตอร์โทโมกราฟฟี และทำไตนามิคคอนทราสต์พบว่า ผู้ป่วยมีหลอดเลือดแดงเออตาที่ท้องโป่งพอง และกดคูโอตินัม ทำให้ลำไส้ส่วนนี้อุดคั้นบางส่วน

The frequency of abdominal aortic aneurysm (AAA) is increasing with the rise in the size of the elderly population.⁽¹⁾ Atherosclerotic AAA can produce the symptoms of virtually any intra-abdominal disorder; however, obstruction of the duodenum by an AAA is an unusual complication.⁽²⁾

Case report

A 71-year-old man attended the Department of Medicine, Chulalongkorn Hospital, with the complaint of fainting. He had history of anorexia, nausea, and vomiting for five days prior to admission.

Physical examination revealed a thin and dehydrated man with no clinical signs of anemia or jaundice. His blood pressure was 60 mmHg. He was stuporous owing to hypovolemic shock. An oval 8 × 10 cm, smooth pulsatile mass was palpable at the epigastrium.

Investigation showed the following; hemoglobin 12.5 gm%, WBC 9300/cu mm, PMN 89%, M 2%, L 9%, adequate platelets, BUN/Cr 45/1.7 serum sodium 149 mEq/L, serum potassium 3.1 mEq/L, serum chloride 110 mEq/L, and serum bicarbonate 27 mEq/L. A plain X-ray film of the abdomen showed an uncalcified soft-tissue mass in the upper abdomen (Fig. 1). Computerized tomography of the abdomen and dynamic contrast study disclosed a large saccular AAA, which was about 8.7 × 6.8 × 8 cm in size, from just below the origin of the renal artery down to the bifurcation of the aorta (Fig. 2).

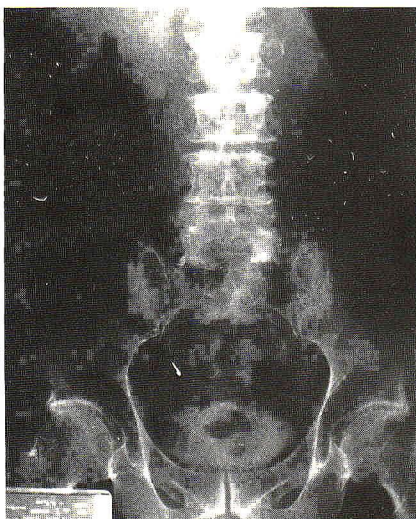


Figure 1. Plain film of abdomen showing soft-tissue mass in the upper abdomen.

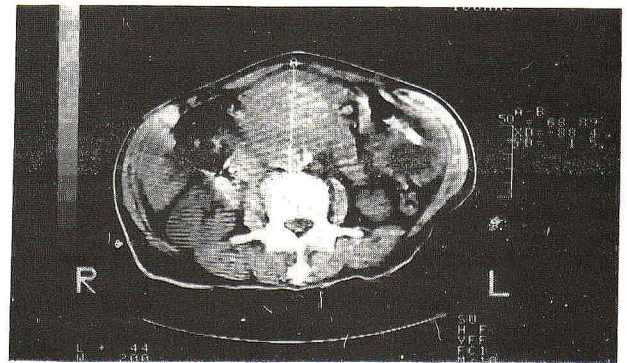


Figure 2. Computerized tomography of the abdomen shows abdominal aortic aneurysm with calcification of the wall.

This aneurysm compressed the third part of the duodenum and caused partial obstruction (Fig. 3). Intravenous fluid was started and his blood pressures became normal but he could not be taken to surgery owing to his poor general condition. On the fourth hospital day, the patient developed massive upper gastrointestinal bleeding. At emergency laparotomy, AAA with aorto-duodenal fistula to the fourth part of duodenum was observed. Aortic Y-graft and duodenal reparation were done.

The patient's course continued to be poor and became progressively worse for five days post-operatively until the time of his death. An autopsy was not done.

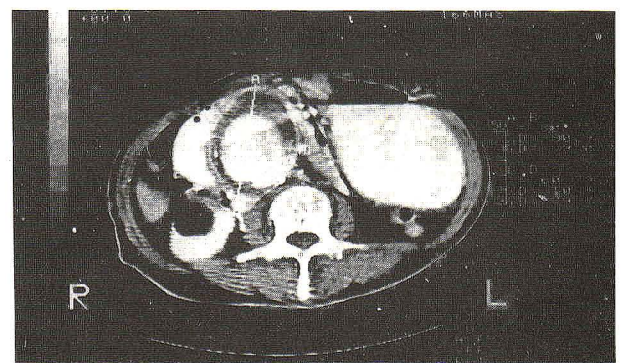


Figure 3. Spot film from dynamic contrast study shows the aneurysm compressing the third part of the duodenum and widening of the duodenal loop causing partial obstruction

Discussion

Osler⁽³⁾ first described duodenal obstruction as a feature of AAA; there have been some similar cases.⁽⁴⁾ Patients with duodenal obstruction invariably

complained of nausea, vomiting, and abdominal pain. The duration of symptoms was variable, ranging from days or weeks to 11 years.⁽⁵⁾ The male: female ratio has been calculated as 4:1, the patients, age ranging from 54 to 86 years, with the size of aneurysms ranging from 4.5 to 10 cm.⁽²⁾

The duodenum is the most common site for rupture of an AAA into the intestinal tract.^(6,7) However, although duodenal obstruction by an aneurysm is rare, it should be considered when obstruction of the transverse duodenum is accompanied by a pulsating mass. The obstruction is caused by compression of the transverse duodenum between the large aneurysm and the superior mesenteric artery.⁽⁸⁾ Surgical intervention is indicated in all patients.

Our patient conformed to the usual pattern. Interestingly, vomiting may be severe enough to cause dehydration and hypotension.

We suggest that this entity be considered in the differential diagnosis where duodenal obstruction is associated with finding of a pulsatile abdominal mass, or when abdominal films show calcification of the aneurysm.^(9,10) Computerized tomography and dynamic contrast study may be useful in demonstrating the aneurysm and may demonstrate the site of duodenal obstruction.

References

1. Panaro VA, Melzer MJ. Duodenal obstruction from abdominal aortic aneurysm. *NY State J Med* 1970 Mar 1; 70(5): 673-6
2. Hough DR, O'Meara TF. Abdominal Aortic Aneurysm with initial symptom of duodenal obstruction. *Am J Gastroenterol* 1981 Jun; 76(6): 538-41
3. Osler W. Aneurysm of abdominal aorta. *Lancet* 1905; 2: 1089-96
4. Sondheimer FK, Steinberg I. Gastrointestinal manifestations of abdominal aortic aneurysms. *AJR* 1964 Nov; 92:1110-22
5. Coster DP, Stubbs DH, Lidney DT. Duodenal obstruction by abdominal aortic aneurysms. *Am J Gastroenterol* 1988 Sep; 83(9): 981-4
6. Voyles WR, Moretz WH. Rupture of aortic aneurysms into gastrointestinal tract. *Surgery* 1958 Apr; 43(4): 666-71
7. Politoske EJ. Ruptured abdominal aortic aneurysm presenting as an obstruction of the left colon. *Am J Gastroenterol* 1990 Jun; 85(6): 745-7
8. Dunning EJ, Jones TE. Obstruction of the duodenum by an aneurysm of the abdominal aorta. *Am J Surg* 1950 Jun; 79(6): 848-50
9. Desideris VC, Kownacki V, Wilson WL. Partial duodenal obstruction from an abdominal aneurysm with hypochloremic alkalosis and azotemia. *Gastroenterology* 1959 Jun; 37(6): 766-9
10. Margoles JS, Olsen PA. Duodenal obstruction from abdominal aortic aneurysm. *Arch Surg* 1959 Apr; 78(4): 591-2