

9-1-1991

Bilirubin encephalopathy in adult

Samruay Shuangshoti

Pongsak Wannakrairot

Follow this and additional works at: <https://digital.car.chula.ac.th/clmjournal>



Part of the [Medicine and Health Sciences Commons](#)

Recommended Citation

Shuangshoti, Samruay and Wannakrairot, Pongsak (1991) "Bilirubin encephalopathy in adult," *Chulalongkorn Medical Journal*: Vol. 35: Iss. 9, Article 7.

DOI: 10.58837/CHULA.CMJ.35.9.7

Available at: <https://digital.car.chula.ac.th/clmjournal/vol35/iss9/7>

This Case Report is brought to you for free and open access by the Chulalongkorn Journal Online (CUJO) at Chula Digital Collections. It has been accepted for inclusion in Chulalongkorn Medical Journal by an authorized editor of Chula Digital Collections. For more information, please contact ChulaDC@car.chula.ac.th.

Bilirubin encephalopathy in adult

Samruay Shuangshoti*
Pongsak Wannakrairot*

Shuangshoti S., Wannakrairot P. Bilirubin encephalopathy in adult. *Chula Med J* 1991 Sep; 35 (9): 587-594

An exceedingly rare case is reported of bilirubin encephalopathy occurring in adult. A 55-year-old woman had chronic alcoholism, highly elevated blood bilirubin especially the unconjugated form (7.5 to 21.3 mg/100 ml), and jaundice. Postmortem examination disclosed chronic alcoholic hepatitis, mild micronodular cirrhosis, and severe cholestasis. Bilirubin staining of the brain was grossly visible at the caudate nuclei, hippocampi, cortex on the medial surface of each frontal lobe and lateral aspect of the right occipital lobe, cingular gyri, and cerebellar folia. Acute nonspecific degeneration of neurons and proliferation of Alzheimer's astrocytes were generally detected, particularly in the pigmented regions. These findings were interpreted as related to bilirubin and hepatic encephalopathies. Multiple factors appear to involve in the pathogenesis of bilirubin encephalopathy including elevation of unconjugated bilirubin, hypoalbuminemia, brain hypoxia and/or ischemia, hepatic encephalopathy, and damage of blood-brain barrier. The term "bilirubin encephalopathy" is more appropriate than "kernicterus"; because it is in accordance with the fact that bilirubin staining in the brain may also be extranuclear.

Key-words : Brain, Bilirubin, Jaundice, Encephalopathy, Kernicterus, Hepatitis, Cirrhosis

Reprint request : Shuangshoti S, Department of Pathology, Faculty of Medicine, Chulalongkorn University, Bangkok 10330, Thailand

Received for publication. March 25, 1991.

สารวทย ช่วงโชติ*, พงษ์ศักดิ์ วรรณไกรโรจน์. บัลัรบินเอนเซฟาโลพาธิในผู้ใหญ่. จุฬาลงกรณ์เวชสาร 2534 กันยายน, 35(9) : 587-594

บัลัรบินเอนเซฟาโลพาธิเป็นภาวะที่พบบ่อยในเด็กแรกเกิดที่ตายด้วยติชานจากสาเหตุใด ๆ ก็ตาม แต่พบน้อยมากหลังจากพ้นระยะแรกเกิดไปแล้ว โดยเฉพาะอย่างยิ่งในผู้ใหญ่ ใ้รายงานผู้ป่วยหญิง อายุ 55 ปี ตายด้วยติชานจากพิษสุราเรื้อรัง ติชานแข็ง และติชานที่มีระดับบัลัรบินในเลือดสูง โดยเฉพาะอย่างยิ่ง อันคอนจูเกเทตบัลัรบิน (7.5 ถึง 21.3 มก/100 มล) ตรวจศพพบสีเหลืองอันเนื่องมาจากมีบัลัรบินสะสมอยู่ในเนื้อสมองหลายแห่ง เช่น คอเททนิวเคลียส, ฮิปโปแคมปัส, คอร์เทกซ์ของกลีบฟรอนทัลด้านในสองข้างและของกลีบออกซิปิตัลขวา, ชิงกูลาร์ไจรัสทั้งสองข้าง, และสมองเล็ก พยาธิกำเนิดของบัลัรบินเอนเซฟาโลพาธิยังไม่ทราบกันแน่ชัด แต่เชื่อว่าเกิดจากหลายปัจจัย เช่นการมีติชาน, แอลบูมินต่ำในเลือด, สมองพร่องออกซิเจน และ/หรือ เลือดเลี้ยง, ภาวะเลือดเป็นกรด, และเอนเซฟาโลพาธิของติชาน เป็นต้น ใ้พิจารณาสรุปศัพท์แล้วเห็นว่า คำ “บัลัรบินเอนเซฟาโลพาธิ” เหมาะสมกว่า “เคอร์นิกเทอรัส” เพราะการสะสมของบัลัรบินนั้นอาจเกิดได้ทั้งในและนอกนิวเคลียสของสมอง

* ใ้รับทุนส่งเสริมอาจารย์ผู้อุทิศตนเป็นนักวิชาการของคณะแพทยศาสตร์ จุฬาลงกรณ์มหาวิทยาลัย (พ.ศ. 2534-2537)

Greenish yellow pigmentation of certain nuclei of the brain viz the basal ganglia with particular reference to the globus pallidus, hippocampi, subthalamic nuclei, dentate nuclei of the cerebellum, olivary nuclei of the medulla oblongata, and nuclei of the floor of the fourth ventricle in patient dying with jaundice has been called kernicterus (Kern is German for nucleus). The previously damaged region of the brain in addition to nuclei, moreover, may be stained such as the cortical infarct and necrotic paraventricular white matter. It is now known that

the staining agent is bilirubin. The term bilirubin encephalopathy is also used. The lesion occurs frequently in the newborn infant who dies with jaundice of various causes such as Rh or ABO incompatibility, hemolytic disease of the newborn, sepsis, and excessive administration of the vitamin K with elevated level of bilirubin, especially the unconjugated form. Premature newborn infants are more susceptible than mature ones.⁽¹⁾ These conditions, combined with immaturity of the brain in the newborn period, such as the presence of the extracellular spaces may result in crossing of bilirubin from the vascular compartment into the brain.

Bilirubin encephalopathy, however, is extremely rare beyond the neonatal period as has been reported in some cases of congenital hyperbilirubinemia (congenital nonhemolytic jaundice of Crigler-Najjar syndrome).⁽²⁻⁵⁾ This syndrome is related to an autosomal recessive form of nonhemolytic jaundice in which the hepatic glucuronyltransferase is absent leading to the presence of excessive amount of unconjugated bilirubin in the blood, occurrence of bilirubin encephalopathy, and severe disorders of the central nervous system. Some patients with this syndrome were adults.⁽³⁻⁵⁾ Apart from these few adult patients with Grigler-Najjar syndrome, we found two more examples of bilirubin encephalopathy in adolescent and adult patients. One occurred in a 14-year-old boy who had fulminating viral hepatitis and isolated central pontine myelinolysis.⁽⁶⁾ The other was a 43-year-old woman who died with severe probable non-A non-B hepatitis.⁽⁷⁾ In this communication, we record bilirubin encephalopathy occurring in an adult female with alcoholic hepatitis.

Case Report

A 55-year-old woman consumed daily a half of bottle of liquor for 20 years. Three months before hospitalization, she developed progressive jaundice and fatigue. A week prior to hospitalization, edema

of the lower limbs and fever ensued.

On admission to hospital, body temperature was 38° C, pulse rate 118/min, respiratory rate 28/min, and blood pressure (BP) 100/60 mm Hg. The positive findings consisted of deep jaundice of the sclerae, skin, and buccal mucosa. The hepatic edge was 6 cm below the costal margin. The lungs contained crepitations. The mental status was clear.

Hemoglobin ranged from 7 to 9 gm/100 ml, leucocyte counts 25,000 to 89,000 cells/mm³ with 92 to 93% neutrophils, 1 to 2% eosinophils, 5 to 6% lymphocytes, 0 to 2% monocytes, and 153,000 to 276,000 thrombocytes/mm³. Serum sugar was within the range of 70 to 100 mg/100 ml, albumin 1.7 to 1.8 gm/100 ml, globulin 1.9 to 3.7 gm/100 ml,

SGOT 65 to 71 IU/L, SGPT 14 to 22 IU/L, total bilirubin 8.5 to 35.3 mg/100 ml, conjugated bilirubin 11 to 16 mg/100 ml, unconjugated bilirubin 7.5 to 21.3 mg/100 ml, alkaline phosphatase 280 to 346 IU/L, sodium 134 to 139 mEq/L, potassium 2.1 to 4.6 mEq/L, and carbon dioxide 10 to 20 mEq/L. BUN was 18 mg/100 ml, and creatinine 3.0 mg/100 ml. The prothrombin time was 26.4 seconds (control 13.3 seconds). The dark urine contained urobilinogen and one plus protein. One to four plus blood was detected in the feces. Multiple hemocultures gave negative results. An ultrasonogram of the abdomen showed hepatosplenomegaly and parenchymal damage of the kidneys.

The patient received antibiotics and other supportive treatments. Her body temperature fluctuated (36.5° to 39°C) as was her BP (80/40 to 140/90 mm Hg). Her previously clear mental status became gradually blurred. A lumbar puncture, 7 days after hospitalization, depicted no cells. The patient died in coma 11 days after admission to hospital. The clinical impression was alcoholic cirrhosis with hepatic encephalopathy.

Postmortem Examination. Intense icteric staining was noted of various organs. The liver (1,650 gm) showed advanced cholestasis, alcoholic hepatitis (Fig 1), mild micronodular cirrhosis and bile plugs (Fig 2). Hyaline inclusion (Mallory's) bodies were frequent in the cytoplasm of the hepatocytes. There were many cellular infiltrates, chiefly neutrophils (Fig 1). Bile canaliculi and small bile ducts were frequently filled by bile (Fig 2). There was mild fatty change of the liver. Acute tubular necrosis was noted of the kidneys. The lungs were severely congested and edematous. Hydropericardium and hydroperitoneum (200 ml each) were present.

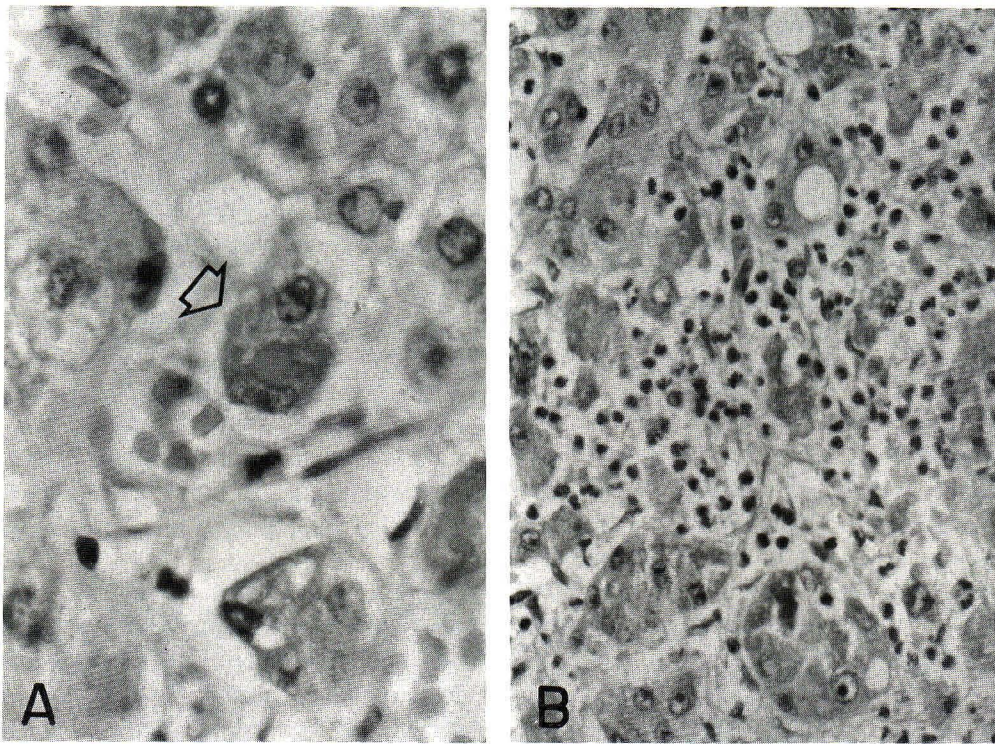


Figure 1. Alcoholic hepatitis.

- A. The arrow points toward a binucleated hepatocyte containing cytoplasmic hyaline inclusion body. Hematoxylin-eosin stain, x 1,000.
- B. Infiltration of leucocytes, chiefly neutrophils, in the liver is demonstrated. Hematoxylin-eosin stain, x 400.

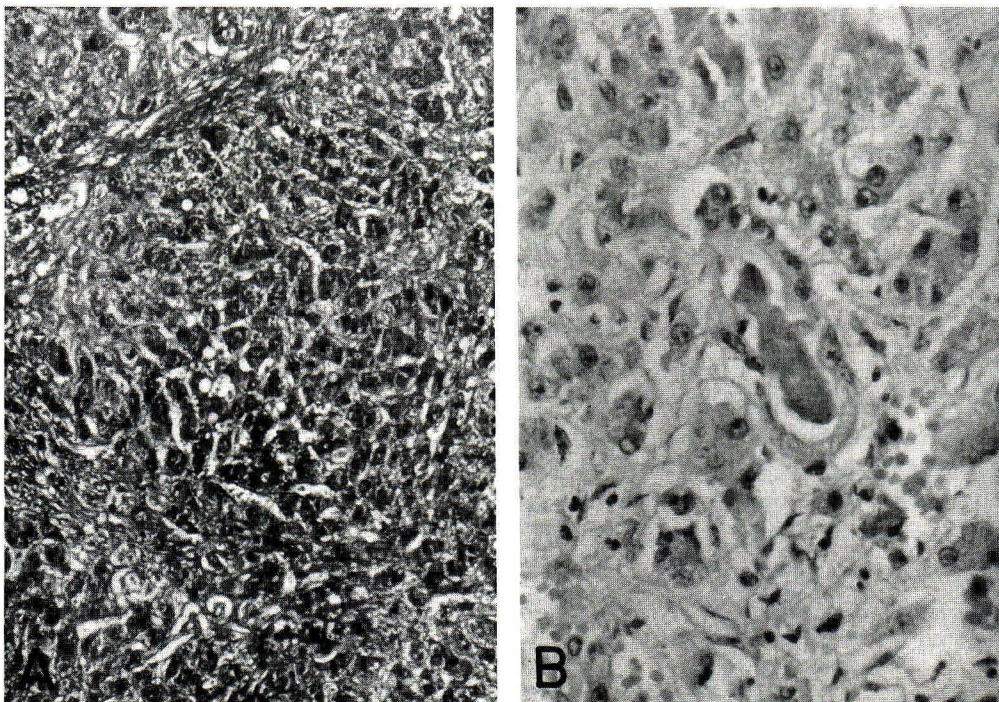


Figure 2. Cirrhosis and cholestasis of the liver.

- A. Micronodular cirrhosis is characterized by formation of the neolobule without central vein and with peripheral surrounding band of the connective tissue. Masson's trichrome stain, x 100.
- B. A small bile duct is plugged with bile representing cholestasis. Hematoxylin-eosin stain, x 400.

Coronal sections of the severely congested and edematous brain (1,160 gm) disclosed greenish yellow discoloration of the caudate nuclei, hippocampi,

frontal lobes on the medial surfaces, cingular gyri, right occipital cortex, and cerebellar folia (Figs 3 to 5).

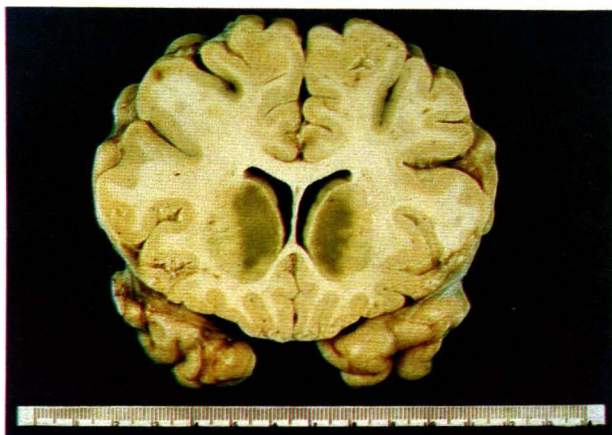


Figure 3. Bilirubin encephalopathy showing yellowish green discoloration of the head of caudate nuclei.

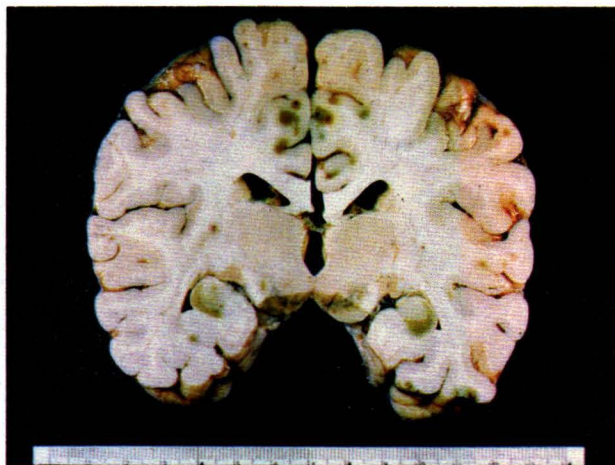


Figure 4. Bilirubin encephalopathy illustrating yellowish green pigmentation of the hippocampi and cortex of the medial aspect of the frontal lobes.

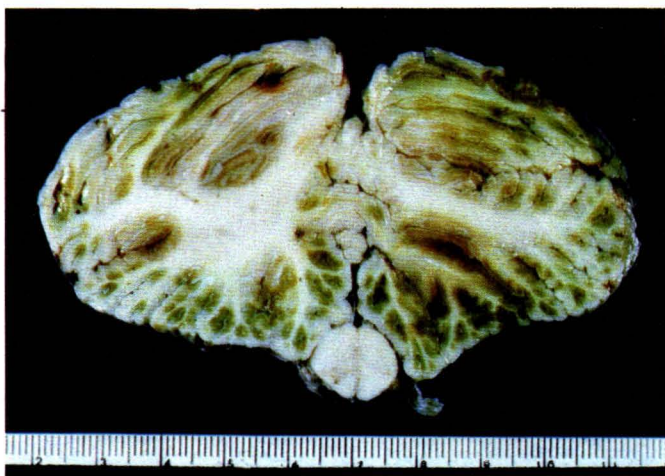


Figure 5. Bilirubin encephalopathy affecting the cerebellum. Note yellowish green staining of the cerebellar folia.

Microscopic examination of various pigmented places demonstrated acute nonspecific changes of neurons and glia in addition to edema of the brain. Some neurons were swollen with homogeneous pale acidophilic cytoplasm containing occasional vacuoles. Others were shrunken with intensely acidophilic perikaryon and with depletion of tigroid granules. The nuclei were often pyknotic and nucleoli were obscure (Fig 6). There was diffuse proliferation of astrocytes (Fig 7). They were frequently in pairs or small clusters. Their nuclei are often enlarged with margination of chromatin

granules and relatively clear central portion. Some nuclei were irregular, lobular, or bean-shaped. The nucleoli were often prominent. These astrocytes were interpreted as Alzheimer's glia^(8,9). Ones with discernable perikaryon were regarded as Alzheimer's type I astrocytes. Others with obscure cytoplasm were considered as Alzheimer's type II astrocytes. Granules of brown pigment similar to those seen in hepatocyte were occasionally observed in the cytoplasm of neurons and Alzheimer's glia, and were interpreted as pigment granules derived from bile. The pigment was nonreactive in staining for iron compound.

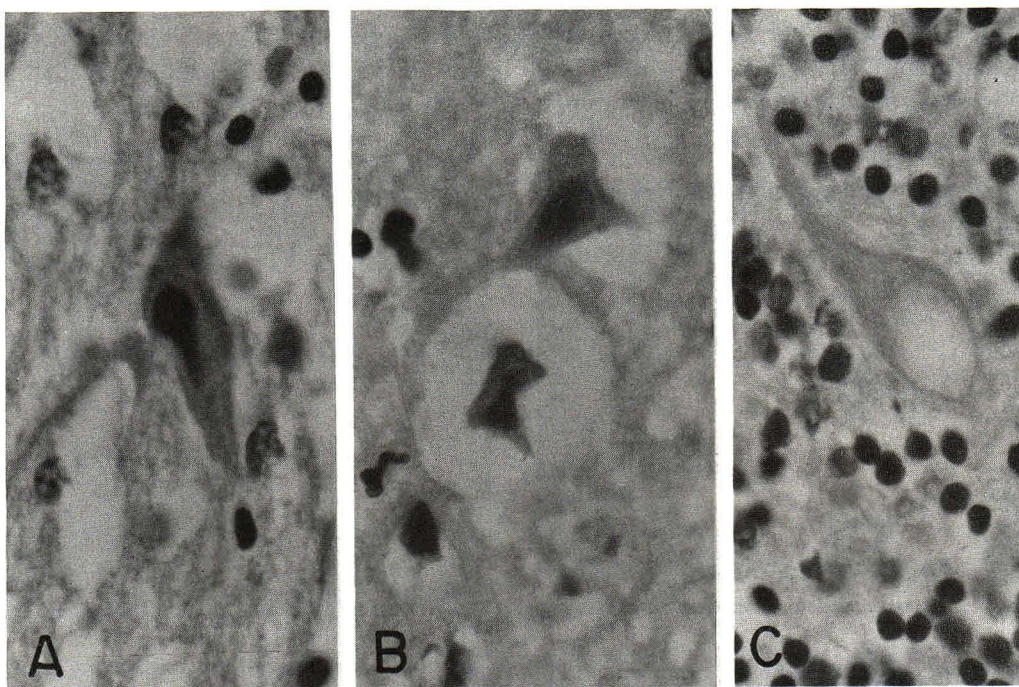


Figure 6. Acute nonspecific changes of brain. Hematoxylin-eosin stain, x 1,000.

- A. Cerebral cortex demonstrating loose neuropil indicating edema. A shrunken neuron with pyknotic nucleus is also seen.
- B. Cerebral cortex showing severe widening of perineuronal space representing edema of the brain. The shrunken neurons are also present.
- C. Cerebellum exhibiting degeneration of a Purkinje cell characterized by cytoplasmic vacuolation.

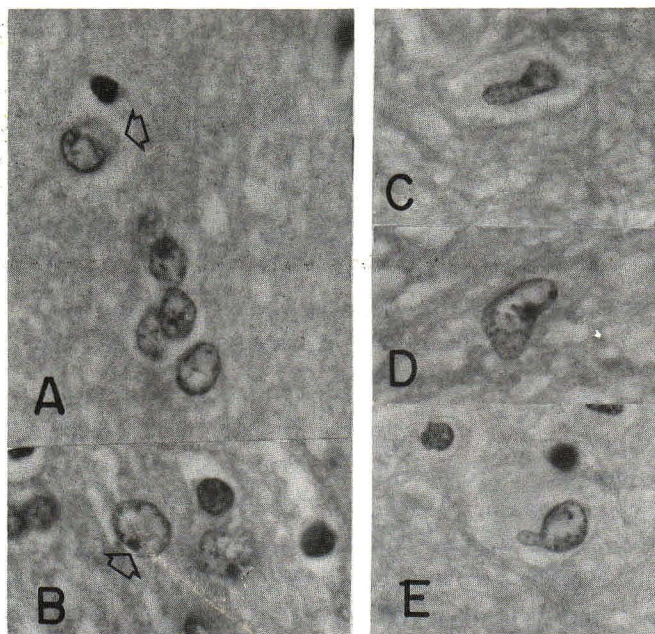


Figure 7. Proliferation of Alzheimer's glias representing hepatic encephalopathy. Hematoxylin-eosin stain, x 1,000 each.

- A. Alzheimer's astrocytes in small cluster are shown. The arrow points toward Alzheimer's astrocyte of type I with chromatin-poor nucleus rimmed by scant cytoplasm.
- B. Alzheimer's astrocytes of type II in pair are shown. Note prominent nucleoli (arrow) and obscure perikaryon. A few oligodendrocytes characterized by small dense nuclei surrounded by clear cytoplasm are also present.
- C, D, & E. Alzheimer's astrocytes with lobular, bean-shaped, or irregular nuclei are exhibited.

The pathologic diagnoses were severe alcoholic hepatitis, mild micronodular cirrhosis, cholestasis, icterus of various organs, acute renal tubular necrosis, and hepatic and bilirubin encephalopathy.

Disussion

The pyrexia and leucocytosis are well explained by advanced alcoholic hepatitis. The viral hepatitis is excluded by blood neutrophilia and neutrophils in the liver. Generally lymphocytic response is observed in viral infection.

Bilirubin is of two types, conjugated (direct) and unconjugated (indirect) ones. Direct bilirubin is conjugated with glucuronic acid; indirect bilirubin is not conjugated and neurotoxic. The pathogenesis of bilirubin encephalopathy is not yet clearly understood. It is, however, thought to be related to excessive production of bilirubin with elevated level of unconjugated bilirubin which accumulates in neurons and glia and which results in greenish yellow pigmentation of the brain, especially in various aforementioned nuclei. Nevertheless, it is clear from the current patient that extranuclear discoloration of bilirubin may also occur.

The mode of deposition of bilirubin in the brain is unclear. Multiple factors are quite likely to be involved including sufficiently high level of unconjugated bilirubin in the blood which crosses the blood-brain barrier (BBB) whereas conjugated bilirubin does not,⁽¹⁰⁾ hypoalbuminemia which decreases plasma bilirubin binding capacity,⁽¹¹⁾ damage of the BBB from various causes such as hypoxia and/or ischemia,⁽¹²⁾ and acidosis in which bilirubin is less firmly bound to albumin.⁽¹³⁾ Some of these factors were present in our case such as increase of blood bilirubin especially the unconjugated form, hypoalbuminemia, and cerebral hypoxia and/or ischemia as supported by fluctuation of BP. Our patient, moreover, had hepatic encephalopathy as revealed by proliferation of Alzheimer's glia.

Generally astrocytic processes are in intimate contact with neurons, basal laminae of capillaries, and pia mater. The processes fill the spaces between axons and dendrites, and bridge among neurons, capillaries, and pia mater. The function of astrocytes logically has been proposed to serve as a water-ion compartment for transport of fluid and metabolites between the

vascular system and neurons. Astrocyte, furthermore, serves as part of the anatomic BBB by virtue of attachment between its processes and capillary basal lamina. The anatomic barrier between the cerebrospinal fluid and brain is created by fusion of the astrocytic processes with pia mater, as has been reviewed.^(14,15) We suggest that proliferation of Alzheimer's astrocytes in the current patient may alter attachment between astrocytic processes and capillary basal laminae resulting in leakage of blood bilirubin into the edematous brain and occurrence of bilirubin encephalopathy.

We prefer to use the term "bilirubin encephalopathy" rather than "kernicterus" because it is seen in our case that bilirubin deposition occurs within as well as outside the nuclei of the brain. The term "kernicterus", hence, does not cover the entire territory of this pathologic pigmentation. Nevertheless staining of bilirubin in such structures as the meninges particularly dura mater, choroid plexuses, area postrema, pineal body, neurohypophysis, and intercolumnar tubercle should not be named bilirubin encephalopathy. This phenomenon occurs in most patients who have elevated blood bilirubin and die beyond neonatal period. This is related to the usual lacking of BBB in these structures.⁽¹⁵⁾

We do not have an unequivocal answer to explain why bilirubin encephalopathy is so rare in adults despite the fact that adult patients dying with jaundice are common in routine autopsy. Perhaps the explanation is either that blood bilirubin in such cases does not reach a sufficiently high level or that only conjugated bilirubin is elevated. The brain, hence, is not stained.

Acknowledgment

Samruay Shuangshoti, M.D. is currently recipient of Chulalongkorn Faculty of Medicine-China Medical Board Scholar Development Fund (1991-1994).

References

1. Ahdab-Barmada M, Moossy J. The neuropathology of kernicterus in the premature neonates: diagnostic problems. *J Neuropathol Exp Neurol* 1984 Jan; 43(1):45-56
2. Crigler JF Jr., Najjar VA. Congenital familial nonhemolytic jaundice with kernicterus. *Pediatrics* 1952;10:164-80

3. Jervis GA. Constitutional familial nonhemolytic hyperbilirubinemia with findings resembling kernicterus. *Arch Neurol Psychiatry* 1959 Jan;81(1):55-64
4. Huang PWH, Rozdilsky B, Gerard JW, Goluboff N, Holman GH. Grigler-Najjar syndrome in four of five siblings, with postmortem findings in one. *Arch Pathol* 1970 Dec;90(6):536-42
5. Wolkoff AW, Clowdhury JR, Gertner LA, Rose AL, Biempica L, Giblin DR, Fink D, Arias IM. Grigler-Najjar syndrome (type I) in an adult male. *Gastroenterology* 1979 Apr;76(1):840-8
6. Ho K-C, Hodach R, Varma R, Thorsteinson V, Hess T, Dale D. Kernicterus and central pontine myelinolysis in a 14-year-old boy with fulminating viral hepatitis. *Ann Neurol* 1980 Dec;8(6):633-6
7. Waser M, Kleihues P, Frick P. Kernicterus in an adult. *Ann Neurol* 1986 Jun;19(6):595-8
8. Malamud N, Hirano A. *Atlas of Neuropathology*. 2nd ed, Los Angeles: University of California Press, 1974:156-7, 396-7 & 402-3
9. Davis RL, Robertson DM. *Textbook of Neuropathology*. Baltimore: Williams & Wilkins, 1985:432-6
10. Barlow CF. Clinical aspect of the blood-brain barrier. *Ann Rev Med* 1964;15:187-202
11. Blanc WA, Johnson L. Studies on kernicterus: relationship with sulfonamide intoxication, report on kernicterus in rats with glucuronyl transferase deficiency and review of pathogenesis. *J Neuropathol Exp Neurol* 1959 Jan;18(1):165-89
12. Chen H-C, Lin C-S, Lien I-N. Vascular permeability in experimental kernicterus: an electron-microscopic study of the blood-brain barrier. *Am J Pathol* 1967 Jul;51(1):69-89
13. Odell GB. Influence of pH on distribution of bilirubin between albumin and mitochondria. *Proc Soc Exp Biol Med* 1965 Nov;120(544):352-4
14. Shuangshoti S, Samranvej P, Netsky MG. Phagocytic astrocytes and neurons in old encephalomalacia. *J Neuropathol Exp Neurol* 1979 May/Jun;38(3):235-41
15. Shuangshoti S, Tangchai P. *Neuropathology*. 2nd ed, Bangkok: Thai Watana Panich Press, 1983:10-12