

10-1-1991

CT scan and ultrasonic characteristic imaging of renal cell carcinoma

Kaesorn Vajarpongse

Darunee Bunjunwetwat

Sililuk Kaengsurakran

Laddawan Vajragupta

Follow this and additional works at: <https://digital.car.chula.ac.th/clmjournal>



Part of the [Medicine and Health Sciences Commons](#)

Recommended Citation

Vajarpongse, Kaesorn; Bunjunwetwat, Darunee; Kaengsurakran, Sililuk; and Vajragupta, Laddawan (1991) "CT scan and ultrasonic characteristic imaging of renal cell carcinoma," *Chulalongkorn Medical Journal*: Vol. 35: Iss. 10, Article 5.

DOI: 10.58837/CHULA.CMJ.35.10.5

Available at: <https://digital.car.chula.ac.th/clmjournal/vol35/iss10/5>

This Article is brought to you for free and open access by the Chulalongkorn Journal Online (CUJO) at Chula Digital Collections. It has been accepted for inclusion in Chulalongkorn Medical Journal by an authorized editor of Chula Digital Collections. For more information, please contact ChulaDC@car.chula.ac.th.

CT scan and ultrasonic characteristic imaging of renal cell carcinoma

Kaesorn Vajarpongse* Darunee Bunjunwetwat*
Sililuk Kaengsurakran* Laddawan Vajragupta*

Vajarpongse K, Bunjunwetwat D, Kaengsurakran S, Vajragupta L. CT and US characteristic imaging of renal cell carcinoma. Chula Med J Oct; 35(10): 651-661

The computerized tomographic (CT) and ultrasonographic (US) findings of 10 cases of renal cell carcinoma were reviewed. US was performed in nine patients (10 tumors); most of the findings (6 out of 10) were of a mass with complex echoes of mixed solid and cystic components. Three tumors were cystic in form, showing the characteristic appearance of a thick-walled cyst with echoic septation and growth projection containing internal bright echoes. Only one case showed multiple hyperechoic masses in the same kidney. CT was performed in eight patients (9 tumors). Characteristic findings were well-defined masses of mixed density. Six out of the nine tumors were mainly slightly more hyperdense than normal renal parenchyma on plain CT, showing patchy enhancement of a less than normally enhanced renal cortex. The other three cases were well-defined, thick-walled cysts, with septation and peripheral rim enhancement. All tumors were intrarenal masses, except one retroperitoneal mass which occurred following a previous nephrectomy for renal cell carcinoma of the left kidney. All involved kidneys preserved their excretory function. Only one case showed calcification in both the US and CT images.

Key words : Renal cell carcinoma, CT scan Ultrasound, Imaging.

Reprint request : Vajarpongse K, Department of Radiology, Faculty of Medicine, Chulalongkorn University, Bangkok 10330, Thailand.

Received for publication. July 10, 1991.

เกษร วัชรพงศ์, ดรณิ บุญยืนเวทวัฒน์, ศิริลักษณ์ เก่งสุรการ, ลัดดาวัลย์ วัชรคุปต์. ลักษณะภาพซีทีสแกน และอัลตราซาวนด์ของมะเร็งไต. จุฬาลงกรณ์เวชสาร 2534 ตุลาคม; 35(10): 651-661

ได้ทำการศึกษาย้อนหลังลักษณะภาพซีทีสแกนและอัลตราซาวนด์ของผู้ป่วยมะเร็งไต จำนวน 10 ราย ณ โรงพยาบาลจุฬาลงกรณ์ พบว่า 6 ใน 10 ของก้อนมะเร็งมีลักษณะภาพอัลตราซาวนด์ เป็นชนิดที่มีทั้งส่วนที่เป็นเนื้อและเป็นน้ำ (solid and cystic components) 3 ใน 10 เป็น cyst ที่มี septation และ 1 ราย เป็น hyperechoic masses คือมีการสะท้อนของคลื่นเสียงสูงกว่าเนื้อ ไตธรรมดา

ลักษณะภาพซีทีสแกน พบว่าเป็นก้อนที่มีขอบเขตชัดเจนและความทึบมากกว่าเนื้อไตธรรมดาเมื่อยังไม่ฉีดสารทึบแสง แต่มีความทึบน้อยกว่าเนื้อไตธรรมดาหลังจากฉีดสารทึบแสง จำนวน 6 ราย ใน 3 รายที่เป็น cyst พบว่ามีความทึบที่ขอบหลังจากฉีดสารทึบแสง (rim enhancement) และมีเพียง 1 ราย ที่พบมีหินปูนในก้อนมะเร็งไต ซึ่งสามารถเห็นได้ทั้งในอัลตราซาวนด์และซีทีสแกน

Ultrasound (US) provides a diagnostic method for the evaluation of renal masses. A mass can be classified simply into cystic, solid or complex varieties. Each entity has its own characteristic features and diagnosis which has been reported in the literature.⁽¹⁻⁷⁾ Computerized tomography (CT) is also a valuable tool in determining the nature and extent of masses.^(8,9) In this paper, we described 10 cases of proven renal cell carcinoma presenting US and CT features that would help to establish a diagnosis. In addition, we studied and compared the benefits of CT and US in examining renal cell carcinoma.

Materials and methods

Between 1986 and 1990, 10 cases of renal cell carcinoma were retrospectively reviewed for history and clinical presentation, emphasizing CT and US images. The US findings of location, size, echogenic pattern, calcification and extension were reviewed as well as those from the CT images. The CT study was also used to determine the excretory function of the kidneys.

Results

There were seven females and three males who had a total of 11 tumors among them. One case had tumors in bilateral kidneys and one had a recurrent left retroperitoneal mass at the site of a previous left nephrectomy for the treatment of renal cell carcinoma. Mean age was 51 years, ranging from 27 to 82 years. Most patients complained of abdominal or flank pain (5 out of 10) and/or palpable abdominal mass (3 out of 10). Two cases had fever, one of whom also had acute pyelonephritis. Two had gross hematuria (Table 1). Five tumors were found in the right kidney and five on the left side. One tumor was a retroperitoneal mass that developed following a previous nephrectomy. The tumor involved the upper pole of the kidney in five cases, the lower pole in two cases, and the whole kidney in two cases; one case had multiple foci (Table 2). The average size of the tumors measured by CT was about 8×10.4 cm and by US about 6.6×9.2 cm (Tables 3, 4).

Table 1. Clinical presentation. (10 patients).

Abdominal or flank pain	5
Fever	2
Gross hematuria	2
Palpable abdominal mass	3

* 1 patient had acute pyelonephritis.

Table 2. Site of tumor. (11 tumors).

Location:	
right kidney	5
left kidney	5
left retroperitoneal mass	1
Total	11
Region of involvement:	
upper pole	5
middle pole	0
lower pole	2
whole kidney	2
multiple foci	1
left retroperitoneal mass	1
Total	11

US was performed in nine patients (10 tumors). The findings are summarized in Table 3.

Table 3. US findings in renal cell carcinoma. (10 tumors in 9 patients).

Outline:		
- well-defined		9
hyperechoic rim		1/9
halo		2/9
without halo		6/9
(distinction of tissue echogenicity)		
- poorly defined		1
Echogenicity:		
solid		
hyperecho, multiple foci		1
(multiple renal stones with hydronephrosis)		
cystic		3
complex		6
Size of tumors:		
Range		5.1 – 7.4 × 6.5 – 11 cm
Average		6.6 × 9.2 cm

Nine tumors had a well-defined margin. Six tumors showed distinction of echoic tissue, two tumors had low echoic halo and another one showed hyperechoic rim. One patient had multiple hyperechoic masses in one kidney associated with multiple renal stones and hydronephrosis (Fig. 1). Six of nine

tumors were complex masses showing heterogeneous echoic and low echoic or cystic areas (Fig. 2). Three tumors had the same appearances of thick-walled cysts, with septation and growth projection containing containing internal bright echoes (Fig. 3).

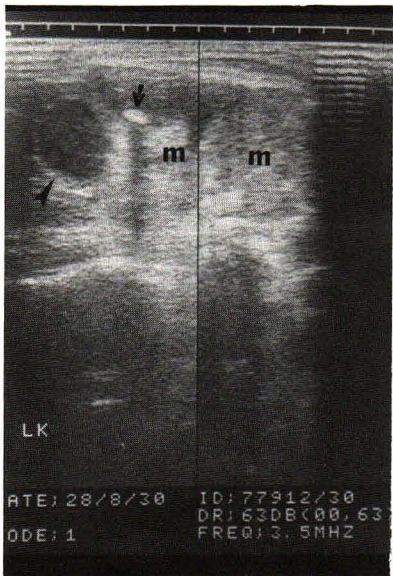


Figure 1. A longitudinal sonogram of the left kidney shows hyperechoic masses (m) at the lower pole with hydronephrosis (arrow head) and stone (arrow).

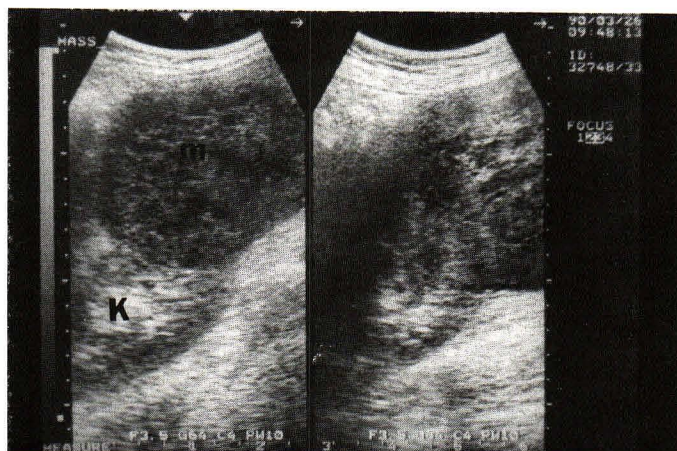


Figure 2. A longitudinal sonogram shows a complex mass (m) at the lower pole of the kidney

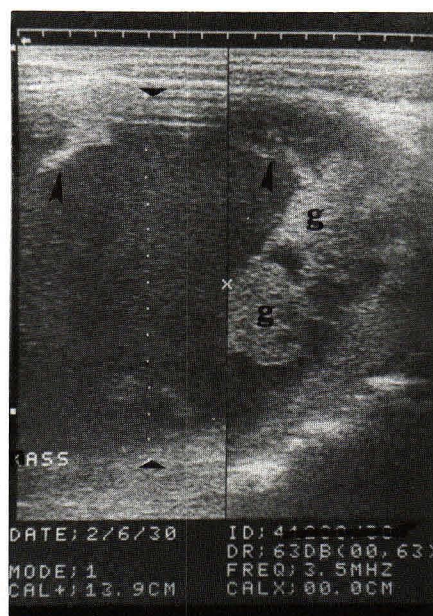

Figure 3. A longitudinal sonogram shows a thick-walled cystic mass (> <) with septation (arrow heads) and nodular growths (g).

CT findings of nine tumors in eight patients are presented in Table 4.

All of six solid and three cystic masses had a well-defined margin. The solid forms showed an inhomogenous, slightly more hyperdense than normal renal parenchyma on plain CT. The enhanced pattern was typically inhomogenous or a patchy enhancement less than a normally enhanced renal parenchyma (Fig. 4). Peripheral rim enhancement was demonstrated in four masses (Fig. 5) and

without such enhancement in two masses. The three cystic tumors had the appearance of a thick-walled cyst, with thick septation and discrete irregular nodules. All of the cystic tumors had rim enhancement, with enhanced septa and nodules (Fig. 6). Preserved excretory function of the involved kidneys was found in all eight patients.

One tumore had irregular, partial rim calcification demonstrable on both CT and US (Fig. 7).

Table 4. CT findings in renal cell carcinoma. (9 tumors in 8 patients).

Outline:		
	well-defined	9 tumors
	poorly-defined	0 tumor
Contrast excretion:		8 patients
Sign of intrarenal mass:		8 patients
Density:		
Plain CT:		
	solid, mixed density (mainly slightly more hyperdense than normal renal parenchyma)	6 tumors
	cystic (thick, irregular wall with septation)	3 tumors
CT scan with contrast enhancement		
	solid (inhomogenous enhancement less than normal renal parenchyma, with multiple internal low density areas)	6 tumors
	- with peripheral rim enhancement	4/6 tumors
	- no peripheral rim enhancement	2/6
	cystic, with rim enhancement	3 tumors
Size:		
	Range	5 – 14 × 8 – 17 cm
	Average	8 × 10.4 cm

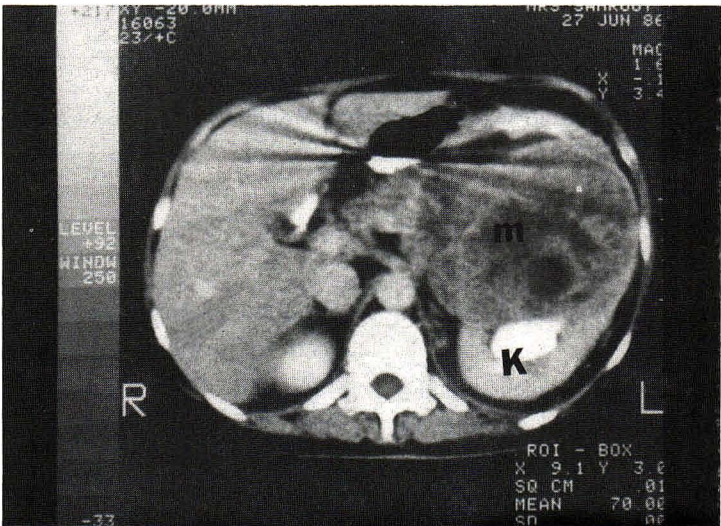


Figure 4. An enhanced axial CT scan shows an inhomogenous enhanced mass (m), with a less than normal renal parenchyma at the hyper pole of the left kidney (K).

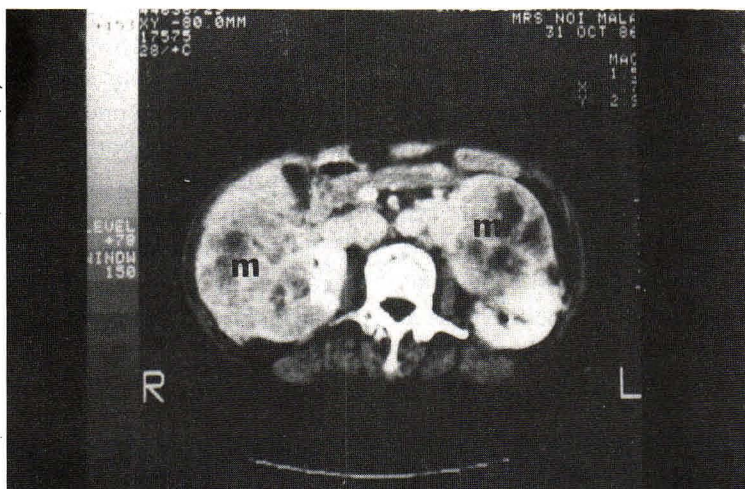


Figure 5. An enhanced axial CT scan shows inhomogeneous enhanced masses in both kidneys (m) with rim enhancement.

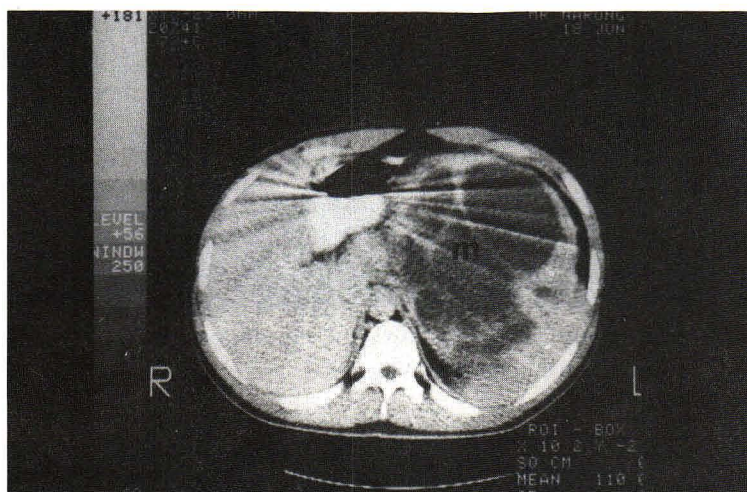


Figure 6. An enhanced axial CT scan shows a thickwalled cystic mass with enhanced cepta and nodular thick wall (m) in the left kidney.

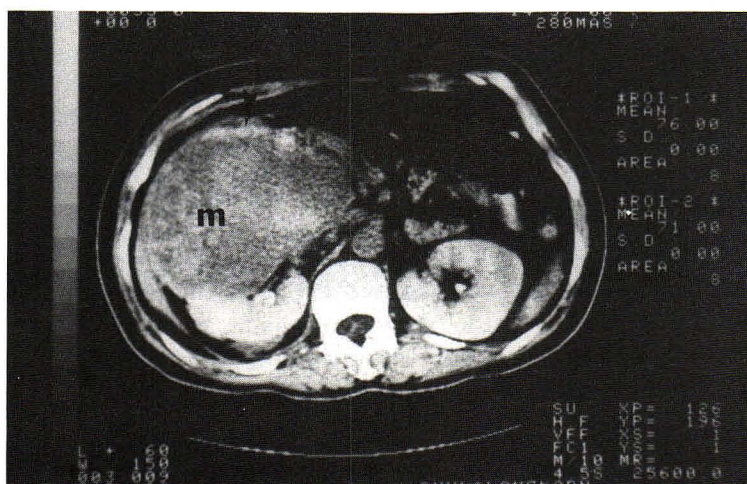


Figure 7. An enhanced axial CT scan shows an inhomogeneously enhanced mass with irregular rim calcification (arrow head) in the right kidney (m).

CT was superior to US in the detection of tumor extension in our study (Table 5). US showed involvement of the regional lymph node in one patient and of the adrenal gland in one patient. Perinephric extension and Gerota's fascia involvement were demonstrated by CT in four cases (Fig. 8) but were undetectable by US, which represented stage II by the Robson classification⁽¹⁾ (Table 6). Vascular invasion was demonstrated as a low-density filling defect in the renal vein and/or IVC on enhanced scans (Fig. 9); it was seen in five cases, representing

stage IIIa. Enlarged lymph node(s) and paraaortic groups, representing stage IIIb, were detected by both US and CT in one case. Adrenal gland involvement was seen by both US and CT in one case. A false-positive reading for Gerota's fascia involvement occurred in one case that was reported as thickened Gerota's fascia but was proven pathologically to be an intracapsular lesions. Adjacent organ invasion (except for the adrenal gland) was not found in any case.

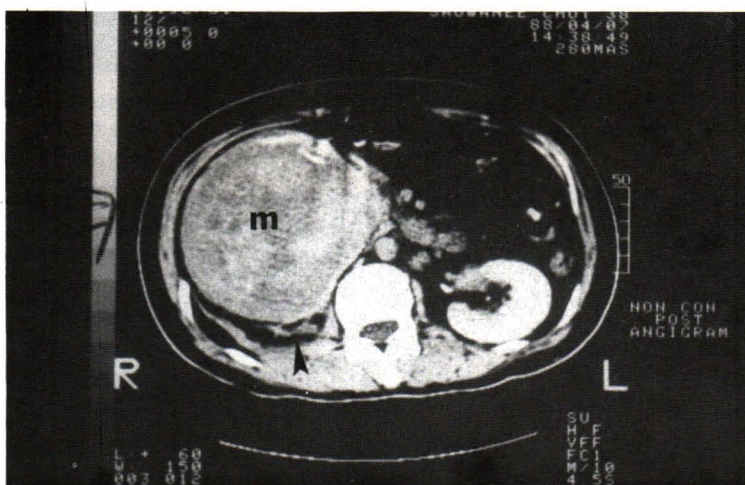


Figure 8. An enhanced axial CT scan shows an inhomogeneously enhanced mass with Gerota's fascia involvement (arrow head) in the right kidney (m).

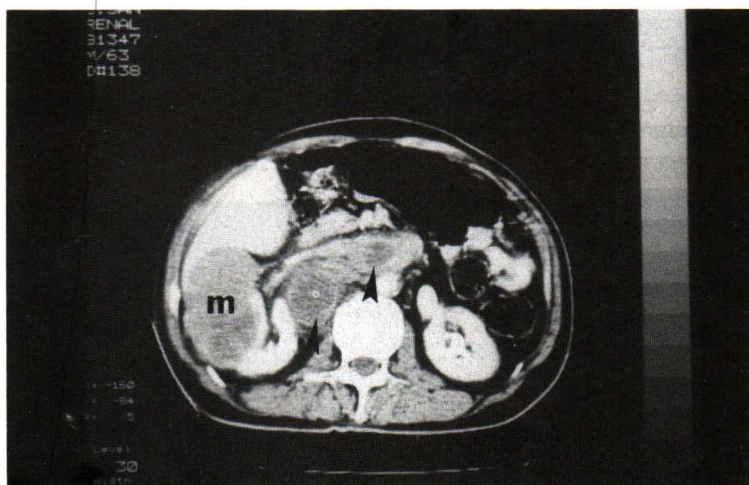


Figure 9. An enhanced axial CT scan shows an inhomogeneously enhanced mass in the right kidney (m); the mass has low-density filling defects (arrow heads) in the renal vein and inferior vena cava, representing a tumor thrombus.

Discussion

Our patients were predominantly female (7 out of 10). The average age was above 50 years (51

years). The lesions were common in the upper pole of the kidney (5 out of 11) and of equal distribution in the right and left kidney. Bilateral tumors were

found in one patient (1 out of 10). Cases of simultaneous bilateral renal cell carcinoma have been reported,^(2,3) the overall incidence of which has been estimated at 5%.⁽²⁾ The average size of the tumor masses was about 8×10.4 cm by CT and 6.6×9.2 cm by US. The clinical presentations were of the clinical triad of renal cell carcinoma, namely flank pain, a palpable abdominal mass and hematuria.⁽⁴⁾ Fever was noted in two patients, one of whom had acute pyelonephritis with multiple calyceal stones. The other patient had fever, which was likely to have been a systemic effect of the tumor.⁽²⁾ This sign could lead a clinician to misinterpret a lesion in the kidney as an abscess rather than a tumor.

Renal cell carcinoma is the most common malignant neoplasm of the adult kidney.⁽⁴⁾ The appearance in US and CT is rather characteristic of an intra-renal mass causing compression and distortion of the renal contour and the collecting system⁽⁵⁾ with preserved excretory function. US findings of most tumors in our patients showed a well-defined outline (9 out of 10 tumors). Six of the 10 tumors had mixed echogenicity, with some cystic components representing areas of necrosis, hemorrhage or tumor vascularity.⁽⁶⁾ Multiple hyperechoic masses in one kidney were another uncommon feature which also had been reported in the other study.⁽⁶⁾ Three tumors showed thick-walled cysts with thick septation and growth projections containing internal bright echoes.

Characteristic US findings of renal cell carcinoma were an irregular mass of mixed echogenicity as found in the majority of cases in our study, with occasionally internal calcification.⁽⁴⁾ However, in US, a wide range of appearance of renal cell carcinoma has also been reported. A poorly defined, low echoic mass without acoustic transmission was indistinguishable between oncocytoma and typical renal cell carcinoma.⁽⁶⁾ Also transitional cell carcinoma, except for its central location near the renal pelvis, was similar to renal cell carcinoma.⁽⁶⁾ A renal abscess could also give the appearance of both a cystic or a mixed echoic solid mass;⁽⁶⁾ misdiagnosis would be possible,⁽²⁾ especially when a patient has pyrexia. Needled aspiration and biopsy might yield a proper result.

CT findings characteristic of renal cell carcinoma are generally accepted as follows:^(8,9)

1. Attenuation coefficient close to that of the renal parenchyma and often heterogeneous.
2. Definite contrast enhancement, but usually less than the normal renal parenchyma.

Transient, marked enhancement frequently seen during the vascular phase after bolus injection.

3. A lack of sharpness at the interface with the surrounding parenchyma.

4. Secondary characteristics such as enlargement of the renal vein or regional lymph nodes, nodular area of soft tissue attenuation within the perinephric space, gross invasion of the IVC or involvement of the main renal vein.

In our study, six out of nine tumors were solid and had characteristic CT findings, as described above, except for a well-defined margin. Four of the six had peripheral rim enhancement. The differential diagnosis included inflammatory mass, other malignant tumor, or hematoma.⁽⁸⁾ These were problems especially when clinical presentation suggested a non-neoplastic process, including fever, renal calculi, recent trauma and/or young age. Careful ultrasound for guiding the puncture of a cyst or mass was the procedure of choice for all lesions which were undetermined by CT.⁽⁸⁾ In such situations, it was generally accepted that angiograms yield no further information.⁽¹⁰⁾

Three of six tumors had a cystic form with the same appearance of a thick, irregular wall with thick septa and small nodules. Contrast-enhanced CT scan showed rim enhancement and also enhanced septa and nodules.

The accuracy of CT in the diagnosis of simple renal cysts approaches 100% using the following criteria.^(8,9)

1. Homogenous, low attenuation value (near density of water).
2. An indiscernible wall.
3. Sharp delineation from the surrounding renal parenchyma.
4. Lack of enhancement following intravenous contrast infusion.

The cystic masses in our series fit the criteria of complicated cysts^(4,8) including thick-wall, peripheral calcification, an attenuation value higher than that of a benign cyst (30-60 HU), irregular contour and poor delineation from the surrounding tissue and/or multilocular structure. The differential diagnosis of this group included cystic carcinoma, hemorrhagic cyst, infected cyst, hydatid cyst, metastasis or MLCN (multilocular cystic nephroma).^(4,8-10) Ultrasound with cyst puncture is recommended in these cases⁽⁹⁾ but it sometimes gives an unsatisfactory result, especially in multilocular lesions. Angiography gives no further information,⁽⁹⁾ except that one

report suggests that its ability to renal encasement of vessels may help in the diagnosis of malignancy.⁽¹⁰⁾ MLCN is a localized cystic tumor of the kidney with a thick wall and septation.⁽¹¹⁾ There are two peaks of presentation, the first peak being predominant in boys under the age of four years and the second peak being female predilection in adults.⁽¹²⁾ Appearances in US and CT make it difficult, and sometimes impossible, to differentiate MLCN from cystic renal cell carcinoma.^(11,13,17)

A combination of other secondary findings of tumor invasion or metastasis (as described later) as well as clinical data may be helpful in reaching the final diagnosis.

In the preoperative staging of renal cell carcinoma, multiple images were reviewed to determine which were the most useful and accurate. A large series of CT stagings of 100 tumors found that overall staging accuracy was 91%.⁽¹⁸⁾ Regardless of tumor stage, the lowest sensitivity was of perinephric extension (46%) following criteria of at least 1 cm of soft tissue mass in the perirenal space and specificity of 98%.⁽¹⁸⁾ For detection of venous invasion, dynamic CT and angiography provide equal accuracy,^(18,19) but CT is more accurate and sensitive than angiography in the evaluation of tumor extension and regional lymphnode involvement.⁽¹⁹⁾

Magnetic Resonance Imaging (MRI) reveal that the most common appearance of renal cell carcinoma was a mass with an intensity intermediated between the renal cortex and medulla of T1-weighted images and hyperintensity of T2-weighted images. MR was similar to CT in staging renal cell carcinoma. Neither CT or MR was reliable in differentiating stage I from stage II lesions. MR was superior in detecting vessel involvement without the use of contrast material.⁽²⁰⁾

Conclusion

Renal cell carcinoma could be found either as a solid or cystic mass. In solid form, both CT and US features are characteristic of a mass of inhomogeneous density or echogenicity, probably with some cystic areas representing necrosis or hemorrhage. Sometimes the mass may contain irregular calcification. The cystic form is a less common feature with evidence of a thick irregular wall, septation or nodular growth projection. Furthermore, CT a more helpful and accurate than US for tumor staging.

References

1. Robson CJ, Churchill BM, Anderson W. The results of radical nephrectomy for renal cell carcinoma. *J Urol* 1969 Mar; 101(3): 297-301
2. Van Poppel H, Vereecken RL, Wilms G. Bilateral renal cell carcinoma diagnosis as renal abscesses. *Urology* 1985 May; 26(5): 548-50
3. Coleman BG, Arger PH, Mulhern CB Jr., Pollack HM, Banner MP, Arenson RL. Gray-scale sonographic spectrum of hypernephromas. *Radiology* 1980 Dec; 137(3): 757-65
4. Tillotson CL, Tillotson PB, DeLuca SA. Imaging of renal masses. *Am Fam Physician* 1987 Jan; 35(1): 199-202
5. Maklad NF, Chuang VP, Doust BD, Cho KJ, Curran JE. Ultrasonic characteristic of solid renal lesions: echographic, angiographic and pathologic correlation. *Radiology* 1977 Jun; 123(3): 733-9
6. Charboneau JW, Hattery RR, Ernst EC 3d., James ME, Williamson B Jr., Hartman GW. Spectrum of sonographic findings in 125 renal masses other than benign simple cyst. *AJR* 1983 Jan; 140(1): 87-94
7. Jordan GH, Hartman DS, Ladaga LE, Schellhammer PF. Large renal masses in young adults. *Urology* 1986 Oct; 28(4): 330-7
8. Balfe DM, McClennan BL, Stanley RJ, Weyman PJ, Sagel SS. Evaluation of renal masses considered indeterminate on computed tomography. *Radiology* 1982 Feb; 142(2): 421-8
9. Mauro MA, Balfe DM, Stanley RJ, Weyman PJ, Lee JKT, McClennan BL. Computed tomography in the diagnosis and management of the renal mass. *JAMA* 1982 Dec 3; 248(21): 2894-6
10. Laperriere J, Filion R, Houde M, Charghi A. Renal cell carcinoma presenting as multilocular cystic mass. *Urology* 1986 Aug; 28(2): 155-8
11. Mauro MA, Wadsworth DE, Stanley RJ, McClennan BL. Renal cell carcinoma: angiography in the CT area. *AJR* 1982 Dec; 139(6): 1135-8
12. Madewell JE, Goldman SM, Davis CJ Jr., Hartman DS, Feigin DS, Lichtenstein JE. Multilocular cystic nephroma: a radiographic-pathologic correlation of 58 patients. *Radiology* 1983 Feb; 146(2): 309-21
13. Feldberg MAM, van Waes PFGM. Multilocular cystic renal cell carcinoma. *AJR* 1982 May; 138(5): 953-5
14. Hartman DS, Davis CJ Jr, John T, Goldman SM. Cystic renal cell carcinoma. *Urology* 1986 Aug; 28(2): 145-53

15. Parienty RA, Pradel J, Imbert MC, Picard JD, Savart P. Computed tomography of multilocular cystic nephroma. *Radiology* 1981 Jul; 140(1): 135-9
16. Parienty RA, Pradel J, Parienty I. Cystic renal cancer: CT characteristics. *Radiology* 1985 Dec; 157(3): 741-4
17. Wills JS. Cystic adenocarcinoma of the kidney mimicking multilocular renal cyst. *Urol Radiol* 1983; 5(1): 51-3
18. Johnson CD, Dunnick NR, Richard H. Fernando F. Illescas. Renal Adenocarcinoma: CT staging of 100 tumors. *AJR* 1987 Jan; 148(1): 59-63
19. Ueda T, Nishitani H, Kudo H. Comparison of angiography and computed tomography using new morphologic criteria in staging of renal cell carcinoma. *Urology* 1988 Nov; 32(5): 459-64
20. Fein AB, Lee JKT, Balfe DM, Heiken JP, Ling D, Glazer HS, McClennan BL. Diagnosis and staging of renal cell carcinoma: a comparison of MR imaging and CT. *AJR* 1987 Apr; 148(4): 749-53

แก้ไขเพิ่มเติม

จุฬาลงกรณ์เวชสาร ปีที่ 35 ฉบับที่ 10 เดือนตุลาคม 2534 เรื่อง “ลักษณะภาพซีทีสแกน และอัลตราซาวนด์ของ มะเร็งไต” ของ รศ. พญ. เกษร วัชรพงศ์

Table 5. CT and US findings in the detection of tumor extension.

	CT	US
Perinephric extension	4	0
Vessel involvement	5	0
Lymph node enlargement	1	1
Adjacent organ invasion	0	0
Adrenal gland invasion**	1	1

**Adrenal gland invasion was not included in stage IVa by the Robson classification.

Table 6. Staging of renal cell carcinoma by Robson classification.

Stage I	The tumor is confined to the renal parenchyma.
Stage II	The tumor extends into the perinephric space but is still within Gerota’s fascia.
Stage IIIa	Involvement of the renal vein or IVC.
IIIb	Involvement of regional lymph nodes.
IIIc	Combination of stage IIIa and IIIb.
Stage IVa	Involvement of adjacent organs (except for the adrenal glands).
Stage IVb	Distance metastasis.

ขออภัยมา ณ ที่นี้ด้วย

บรรณาธิการ