

11-1-1991

The infected vascular graft

Suvit Sriussadaporn

Follow this and additional works at: <https://digital.car.chula.ac.th/clmjournal>



Part of the [Medicine and Health Sciences Commons](#)

Recommended Citation

Sriussadaporn, Suvit (1991) "The infected vascular graft," *Chulalongkorn Medical Journal*: Vol. 35: Iss. 11, Article 8.

Available at: <https://digital.car.chula.ac.th/clmjournal/vol35/iss11/8>

This Review Article is brought to you for free and open access by the Chulalongkorn Journal Online (CUJO) at Chula Digital Collections. It has been accepted for inclusion in Chulalongkorn Medical Journal by an authorized editor of Chula Digital Collections. For more information, please contact ChulaDC@car.chula.ac.th.

The infected vascular graft

Suvit Sriussadaporn*

Sriussadaporn S. The infected vascular graft. Chula Med J 1991 Nov; 35 (11): 751-764

In recent years, prosthetic vascular graft has been widely used in vascular reconstructive procedures. Graft infection is a serious complication well known to vascular surgeons. Although the management of this problem is improving, morbidity and mortality are still relatively high. This article is a review of infected vascular graft cases, and the management and prevention of this grave complication.

Key words : Synthetic vascular graft, vascular prosthesis, Infection, A orto-enteric fistula.

Reprint request: Sriussadaporn S. Department of Surgery, Faculty of Medicine, Chulalongkorn University, Bangkok 10330, Thailand.

Received for publication. August 19, 1991.

**สุวิทย์ ศรีอำมพร. ภาวะติดยึดของหลอดเลือดเทียม. จุฬาลงกรณ์เวชสาร 2534 พฤศจิกายน;
35(11) : 751-764**

ในปัจจุบัน มีการใช้หลอดเลือดเทียมอย่างแพร่หลายในศัลยกรรมหลอดเลือด การติดยึดของหลอดเลือดเทียมเป็นภาวะแทรกซ้อนที่อันตรายมาก ผู้ป่วยที่มีการติดยึดของหลอดเลือดเทียมจะมีอัตราตายหรือทุพพลภาพสูงมาก บทความนี้เป็นบทฟื้นฟูวิชาการเกี่ยวกับการติดยึดของหลอดเลือดเทียมที่ครอบคลุมตั้งแต่สมมุติฐานต่าง ๆ ที่อาจเป็นสาเหตุจนถึงแนวทางในการรักษาและป้องกันภาวะติดยึดของหลอดเลือดเทียม

Infection in a prosthetic graft is a serious post-surgical complication and is associated with a high risk of limb loss and death. A major challenge in treating this complication is early and accurate diagnosis of graft infection. Proper surgical management is needed in treating this dreadful complication.

Illustrative case

A 65-year-old man had an aorto-bifemoral bypass graft inserted for claudication 16 years previously. He had been well until he developed vomiting, rigors, pain in his left groin, abscesses in the right upper thigh, right calf and left calf. He had initially been admitted to a local hospital where an infected hematoma was diagnosed and treated with antibiotics. Following that course he again developed a fever and further abscess appeared. A diagnosis of graft infection with septic embolization was made and he was transferred to St. Mary's Hospital, London.

On admission he looked unwell, the pulse rate was 104/min, blood pressure 150/100 mmHg, temperature 37°C. Abdominal examination was unrevealing. There were redness and swelling in his right thigh, right calf and left calf. His hemoglobin level was 13.3 gm/100ml and white blood cell count was 13,300/mm.³ He was brought to the theatre that evening for drainage of his right thigh abscess. Four days later incision and drainage of both calves was carried out. The pus culture grew *Streptococcus milleri* which was sensitive to penicillin and erythromycin.

Indium-111-labelled white blood cell scan revealed minimal increase in activity in the left groin. CT scan demonstrated a small collection of air in the left side of the aorto-bifemoral graft and a large left paranephric abscess. Thus, the diagnosis of aortic graft infection was confirmed. The left paranephric abscess was drained by percutaneous puncture in the Radiologic Department. A few days later, he underwent exploratory laparotomy. It was discovered that he had an aorto-duodenal fistula with a green graft, which was floating in pus. The graft was removed and gentamicin beads were placed in the graft bed. No revascularization was performed owing to the fear of secondary infection of the extra-anatomic bypass graft. The graft culture grew mixed coliform bacteria.

The post-operative course was complicated by necrosis and spreading infection in his left leg at the previously drained wound of the left calf abscess.

Left below-knee amputation, followed by left above-knee amputation, were performed. He was discharged two months after his graft removal and was confined in a wheel chair.

Two months later, he was readmitted electively for revascularization of his right lower extremity which was severely ischemic after his aorto-bifemoral graft excision. Right axillofemoral dacron bypass was performed. He made an uneventful recovery and was discharged 10 days after the operation.

Three years later, he underwent graft thrombectomy and vein patch at the femoral anastomosis of his right axillo-femoral bypass graft because of graft occlusion from neo-intimal hyperplasia.

It has been five years since his aorto-bifemoral graft infection. His right axillo-femoral graft is still in good condition. He is fully rehabilitated.

Incidence

The incidence of infected vascular graft ranges from 0.77% to 7%.⁽¹⁻⁴⁾ Aortic graft has a lower incidence of infection than peripheral graft. Of the 838 patients who survived aortic graft implantation at St. Mary's Hospital from 1980 to 1989, 11(1.3%) developed graft infection while six out of 165 femoro-popliteal or femoro-distal grafts (3.6%) developed graft infection.

General considerations

Synthetic vascular grafts most often used today are a variety of dacron or polytetrafluoroethylene (PTFE). Healing of the graft begins shortly after implantation. The ultimate outcome is endothelial lining of the inner surface and fibrous capsule formation surrounding the graft. Endothelial lining of the graft lumen has been claimed to be bacteriologically resistant and its formation increases with time.⁽⁵⁾ Although the completeness of the endothelial lining has been demonstrated in animal models, this has never been achieved in humans.^(6,7) Incompleteness of the pseudointimal lining may be responsible for late hematogenous graft infection.

Microbiology

Staphylococcus aureus is the most common cause of infected vascular grafts reported in most series. Other organisms frequently found are *Escherichia coli*, *Klebsiella*, *Pseudomonas*, *Proteus*, *Enterobacter* and *Streptococcus*. Infection

by anaerobic organisms is not rare.⁽⁸⁾ The common anaerobic organisms responsible for infected vascular grafts are *Bacteroides* and anaerobic gram positive cocci. Recently, *Staphylococcus epidermidis*, which

is a coagulase-negative *Staphylococcus* and is less virulent than *Staphylococcus aureus*, has been reported to play an important role in early and late prosthetic graft infection.^(9,10,11)

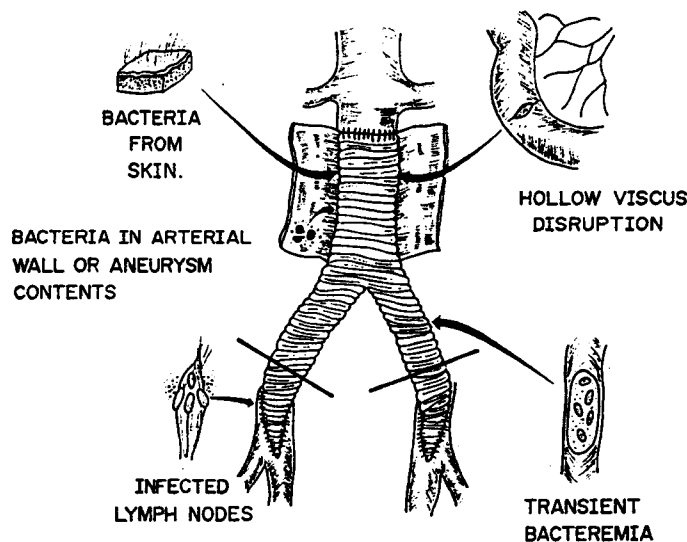


Figure 1. Sources of graft infection.

Sources of infection (Figure 1)

The skin is a predominant source of infection of prosthetic grafts. Most staphylococcal and anaerobic infections come from skin contamination at the time of surgery. Infection caused by Gram-negative bacilli and anaerobic organisms usually comes from hollow viscus directly or probably from lymphatic channels that were severed during surgery. Organisms that are harbored in the aortic aneurysm wall may spread to the aortic graft and cause aortic graft infection. Positive bacterial cultures from the aneurysm contents have been reported to be associated with a significant increase in the incidence of prosthetic graft infection.^(1,2,12,13)

Vascular surgeons are familiar with patients who present with an infected toe or foot. Under such circumstances, organisms may spread via lymphatic channels and cause contamination of the inguinal lymph nodes. Dissecting and placement of a prosthetic graft in this area without pre-treatment with antibiotics may jeopardize the graft by exposing it to the risk of infection. Lastly, transient bacteremia from any source has been postulated to be a possible cause of graft infection.⁽¹⁴⁾

Pathogenesis of the prosthetic graft infection

Prosthetic grafts are foreign bodies which are inert and possess a high tendency to become infected when they are contaminated. Tissue injury can often be coped with by host defenses even when challenged with a large inoculation of bacteria. In the presence of a foreign body, the ability of the immune system to eradicate the microorganisms is hampered by various mechanisms.

Once the bacteria are implanted into the interstices of the prosthetic graft, colonization begins. Colonization is protected by the interstices of the foreign body and by a locally deranged immune system. The adherent bacteria can survive and eventually flourish. The process continues as long as the graft is still in place. Systemic antibiotics or surgical drainage without graft removal usually fails to halt this catastrophic event.

Consequences of the infected vascular graft

Once the graft has been infected, the following events may occur:

1. Sepsis

Patients with infected grafts may present with full blown clinical manifestations of systemic sepsis or chronic indolent course. The latter is commonly associated with healing complications, i.e., anastomosis aneurysm, graft-enteric fistula and absence of graft incorporation by the surrounding tissue. In our experience at St. Mary's Hospital, 37% (11 of 29) of patients who had an infected aortic graft presented with clinical evidences of systemic sepsis.

2. Wound discharge and graft-cutaneous sinus tract

This is often seen when the infection involves one limb of the aorto-femoral graft. Turbid fluid or pus-like material may come out from a groin wound. In the chronic stage, persistent drainage

from a sinus tract in the groin usually indicates a communication between the skin and underlying prosthetic graft.

3. False aneurysm formation

When the infection involves anastomosis, the arterial wall at the anastomotic site is destroyed. This leads to false aneurysm formation. False aneurysm in the groin is easy to detect, but false aneurysm in the abdomen is more subtle and usually present with a more complicated clinical problem such as gastrointestinal bleeding due to graft-enteric fistula. At St. Mary's Hospital, 17.2% (5 of 29) of patients with infected aortic graft presented with a false aneurysm in the groin.

4. Aorto-enteric fistula and erosion (Figures 2 and 3)

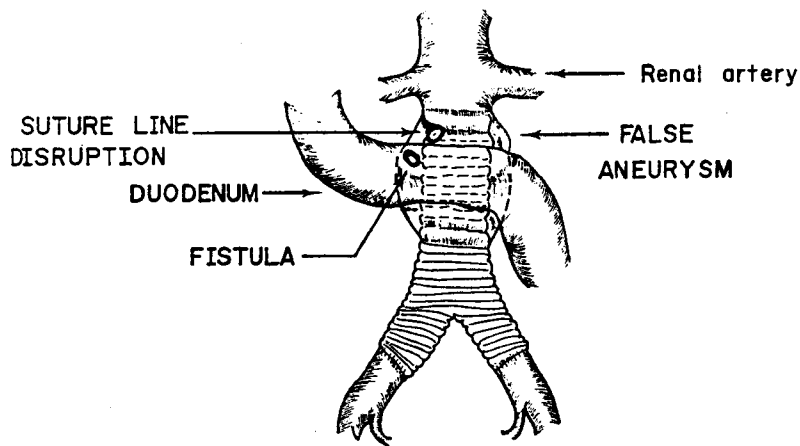


Figure 2. Graft - enteric fistula.

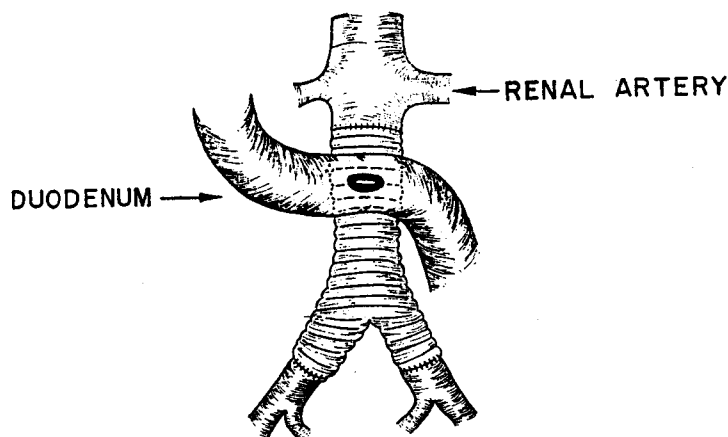


Figure 3. Graft - enteric erosion.

False aneurysm in the abdomen may erode into the bowel, resulting in aorto-enteric fistula. The duodenum is the most common site of fistula; the fistula usually communicates with the proximal anastomosis of the aortic graft. In some circumstances, there is an false aneurysm formation, but the bowel adheres to the body of the aortic graft. This leads to graft-enteric erosion. Adherence of the bowel wall to the graft surface prevents leakage of the intestinal contents while the fibrous capsule surrounding the graft is being digested. Low grade sepsis and minimal gastrointestinal bleeding are the usual manifestations of this graft-enteric erosion. In our experience with aortic graft infection at St. Mary's Hospital, 55.2% (16/29) had graft-enteric fistula and 10.3% (3/29) had graft-enteric erosion.

5. Miscellaneous

Obstruction of the ureter by false aneurysm and fistula between the false aneurysm and the inferior vena cava have been found on some occasions.

Presentation of the infected vascular graft

Graft infection is obvious when a patient presents with an infected wound, pus drainage or sinus tract communicated with the implanted graft. This is commonly seen in the groin where an aorto-femoral or femoro-femoral or femoro-popliteal or axillo-femoral graft has been placed.

Gastrointestinal bleeding from aorto-enteric fistula or graft enteric erosion is one of the most common and serious presentations of the infected aortic graft. Patients may present with hematemesis or melena and sometimes with anemia from chronic blood loss. The bleeding may be minimal and self limited at the early stage only to exsanguinate sometime later. Although infected grafts are a relatively rare cause of gastrointestinal bleeding compared with the more common causes such as acute gastro-duodenal erosion, peptic ulcer and esophageal varices,⁽¹⁵⁾ gastrointestinal bleeding in patients with an aortic graft in the abdomen means aorto-enteric fistula until proven otherwise. At St. Mary's Hospital, 41.4% (12/29) of patients who had an infected aortic graft presented with gastrointestinal bleeding.

Full-blown systemic sepsis after graft implantation is strongly suggestive of graft infection. However, it is not infrequent to see a patient with an infected graft who has no systemic manifestation of sepsis. The patients may present with a prolonged

low grade pyrexia and sometimes together with non-specific symptoms such as vague abdominal pain, weight loss, back pain and groin pain. Some patients had been diagnosed with pyrexia of unknown origin (PUO) until the ultimate process of infection occurred (e.g. gastrointestinal bleeding from aorto-enteric fistula). Graft infection should be considered in a patient who is unwell after graft implantation, even months or years after the operation.

False aneurysm in the groin with or without systemic manifestations of sepsis is a common presentation of the infected graft. This has to be differentiated from a sterile false aneurysm caused by anastomotic failure from mechanical causes. On physical examination, a pulsatile mass in the groin, which was the site of a previous anastomosis, is undoubtedly a false aneurysm. A positive Gram's stain or culture for organisms in the aneurysm contents or arterial wall leads to the diagnosis of infected false aneurysm.

Laboratories

Routine laboratory findings in a patient with an infected graft may reveal anemia due to acute or chronic blood loss or prolonged course of low grade sepsis. White blood cell count may be normal or increased. The erythrocyte sedimentation rate is usually increased but is not specific for an infected graft.

Gram's stain and culture of the discharge from the wound or the sinus tract may disclose the responsible organism.

Hemoculture should be routinely performed in a patient in whom graft infection is suspected.

It should not come as a surprise if all the Gram's and cultures are negative for organisms. Studies have shown that some low virulence organisms, such as *Staphylococcus epidermides*, colonize and survive within a biofilm adherent to the prosthetic graft surface. Identification of these organisms may need some specific culture techniques.^(10,16)

Investigations

Gastroduodenal endoscopy

Gastroduodenal endoscopy has been generally accepted as being a routine investigation in a patient who has gastrointestinal bleeding. When aorto-duodenal fistula is suspected, a long flexible endoscope should be used to visualize the third and fourth parts of the duodenum which are most common sites of aorto-enteric fistula.⁽¹⁷⁾ The

diagnosis of aorto-duodenal fistula is made when endoscopy demonstrates 1) a vascular prosthesis in the duodenal lumen, 2) arterial bleeding in the second or third part of the duodenum, 3) a pulsatile structure in the wall or lumen of the duodenum, 4) a suture line, or 5) a bile-stained structure in a patient who has had an aortic graft implantation.^(17,19)

The sensitivity of endoscopy in the diagnosis of aorto-duodenal fistula has been reported as being from 60% to 70%.^(18,19) Although our result at St. Mary's Hospital is disappointing (positive test in 1 of the 11 patients (9.1%) who had aortoenteric fistula), endoscopy should still be used when feasible. The major purpose of endoscopy is to rule out other possible causes of gastrointestinal bleeding.

Indium-111-labeled white blood cell scan

This test has been commonly used as an adjunctive investigation to detect graft infection in recent years. The sensitivity has been reported to be as high as 100%, but specificity is relatively low (50%-85%).⁽²⁰⁻²²⁾ Indium-111-labeled white blood cell scan also gives a false-positive result in the non-infectious inflammatory process and in the early post-operative period.⁽²²⁾ The test should be used as a screening method in a patient in whom the graft infection is suspected and the diagnosis of graft infection should be confirmed by other investigations.

Angiography

Angiography is seldom used to diagnose graft infection because the result is not so encouraging as other investigation such as CT scan.⁽²³⁾ However, angiography can give some indirect evidence of graft infection (e.g., false aneurysm, graft occlusion). Angiography is quite insensitive in the diagnosis of aorto-enteric fistula.^(17,19) When the diagnosis of graft infection has been made, angiography may be helpful in the planning of the surgical management of the renal artery at the aortic false aneurysm or outlining the vascular trees for reconstructive procedures.

CT scan

CT scan is currently probably the most accurate diagnostic tool for the diagnosis of aortic graft infection, which usually involves the retroperitoneal area and is difficult to diagnose by other means. The appearance of perigraft fluid or air in CT scans is strongly suggestive of graft infection. Normally, perigraft fluid may be seen

up to six weeks and air may be presented during the first two weeks after the operation.^(23,24) Any fluid or air or both, appearing on a CT scan after six weeks and two weeks, respectively, should be considered highly suspicious of graft infection. CT scan has been reported to be superior to angiography and Indium-111-labeled white blood cell scan for the diagnosis of graft infection.^(25,26) The introduction of CT-guided periaortic fluid aspiration in suspected cases of aortic graft infection has increased the accuracy of diagnosis.^(27,28) Recovery of organisms in the periaortic aspirated fluid is virtually pathognomonic of an aortic graft infection.

Magnetic Resonance Imaging (MRI)

Recently, magnetic resonance imaging has been shown to be useful in the diagnosis of aortic graft infection.^(29,30) The diagnosis of graft infection is considered on the basis of MRI identification of perigraft fluid. However, in the early post operative period, MRI cannot differentiate between infected and sterile fluid. The applicability of this modern imaging technique will have to be verified before it is generally accepted as an investigation of choice in the diagnosis of the aortic graft infection.

Management of the infected graft

Once the diagnosis of graft infection is made, the ideal treatment is to remove the infected graft and to revascularize the distal limbs to prevent ischemia. Less aggressive management, such as closure of aorto-enteric fistula and local wound irrigation, has been reported with variable success.

When graft infection is suspected, systemic antibiotics should be started immediately. Broad spectrum antibiotics are given to the patient when the responsible organism has not been identified and specific antibiotics given when culture sensitivity is available.

Conservative management

1. Local wound irrigation with antibiotics or antiseptic solution

This treatment modality has been reported with satisfactory outcome.⁽³¹⁻³³⁾ Most of the successfully reported cases are the infected grafts in the groin. Usually, the graft is exposed in the bed of the infected wound. The prerequisite conditions are that the graft still be patent and the infection localized to the exposed segment of the

graft. All the necrotic tissue in the wound and surrounding the graft must be debrided. The antiseptic recommended is povidone-iodine solution delivered either by a colostomy bag apparatus⁽³²⁾ or by packing the wound with gauze soaked in a half-strength povidone-iodine solution.⁽³³⁾ The wound is left open and irrigated with the povidone-iodine solution until the graft and the wound bed are covered with granulation tissue. The wound may be left to heal spontaneously or may be closed by secondary wound closure. This technique requires meticulous wound care and prolonged hospitalization.

2. Direct closure of aorto-enteric fistula

This technique is performed by identification of the fistula site which is usually located between the duodenum or small bowel and the proximal anastomosis of the aortic graft. The bowel is then separated from the aortic anastomosis after the clamps have been placed to control the proximal and distal aorta. The bowel defect is then closed and the defect at the aortic anastomosis is closed primarily or revised or closed with a synthetic patch. The bowel may be separated from the new aortic anastomosis by some viable tissue such as omentum. This less aggressive treatment is proposed to avoid a more radical operation, i.e., aortic graft removal. Unfortunately, the infection still remains and results in high morbidity and

mortality due to sepsis or recurrent fistula.^(19,34) Direct closure of the aorto-enteric fistula is seldom used at present. In our experience, we had three patients who had had a failed direct closure of an aorto-enteric fistula. All of them underwent subsequent graft removal and extra-anatomic bypass grafting.

3. Removal of the infected graft and replacement of a new graft *in situ*

This technique is performed by removal of some part or the whole graft and a new graft is placed *in situ* to revascularize the distal limbs. Some success has been reported.^(34,35) The reason for a new graft *in situ* is to avoid a prolonged operation of revascularization by extra-anatomic bypass and to avoid the complication of aortic stump. There must be no obvious active infection in the newly placed graft bed and the organisms, if known, should be of low virulence. This treatment modality is not generally accepted because the potential risk of infection still remains.⁽⁴⁾ In our experience, we had three successful cases by this method and two failures that required graft removal and extra-anatomic bypass.

Radical Treatment

Excision of the infected graft and extra-anatomic bypass (Figure 4)

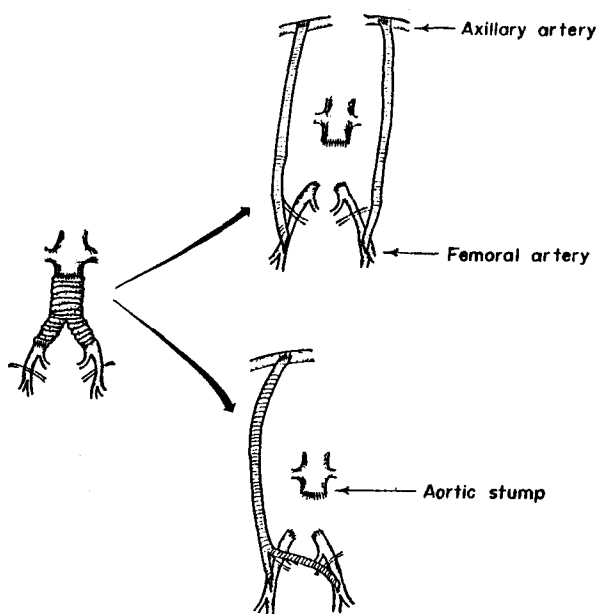


Figure 4. Graft removal with extra-anatomic bypass.

This logical treatment is generally practiced with less morbidity and mortality than the more conservative procedures mentioned in the preceding section.^(1,2,4,19) Extra anatomic bypass is a procedure to revascularize the distal limbs by placing a new graft in a new clean tissue plane thus avoiding the placement of a new graft in the old infected bed. In aorto-iliac graft infection, the whole graft is removed and the lower limbs are revascularized by axillofemoral bypass.

In aorto-femoral graft infection, if the infection involve the whole graft, it must be removed as in an aorto-iliac graft infection. If one limb of the aorto-femoral graft is involved and the infection does not extend to the abdominal part of the graft, only the infected limb may be excised and revascularization may be performed by obturator bypass or from an axillary artery to distal superficial femoral artery or popliteal artery to avoid the infected groin wound (Figure 5).

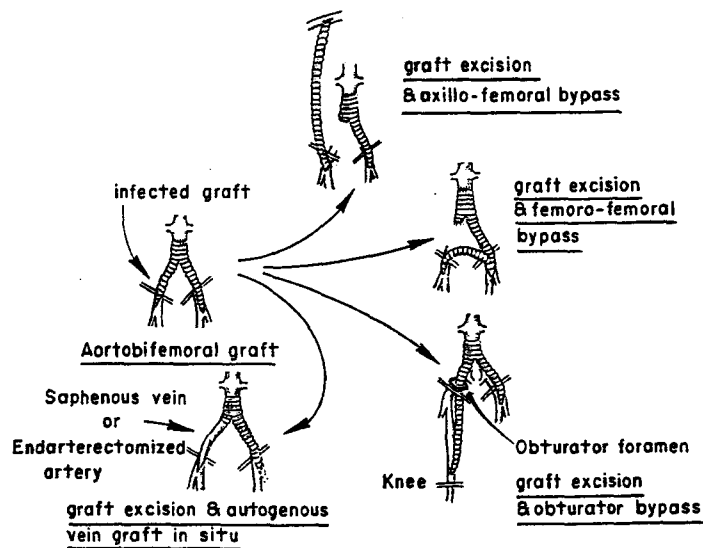


Figure 5. Treatment of infected graft limited to one limb of aortobifemoral graft.

Aortic stump blow-out is one of the most serious complications after infected aortic graft has been removed. Before closure of the aortic stump is performed, the infected aorta must be debrided to the clean, normal appearing aorta. After the aortic stump has been closed, some vascular surgeons advocate the use of vascularized tissue to protect the stump (e.g., cover the stump with submucosal mesenteric pedicled graft)^(36,37) (Figure 6).

We usually place a chain of gentamicin beads into the bed of the infected graft to increase the tissue level of the drug without interfering with renal function. (Figure 7)

The commonly used extra-anatomic bypass, which is the axillofemoral bypass, may be performed

before or after the infected aortic graft is removed in one setting. Stage operation, i.e., the axillofemoral bypass is performed first and then the infected graft is removed a few days later, has been reported with satisfactory outcome.^(4,38)

In some circumstances, it is unavoidable to put a new graft into the infected area. Synthetic grafting is too dangerous in this situation. Revascularization by autogenous saphenous vein has been reported with encouraging results.⁽³⁹⁻⁴¹⁾ (Figure 5)

In cases of infected peripheral graft such as femoro-popliteal graft or axillo-femoral graft, graft removal should be performed. Revascularization is usually problematic. Other routes of bypass may be attempted, but sometimes amputation is inevitable.

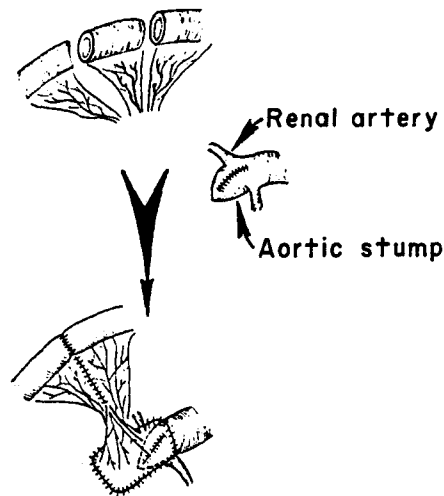


Figure 6. Protection of the infected aortic stump: submucosal mesenteric pedicle graft.

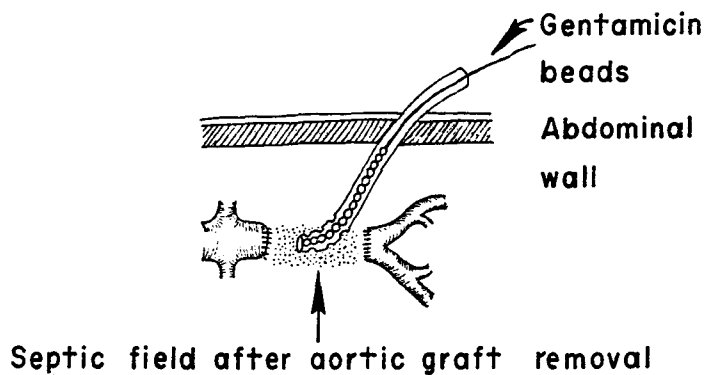


Figure 7. Intraperitoneal placement of gentamicin beads in the management of prosthetic graft sepsis.

Results

For aortic graft infection, the mortality rate ranges from 14% to 77%.^(1,2,4,9,17,19,42) Mortality has tended to improve in recent reports,^(9,42) Improvement in diagnostic modalities and operative strategies, more effective antibiotics, better anesthesia and monitoring techniques, advancement in intensive care are all responsible for the decrease in the mortality rate due to aortic graft infection. The amputation rate in aortic graft infection ranges from 11% to 57%.^(1,2,4,18,42)

In femoro-popliteal graft infection, there is a lower mortality rate than in aortic graft infection (0-22%). However, the amputation rate is higher (50%-79%).^(1,2,4,3)

Few reports provide information about the incidence of subsequent infection of the extra-anatomic bypass graft following aortic graft removal. One report from Portland, Oregon (9) had an infection rate of 22% for axillo-femoral bypass graft.

At St. Mary's Hospital, the mortality rate following aortic graft infection was 24% (8/33) and the amputation rate was 20% (5/25). The rate of subsequent infection of the axillo-femoral graft was 22.2% (4/18).

Prevention of synthetic graft infection

When vascular reconstruction is considered, every effort should be attempted to prevent graft infection. Prevention of synthetic graft infection

begins from the pre-operative period throughout the operative and post-operative period.

1. Treat pre-existing infection

Candidate for elective graft implantation should possess no potential source of infection that would contaminate the graft during operation either by direct contamination, hematogenous spread or lymphatic spread. Any skin infection or respiratory tract infection should be treated with proper antibiotics. Toe or foot gangrene, which is commonly seen in peripheral vascular disease, should be treated with antibiotics to decrease contamination of the inguinal lymph nodes before the reconstructive surgery is performed.

2. Prophylactic antibiotics

Although most vascular reconstructive procedures are clean surgical procedures, antibiotic prophylaxis is recommended to prevent any infection which, if it occurs, is usually severe or fatal.

Antibiotic prophylaxis has been shown to reduce the incidence of the prosthetic graft infection.^(2,3,44) The antibiotics chosen should cover the predominant pathogens that are responsible for prosthetic graft infection (e.g., *Staphylococcus* and *Streptococcus* and Gram-negative enteric bacteria). Cephalosporin has been the most common agent used in the prophylaxis of graft infection in vascular surgery.^(3,44,45) Prophylactic antibiotics should be administered immediately before the operation, during the operation and in the early post-operative period.

During the operation, prophylactic antibiotics should be given every four to six hours or more frequently to maintain the blood and tissue level of antibiotics against the organisms.⁽⁴⁶⁾

Post-operatively, prophylactic antibiotics should be given until all monitoring lines which may be the source of transient bacteremia are removed, which is usually 4-5 days. In patients who have positive cultures from the arterial wall or from the contents of the arterial lumen, prophylactic antibiotics may have to be continued for a longer period of time, which may be up to eight weeks.⁽⁴⁷⁻⁴⁹⁾

The risk of graft infection still remains even years after the operation due to the incompleteness of the pseudointimal lining.^(5,6) Thus, it is reasonable to consider prophylactic antibiotics when procedures that may cause transient bacteremia, such as urinary bladder catheterization, or tooth extraction, are performed in those who have a prosthetic graft in their bodies.

3. Prevention during operation

As in every surgical procedure, sterile technique in every step is of the utmost importance. The prosthetic graft should not come into contact with the skin. The skin may be draped with a plastic sheet. A thrombus in the aneurysm sac should be routinely sent for culture. Any potential source of infections, including the arterial wall if suspected, should also be sent for culture.

If infection is strongly suspected in the vascular reconstructive field, implantation with a prosthetic graft should be avoided. Revascularization may be carried out by using autogenous vein or endarterectomized artery in the infected bed. Sometimes, extra-anatomic bypass may have to be considered, for example, in the case of an infected aortic aneurysm.

In aortic graft implantation, the graft should be covered with the aneurysm sac and/or peritoneum to prevent adhesion between the bowel and the graft that may cause graft-enteric erosion and subsequent graft infection.

Lymphatic leakage in the groin has been shown to be associated with acute graft infection.⁽⁵⁰⁾ Careful transection and ligation of the inguinal lymphatics may minimize this complication. Groin wounds should be closed with meticulous care.

Recent development of the antibiotic-bonded vascular graft may play an important role in decreasing the incidence of the prosthetic graft infection in the future.^(51,52)

Conclusion

Prosthetic graft infection is a relatively rare complication of vascular reconstructive surgery. However, the serious consequences of this catastrophic event make it worthwhile for the vascular surgeon to prevent its occurrence. The predominant organisms responsible for the infected graft are *Staphylococcus aureus*, *Staphylococcus epidermidis*, *Streptococcus* and Gram negative enteric bacteria. Systemic sepsis, wound discharge, false aneurysm in the groin and gastrointestinal bleeding from aorto enteric fistula are the major presentations. CT scan and Indium-111 labeled white blood cell scan are valuable diagnostic tools. Standard treatment is excision of the infected graft and revascularization of the distal limbs by extraanatomic bypass. Management may be varied according to circumstances. Prophylactic antibiotics play an important role in the prevention

of prosthetic graft infection. Prophylactic antibiotics should be administered immediately before the operation, throughout the operation until early post operative period. Prophylactic antibiotics should also be considered when patients with a prosthetic graft implantation are at risk of transient bacteremia such as during urinary bladder catheterization or tooth extraction.

Acknowledgements

This article was written while I was a vascular fellow to Miss Averil O. Mansfield, consultant surgeon at the Vascular Unit, St Mary's Hospital, London from February 1990 to January 1991. I would like to thank the Thai Red Cross Society for providing me the fund. I am grateful to Associate Professor Sunitaya Chandraprasert, Associate Professor Tanit Vajrabukka and Miss Averil O. Mansfield for their help and support.

References

1. Szilagyi DE, Smith RF, Elliott JP, Vrandeic MP. Infection in arterial reconstruction with synthetic grafts. *Ann Surg* 1972 Sep; 176(3): 321-33
2. Goldstone J, Moore WS. Infection in vascular prostheses. Clinical manifestations and surgical management. *Am J Surg* 1974 Aug; 128(2): 225-34
3. Kaiser AB, Clayson KR, Mulherin JL Jr, Roach AC, Allen TR, Edwards WH, Dale WA. Antibiotic prophylaxis in vascular surgery. *Ann Surg* 1978 Sep; 188(3): 283-9
4. O'Hara, PJ, Hertzner NR, Beven EG, Krajewski LP. Surgical management of infected abdominal aortic grafts: review of a 25-year experience. *J Vasc Surg* 1986 May; 3(5): 725-31
5. Malone JM, Moore WS, Campagna G, Bean B. Bacteremic infectability of vascular grafts: the influence of pseudointegrity and duration of graft function. *Surgery* 1975 Aug; 78(2): 211-6
6. Berger K, Sauvage LR, Rao AM, Wood SJ. Healing of arterial prostheses in man: its incompleteness. *Ann Surg* 1972 Jan; 175(1): 118-27
7. Zacharias RK, Kirkman TR, Clowes AW. Mechanism of healing in synthetic grafts. *J Vasc Surg* 1986 Nov; 6(5): 429-36
8. Brook I. Role of anaerobic bacteria in aorto femoral graft infection. *Surgery* 1988 Nov; 104(5): 843-5
9. Yeager RA, Moneta GL, Taylor LM, Harris EJ, McConnell DB, Porter JM. Improving survival and limb salvage in patients with aortic graft infection. *Am J Surg* 1990 May; 159(5): 466-9
10. Bergamini TM, Bandyk DF, Govostis D, Vetsch R, Towne JB. Identification of *Staphylococcus epidermidis* vascular graft infections: a comparison of culture techniques. *J Vasc Surg* 1989 May; 9(5): 665-70
11. Martin LF, Harris JM, Fehr DM, Peter AO, Appelbaum PC, Spangler SK, Thiele BL. Vascular prosthetic infection with *Staphylococcus epidermidis*: experimental study of pathogenesis and therapy. *J Vasc Surg* 1989 Mar; 9(3): 464-71
12. Buckels JAC, Field JW, Black J, Ashton F, Slaney G. Significance of positive bacteria cultures from aortic aneurysm contents. *Br J Surg* 1985 Jun; 72(6): 440-2
13. Ernst CB, Campbell HC, Daugherty ME, Sachatello CR, Griffen WO. Incidence and significance of intra-operative bacterial cultures during abdominal aortic aneurysmectomy. *Ann Surg* 1977 Jun; 185(6): 626-30
14. Lepout C, Goeau-Brissonniere O, Lebrault C, Guidoin R, Vilde JL, Bacourt F, Pechere JC. Experimental colonization of a polyester vascular graft with *Staphylococcus aureus*: a quantitative and morphologic study. *J Vasc Surg* 1988 Jul; 8(1): 1-9
15. Pabst TS,^{3d} Bernhard VM, McIntyre KE Jr, Malone JM. Gastrointestinal bleeding after aortic surgery. The role of laparotomy to rule out aortoenteric fistula. *J Vasc Surg* 1988 Sep; 8(3): 280-5
16. Bergamini TM, Bandyk DF, govostis D, Kaebnick HW, Towne JB. Infection of vascular prostheses caused by bacterial biofilms. *J Vasc Surg* 1988 Jan; 7(1): 21-30
17. O'donnell TF Jr, Scott G, Shepard A, Mackey WC, Deterling RA, Callow AD. Improvements in the diagnosis and management of aortoenteric fistula. *Am J Surg* 1985 Apr; 149(4): 481-6
18. Baker MS, Fisher JH, van der Reis L. The endoscopic diagnosis of an aortoduodenal fistula. *Arch Surg* 1976 Mar; 111(3): 304-5
19. Champion MC, Sullivan SN, Coles JC, Goldbach M, Watton WC. Aortoenteric

- fistula. Incidence, presentation recognition, and management. *Ann Surg* 1982 Mar; 195(3): 314-7
20. Lawrence PE, Dries DJ, Alazraki N, Albo D Jr. Indium 111-labeled leukocyte scanning for detection of prosthetic vascular graft infection. *J Vas Surg* 1985 Jan; 2(1): 165-73
 21. Brunner MC, Mitchell RS, Baldwin JC, James DR, Olcott C 4th, Mehigan JT, McDougall IR, Miller DC. Prosthetic graft infection: limitations of indium white blood cell scanning. *J Vasc Surg* 1986 Jan; 3(1): 42-8
 22. Sedwitz MM, Davies RJ, Pretorius HT, Vasquez TE. Indium 111-labeled white blood cell scans after vascular prosthetic reconstruction. *J Vasc Surg* 1987 Nov; 6(5): 476-81
 23. Haaga JR, Baldwin GN, Reich NE, Beven E, Kramer A, Weinstein A, Havrilla TR, Seidemann FE, Namba AH. CT Detection of infected synthetic grafts: preliminary report of a new sign. *Am J Roentgenol* 1978 Aug; 131(2): 317-20
 24. Mark A, Moss AA, Lusby RJ, Kaiser JA. CT evaluation of complication of abdominal aortic surgery. *Radiology* 1982 Nov; 145(2): 409-14
 25. Mark AS, McCarthy SM, Moss AA, Price D. Detection of abdominal aortic graft infection: comparison of CT and In-labeled white blood cell scans. *AJR* 1985 Feb; 144(2): 315-8
 26. Vogelzang RL, Limpert JD, Yao JST. Detection of prosthetic vascular complications: comparison of CT and angiography. *AJR* 1987 Apr; 148(4): 819-23
 27. Rabinovici R, Fieles S, Berlatzky Y, shifrin EG, Romanoff H. CT guided periaortic fluid aspiration diagnosing aortic graft infection. *J Cardiovasc Surg Torino* 1988 Mar-Jun; 29(3): 318-9
 28. Harria KA, Kozak R, Carroll SE, Meads GE, Sweeney JP. Confirmation of infection of an aortic graft. *J Cardiovasc Surg Torino* 1989 Mar-Apr; 30(2): 230-2
 29. Olofsson PA, Auffermann W, Higgins CB, Rabahie GN, Tavares N, Stoney RJ. Diagnosis of prosthetic aortic graft infection by magnetic resonance imaging. *J Vasc Surg* 1988 Aug; 8(2): 99-105
 30. Auffermann W, Olofsson PA, Rabahie GN, Tavares NJ, Stoney RJ, Higgins CB. Incorporation versus infection of retro-peritoneal aortic grafts: MR imaging features. *Radiology* 1989 Aug; 172(2): 359-62
 31. Carter SC, Cohen A, Whelan TJ. Clinical experience with management of the infected dacron graft. *Ann Surg* 1963 Aug; 158(2): 249-55
 32. Kwaan JHM, Connolly JE. Successful management of prosthetic graft infection with continuous povidone-iodine irrigation. *ArchSurg* 1981 May; 116(5): 716-20
 33. Moran KT, Jewell ER. Local antiseptic treatment of infected prosthetic vascular grafts in the groin. *Br J Surg* 1988 Oct; 75(10): 1037-8
 34. Wierman WH, Strahan RW, Spencer JR. Small bowel erosion by synthetic aortic grafts. *Am J Surg* 1966 Nov; 112(5): 791-7
 35. Sorensen S, Lorentzedn JE. Recurrent graft-enteric fistulae. *Eur J Vasc Surg* 1989 Dec; 3(6): 583-5
 36. Shah DM, Buchbinder D, Leather RP, Corson J, Karmody AM. Clinical use of the seromuscular jejunal patch for protection of the infected aortic strump. *Am J Surg* 1983 Aug; 146(20): 198-202
 37. Wolfe JHN, Grigg MJ. Protection of the infected aortic stump: submucosal mesenteric pedicle grafts. *Br J Surg* 1988 Dec; 75(12): 1200
 38. Trout HH^{3d}. Kozloff L, Giordano JM. Priority of revascularization in patients with graft enteric fistulas, infected arteries, or infected arterial prostheses. *Ann Surg* 1984 Jun; 199(6): 669-83
 39. Lorentzen JE, Nielsen OM. Aortobifemoral bypass with autogenous saphenous vein in treatment of paninfected aorticbifurcation graft. *J Vasc Surg* 1986 Apr; 3(4): 666-8
 40. Fowl RJ, Martin KD, Sax HC, Kempczinski RF. Use of autogenous spiral vein grafts for vascular reconstructions in contaminated fields. *J Vasc Surg* 1988; 8: 442-6
 41. Yeager RA, McConnell DB, Sasaki TM, Vetto RM. Aortic and peripheral prosthetic graft infection: differential management and causes of mortality. *Am J Surg* 1985 Jul; 150(1): 36-43
 42. Reilly LM, Stoney RJ, Goldstone J, Ehrenfeld WK. Improved management of aortic graft infection: the influence of operation sequence and staging. *J Vasc Surg* 1987; 5: 421-31
 43. Kikta MJ, Goodson SF, Bishara RA, Meyer JP,

- Schuler JJ, Flanigan DP. Mortality and limb loss with infected infrainguinal bypass grafts. *J Vasc Surg* 1987 Apr; 5(4): 566-71
44. Pitt HA, Postier RG, MacGowan WAL, Frank LW, Surmak AJ, Sitzman JV, Bouchier-Hayes D. Prophylactic antibiotics in vascular surgery: topical, systemic, or both? *Ann Surg* 1980 Sep; 192(3): 356-64
45. Guglielmo BJ, Hohn DC, Koo PJ, Hunt TK, Sweet RL, Conte JE Jr. Antibiotic prophylaxis in surgical procedures: critical analysis of the literature. *Arch Surg* 1983 Aug; 118(8): 943-55
46. Lalka SG, Malone JM, Fisher DF, Jr, Bernhard VM, Sullivan D, Stocckelmann D, Bergstrom RF. Efficacy of prophylactic antibiotics in vascular surgery: an arterial wall microbiologic and pharmacokinetic perspective. *J Vasc Surg* 1989 Nov; 10(5): 501-10
47. Williams RD, Fisher FW. Aneurysm contents as source of graft infection. *Arch Surg* 1977 Apr; 112(4): 415-6
48. Malone JM, Lalka SG, McIntyre KE, Bernhard VM, Pabst TS. The necessity for long-term antibiotic therapy with positive arterial wall cultures. *J Vasc Surg* 1988 Sep; 8(3): 262-7
49. Perry MO. Infected aortic aneurysms. *J Vasc Surg* 1985 Jul; 2(4): 597-9
50. Shue WB, Worosilo SC, Trooskin SZ, Harvey RA, Donetz AP, Greco RS. Prevention of vascular prosthetic infection with an antibiotic bonded Dacron graft. *J Vasc Surg* 1988 Nov; 8(5): 600-5
51. Rubin JR, Malone JM, Goldstone J. The role of the lymphatic system in acute arterial prosthetic graft infections. *J Vasc Surg* 1985 Jan; 2(1): 92-8
52. Webb LX, Myers RT, Cordell AR, Hobgood CD, Costerton JW, Gristina AG. Inhibition of bacterial adhesion by antibacterial surface pretreatment of vascular prostheses. *J Vasc Surg* 1986 Jul; 4(1): 16-21