

6-1-2014

Ophthalmology Snapshot

Nalinee Tuntivanich

Follow this and additional works at: <https://digital.car.chula.ac.th/tjvm>



Part of the [Veterinary Medicine Commons](#)

Recommended Citation

Tuntivanich, Nalinee (2014) "Ophthalmology Snapshot," *The Thai Journal of Veterinary Medicine*: Vol. 44: Iss. 2, Article 15.

DOI: <https://doi.org/10.56808/2985-1130.2571>

Available at: <https://digital.car.chula.ac.th/tjvm/vol44/iss2/15>

This Other is brought to you for free and open access by the Chulalongkorn Journal Online (CUJO) at Chula Digital Collections. It has been accepted for inclusion in The Thai Journal of Veterinary Medicine by an authorized editor of Chula Digital Collections. For more information, please contact ChulaDC@car.chula.ac.th.

Ophthalmology Snapshot

Nalinee Tuntivanich

History

A 10 year-old male Fox Terrier was into a dog fight at home. He was presented to the Ophthalmology clinic, Animal Teaching Hospital, Faculty of Veterinary Science, Chulalongkorn University several days after traumatic injury, when the owner had realized a

swelling of the left lower eyelid and small open wound.

The dog was bilaterally visual. Ophthalmic examinations of the left eye revealed lachrymation but yet negative fluorescein staining test. Hyphema or globe rupture was not indicated. Two small wounds were observed at the temporal aspect of the swollen eyelid.

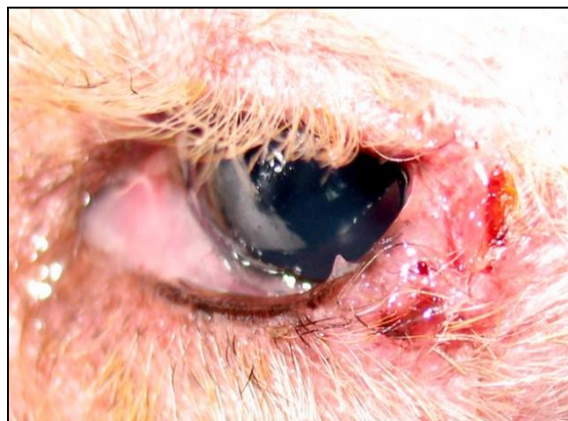

Figure 1 A photograph of the left eye of the Fox Terrier; illustrating open periorcular wounds. (For better quality of photographs, please visit the TJVM website)

Question

Give the appropriate treatment

Please turn to next page for the answer.

Answer

Skin suturing of eyelid laceration

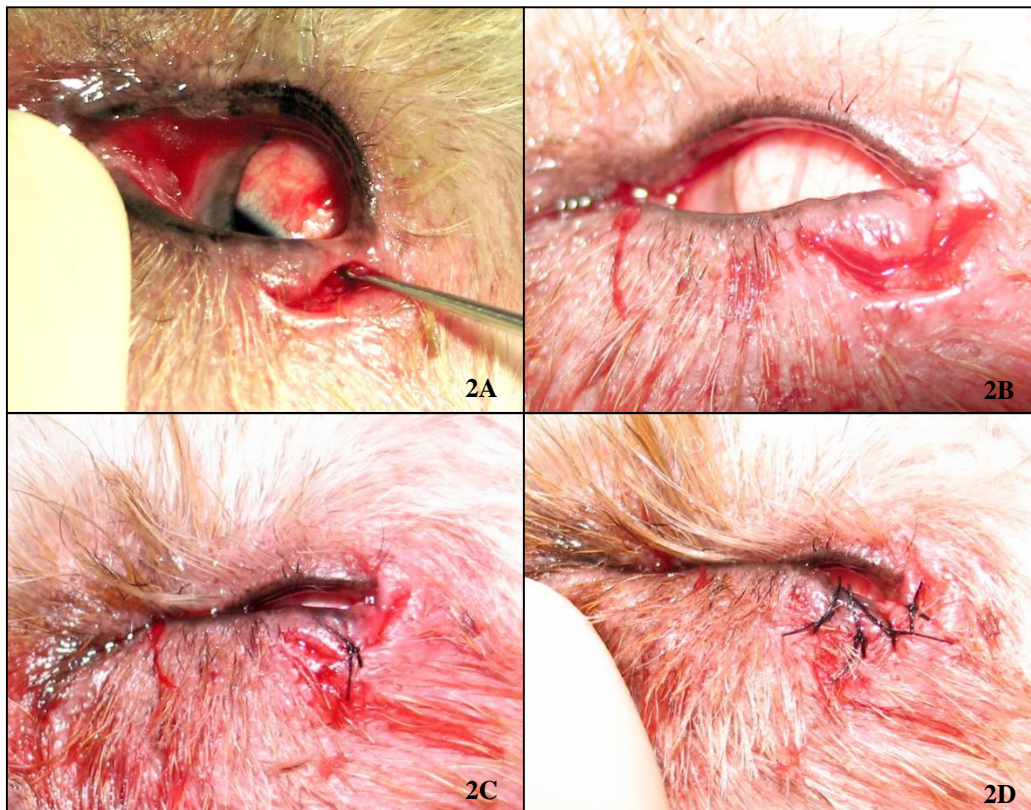


Figure 2 Photographs of the left eye with eyelid laceration; curettage of the two wounds connected to each other (2A), fresh wound with edge slightly trimmed (2B) and wound sutured (2C & 2D). (For better quality of photographs, please visit the TJVM website)

Comments

Eyelid trauma is common. It can occur in variety of manners. Before attempting to repair eyelid trauma, several evaluations should generally be considered; time and nature of injury, ocular conditions, lid function and medical history.

Since eyelid trauma may be associated with ocular problems, ophthalmic examinations should thoroughly be performed, including dilated fundus examination. Detailed history should be taken. If chemical is involved, irrigation is essential. Since this case was a dog bite; and yet we are in rabies-endemic country, history of previous vaccination should also be documented.

Eyelid injuries can generally be classified as blunt and penetrating. Because of tissue edema and ecchymosis in this case, it is considered a blunt wound. Penetrating wound appears as a direct slice through tissue structures. When skin is penetrated, any foreign bodies must be inspected. Evaluation of lid trauma should include function of muscles and nerves; both sensories and motors. If laceration involves lid margin, animals should receive special attention because

functional and cosmetic problems will possibly be involved.

A repair of lid laceration within 12-24 hours of the injury will reduce subsequent complications. Even though the wound of this Fox terrier was considered old (several days), techniques to avoid infection, inflammation and cicatrization of the eyelid were performed, so called wound debridement. The process should include copious irrigation with saline and removal of foreign particles. With dog bites injury, careful irrigation and cleaning combined with prophylactic antibiotics is required. Fibrin clot and old tissues were removed by curettage. Skin edge of the injured lid was trimmed to create fresh wound edge, promoting better healing. Apposition of the wound edge not only should be accurate but also appropriate to avoid lid misalignment. Suture materials should be removed after 10 days in periorbital skin injury.

Reference

Nelson CC 1999. Management of eyelid trauma. Australian and New Zealand Journal of Ophthalmology. 19(4): 357-363.