

3-1-2014

## What is Your Diagnosis?

Pranee Tuntivanich

Suwicha Chuthatep

Rampaipat Tungjitpeanpong

Follow this and additional works at: <https://digital.car.chula.ac.th/tjvm>



Part of the [Veterinary Medicine Commons](#)

---

### Recommended Citation

Tuntivanich, Pranee; Chuthatep, Suwicha; and Tungjitpeanpong, Rampaipat (2014) "What is Your Diagnosis?," *The Thai Journal of Veterinary Medicine*: Vol. 44: Iss. 1, Article 13.

Available at: <https://digital.car.chula.ac.th/tjvm/vol44/iss1/13>

This Other is brought to you for free and open access by the Chulalongkorn Journal Online (CUJO) at Chula Digital Collections. It has been accepted for inclusion in The Thai Journal of Veterinary Medicine by an authorized editor of Chula Digital Collections. For more information, please contact [ChulaDC@car.chula.ac.th](mailto:ChulaDC@car.chula.ac.th).

## What is Your Diagnosis?

Pranee Tuntivanich Suwicha Chuthatep Rampaipat Tungjitpeanpong

### *Signalment*

A 15-year-old female Lhasa Apso

### *History*

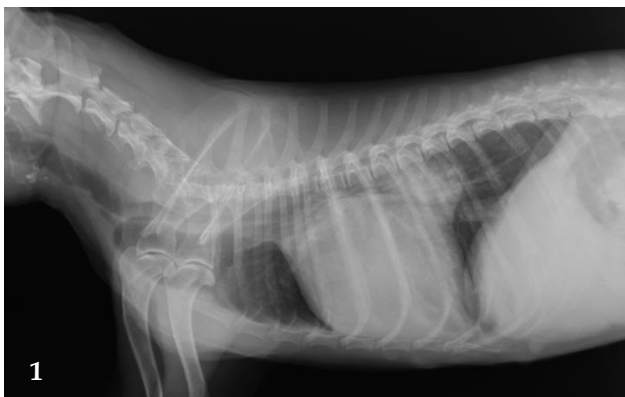The dog was diagnosed with chronic bronchitis and concurrent left-sided heart problem that had been treated for a year. The dog had chronic cough that was treated periodically with corticosteroids and bronchodilators during the last 2 months. A week prior to presentation, the owner noticed an intermittent swelling of the ventral aspect of the neck during coughing and expiration period.

### *Clinical Examination*

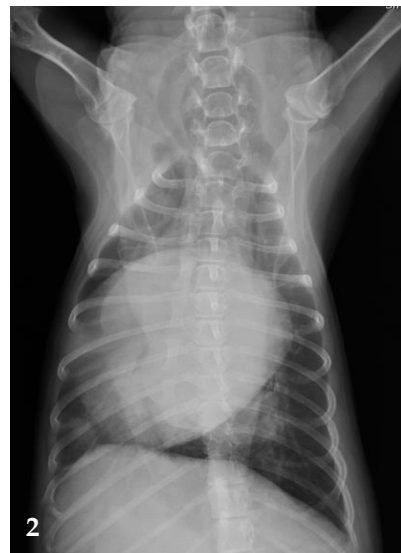The cough was easily induced by palpation of the trachea. An intermittent, painless, swelling soft tissue was palpable in the ventral area of the thoracic inlet. Blood biochemical tests showed a slight increase in liver enzyme activities.

### *Radiographic Examination*

Plain right lateral and ventrodorsal cervico-thoracic radiographs were taken to evaluate cardiorespiratory abnormalities and the soft tissue swelling.

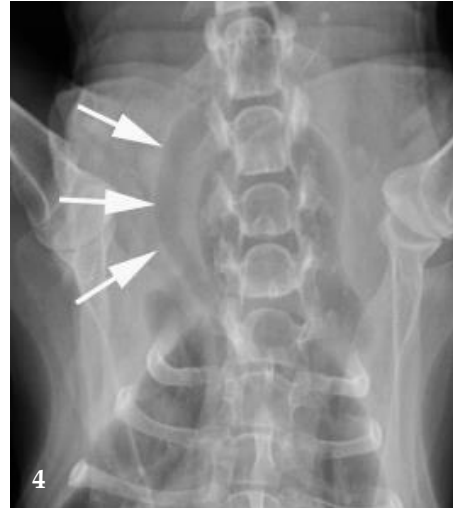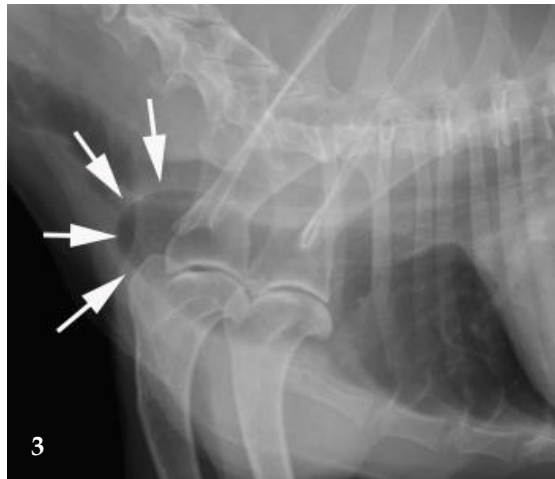


**Figure 1** Right lateral view of the cervico-thoracic radiograph



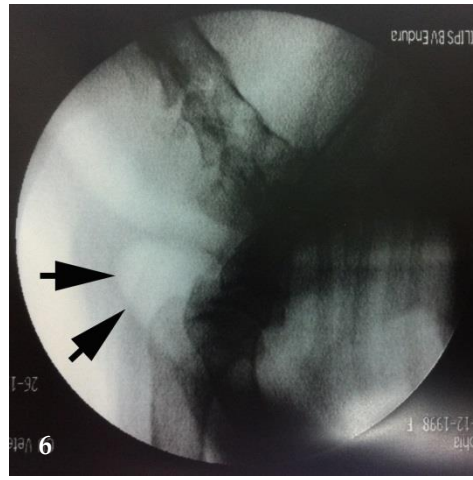
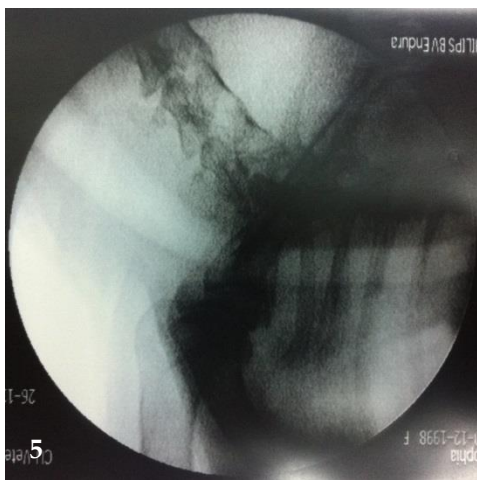
**Figure 2** Ventrrodorsal view of the cervico-thoracic radiograph

Give your diagnosis and turn to the next page.



**Figure 3** The radiolucent pocket in the ventral cervical region presents cranial lung herniation (white arrows).

**Figure 4** Right lateral displacement of the trachea (white arrows) due to the left cranial lung lobe herniation.



**Figure 5** Inspiratory fluorogram

**Figure 6** Protusion of a cranial lung lobe (black arrows) during expiratory fluorogram

### **Radiographic findings**

The right lateral view (Fig 1) showed a well-defined oval-shaped radiolucency area in the ventral aspect of the cervical portion of the thoracic inlet was seen. This lesion induces a mild dorsal elevation of the cranial portion of the thoracic trachea. Bulging of the caudo-dorsal border of the cardiac silhouette and generalized interstitial infiltration of the lung were also presented on this view. The ventrodorsal view (Fig 2) revealed a right lateral deviation of the trachea at the level of caudal cervical region due to left cranial lung lobe protrusion. The tracheal bifurcation was diverged due to left atrial enlargement, and interstitial infiltration was obviously noticed at the perihilar area. For further information, dynamic fluoroscopy was performed to evaluate abnormalities of the trachea and movement of the herniated lung lobe during different phases of the respiratory cycle. A protrusion of the cranial lung lobe with narrowing diameter of the intra-thoracic trachea was seen on the peak expiratory fluorogram, but not on the inspiratory fluorogram (Figs 5-6).

### **Radiographic diagnosis**

Cranial lung herniation and left-sided heart disease

### **Discussion**

Cranial lung herniation is described as a protrusion of the lung tissue beyond the normal border of the thoracic cavity. The hernia may be congenital, which is found in young dog (Chang et al., 2010) or acquired, often developed in aging dog older than 13 years (Guglielmini et al., 2007). The acquired form is associated with an increase in expiratory effort and chronic cough secondary to chronic obstructive airway disorder. In addition, muscle weakness of the thoracic inlet and the stretch of parietal pleura may be caused by long-term use of steroids. Lung herniation is usually diagnosed by radiography, computed tomograph (CT), and fluoroscopy. Although CT can detect the location of the thoracic wall defect, false-negative result may occur. Fluoroscopy may be a proper tool for evaluating the lung movement during respiration cycle. An esophageal diverticulum should be an important differential diagnosis, which can be ruled out using contrast esophagram.

### **References**

- Chang JL, Maritato K and Ryan KA 2010. What is your diagnosis? J Am Vet Med Assoc. 236 (6): 627- 628.  
Guglielmini C, De Simone A, Valbonetti L and Diana A 2007. Intermittent cranial lung herniation in two dogs. Vet Radiol Ultrasoun. 48 (3): 227-229.

