

3-1-2014

Ultrasound Diagnosis

Phiwipha Kamonrat

Follow this and additional works at: <https://digital.car.chula.ac.th/tjvm>



Part of the [Veterinary Medicine Commons](#)

Recommended Citation

Kamonrat, Phiwipha (2014) "Ultrasound Diagnosis," *The Thai Journal of Veterinary Medicine*: Vol. 44: Iss. 1, Article 12.

Available at: <https://digital.car.chula.ac.th/tjvm/vol44/iss1/12>

This Other is brought to you for free and open access by the Chulalongkorn Journal Online (CUJO) at Chula Digital Collections. It has been accepted for inclusion in The Thai Journal of Veterinary Medicine by an authorized editor of Chula Digital Collections. For more information, please contact ChulaDC@car.chula.ac.th.

Ultrasound Diagnosis

Phiwipha Kamonrat

History

A three-year-old, spayed female, Shihtzu dog was referred to the Chulalongkorn University, Small Animal, Veterinary Teaching Hospital for a sudden onset of depression, vomiting and bloody diarrhoea. The dog had undergone an ovariohysterectomy ten months earlier at a veterinary clinic and had diarrhea for a few times during the last five months. Physical examination findings showed pink mucous membranes, normal heart and lung sound, and a mild abdominal cramp on palpation of the mid abdomen. The results of a complete blood count and a serum biochemistry profile were unremarkable. Blood parasites were not found. Survey abdominal radiographs were within normal limits with no evidence of gastrointestinal foreign bodies or obstruction. An abdominal ultrasonography was performed to obtain more specific information.

Ultrasonographic Findings

A real-time, ultrasonographic examination of an entire abdomen was performed using an 11 MHz linear transducer with the dog in dorsal recumbency. The echogenicity relationship of liver, spleen and kidneys were within normal limits. With sagittal (Figure 1A and 2A) and transverse (Figure 1B and 2B) scans, a localized structure was found in the right mid abdominal cavity, just caudal to the right kidney. This lesion was approximately 1.6 by 2.3 cm in diameter and oval in shape with a smooth surface. It appeared as a heterogeneously hypoechoic structure with diffuse areas of hyperechogenicity. At the center of the lesion, there was a hyperechoic focus associated with distal acoustic shadowing, consistent with a mineralization. The tissue surrounding this lesion was relatively hyperechoic, which was highly suggestive of a localized inflammatory reaction, adhesion and / or scar tissue. Ultrasonography of other abdominal organs including the gastrointestinal tract appeared normal in echotexture. An ultrasound-guided fine needle aspiration of this lesion was performed and diagnosed as a septic lesion.

Ultrasonographic Diagnosis

An infected ovarian stump.

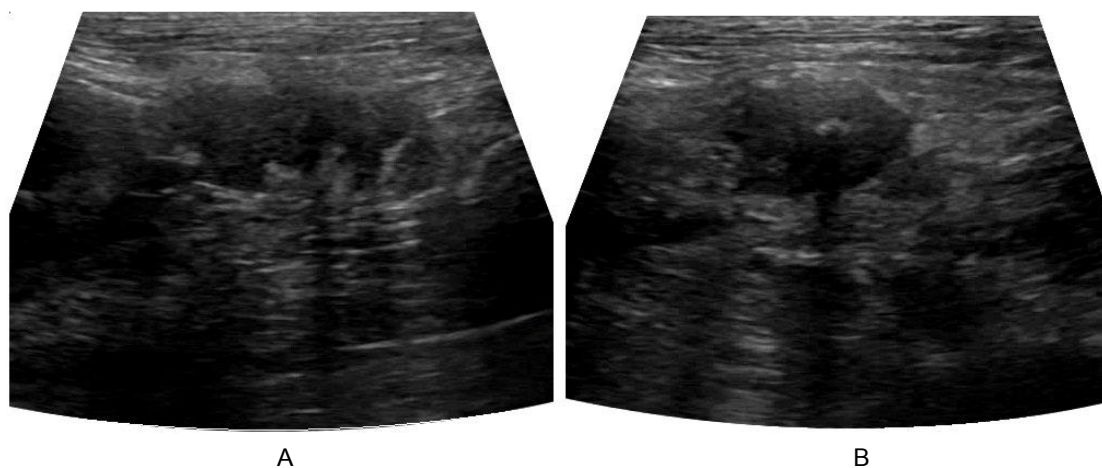


Figure 1 Transabdominal sagittal (A) and transverse (B) ultrasonograms of the three-year-old, spayed female, Shihtzu dog that previously had an ovariectomy, in dorsal recumbency. A localized mass caudal to the right kidney was an infected ovarian stump, which appeared as a heterogeneously hypoechoic structure with diffuse areas of hyperechogenicity and a central focus of mineralization. The hyperechoic surrounding tissue was consistent with the localized inflammatory reaction and adhesion.

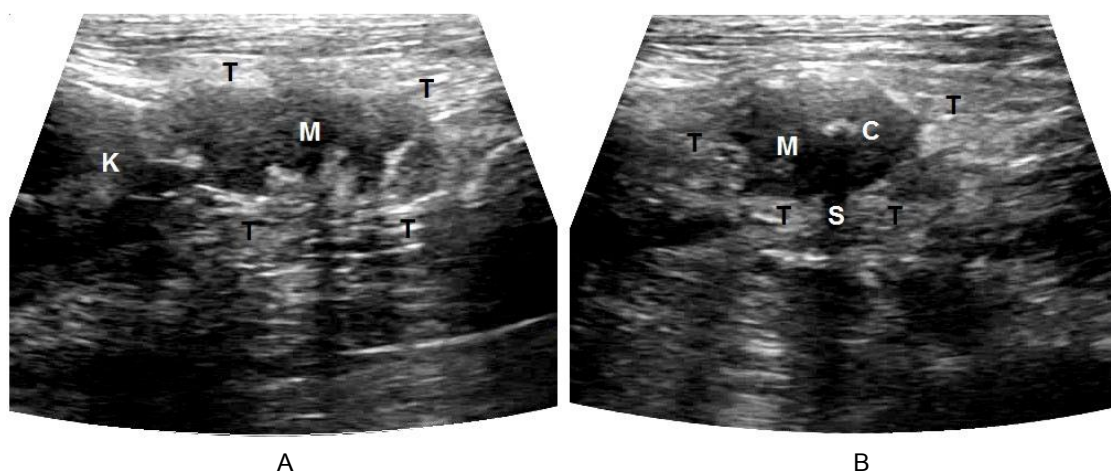


Figure 2 Schematics of the relative positions of the structures scanned in figure 1. K -right kidney; M -mass (infected ovarian stump); C -hyperechoic mineralized focus; S -distal acoustic shadow; T -hyperechoic surrounding tissues.

Comments

In the dog of this report, the ultrasonographic finding of the mass location combined with the cytology result pointed to a diagnosis of an infected ovarian stump. Exploratory laparotomy confirmed the ultrasonographic diagnosis. This mass was firm in consistency and adhered to the surrounding tissues, including the caudal portion of the right kidney, omentum and peritoneum. Subsequent histopathological examination indicated that this infected mass was arising from the residual ovarian tissue.

Canine ovaries are located caudally, caudolaterally, caudomedially or ventrally to the caudal poles of the kidneys. The recognition of anatomical landmarks is important for identifying and examining this organ. In normal dogs, ovaries are oval to round structures and measure approximately 2 cm long. The ultrasonographic appearance of the canine ovaries varies during the estrus cycle (Wallace et al., 1992). During anestrus, they have homogeneous echogenicity similar to that

of the adjacent renal cortex, with smooth, well-delineated margins, without evidence of follicles or corpora lutea. The cortex is not usually differentiated from the medulla.

One of the complications following ovariectomy is the presence of residual ovarian tissues which may develop other abnormalities, including ovarian remnant syndrome, ovarian stump granuloma, tumor or infection. In dogs, the residual tissue of the right ovary was found more often than that of the left one (Ball et al., 2010), as presented in this dog. The sonographic changes associated with intra-abdominal abscesses are typically thick and irregularly walled with hyperechoic debris or gas within the hypoechoic purulent exudate. Distal acoustic enhancement may be either present or absent varying with the viscosity of the exudate and amount of cellular elements (Konde et al., 1986). Ultrasonography is the diagnostic of choice; however, conclusive evidence of infection may require exploratory laparotomy and histological confirmation of the presence of ovarian structures.

References

- Ball RL, Birchard SJ, May LR, Threlfall WR and Young GS 2010. Ovarian remnant syndrome in dogs and cats: 21 cases (2000-2007). *J Am Vet Med Assoc.* 236(5): 548-553.
- Konde LJ, Lebel JL, Park RD and Wrigley RH 1986. Sonographic application in the diagnosis of intraabdominal abscess in the dog. *Vet Radiol.* 27(5): 151-154.
- Wallace SS, Mahaffey MB, Miller DM, Thompson FN and Chakraborty PK 1992. Ultrasonographic appearance of the ovaries of dogs during the follicular and luteal phases of the estrous cycle. *Am J Vet Res.* 53(2): 209-215.

