

4-1-1985

Co-Trimoxazole in the treatment of chancroid

Phairaj Desudchit

Follow this and additional works at: <https://digital.car.chula.ac.th/clmjjournal>



Part of the [Medicine and Health Sciences Commons](#)

Recommended Citation

Desudchit, Phairaj (1985) "Co-Trimoxazole in the treatment of chancroid," *Chulalongkorn Medical Journal*: Vol. 29: Iss. 4, Article 4.

Available at: <https://digital.car.chula.ac.th/clmjjournal/vol29/iss4/4>

This Article is brought to you for free and open access by the Chulalongkorn Journal Online (CUJO) at Chula Digital Collections. It has been accepted for inclusion in Chulalongkorn Medical Journal by an authorized editor of Chula Digital Collections. For more information, please contact ChulaDC@car.chula.ac.th.

Co-Trimoxazole in the treatment of chancroid

Phairaj Desudchit*

Desudchit P. Co-Trimoxazole in the treatment of chancroid. Chula Med J 1985 Apr; 29 (4) : 455-461

*Fifty six men with positive smears for chancroid were treated with sulfamethoxazole-trimethoprim. Of the 52 patients who remained for evaluation, forty seven (90.38%) were reported cured within two weeks, while five (9.62%) needed additional erythromycin two more weeks. This investigation concluded that the sulfamethoxazole-trimethoprim combination had promising efficacy in the treatment of chancroid and that Unna Pappenheim's stain showed *H. ducreyi*-like organism in 56 (42.11%) out of the 133 clinically diagnosed cases of chancroid. This smear method of diagnosis is useful in area with limited facilities.*

ไพรัช ตีสุดจิต. การใช้ co-trimoxazole รักษาโรคแผลริมอ่อน. จุฬาลงกรณ์เวชสาร 2528 เมษายน; 29 (4) : 455-461

ผู้ป่วยชาย 52 คน เป็นแผลริมอ่อนชนิด smear positive ได้รับการรักษาด้วย co-trimoxazole ผู้ป่วย 52 รายกลับมาให้ประเมินผล 47 ราย (90.38%) รักษาหายภายใน 2 อาทิตย์ ที่เหลือ 5 ราย (9.62%) ต้องเปลี่ยนเป็น erythromycin อีก 1-2 อาทิตย์ ผลการวิจัยนี้แสดงว่า co-trimoxazole มีประสิทธิภาพดี

*การใช้สี Unna Pappenheim พบเชื้อเหมือน *H. ducreyi* 56 ราย (42.11%) จากผู้ป่วยที่วินิจฉัยทางคลินิกเป็นแผลริมอ่อน 133 ราย การวินิจฉัยด้วยวิธีนี้นับว่ามีประโยชน์ในที่ไม่มีเครื่องมือเพาะเชื้อ*

* Department of Preventive and Social Medicine, Faculty of Medicine, Chulalongkorn University.

Introduction

Chancroid is a sexually transmitted disease caused by *Haemophilus ducreyi* and thought to be infrequent in the west but common in the tropical and subtropical countries. In Thailand there was a rapid increase in the incidence of sexually transmitted diseases in the past decade. During the years 1977-1979 there were 52517, 56319 and 57822 cases of chancroid diagnosed clinically in Thailand, whereas in Britain there were 49, 57 and 49 respectively (Table 1).

Co-trimoxazole, a combination of sulphamethoxazole 400 mg. with trimethoprim 80 mg. has no effect on *treponema pallidum* and dose not alter the course of incubating or active syphilis. K.C. Nayyar et als., has reported the clinical effectiveness of Co-trimoxazole in the treatment of chancroid, confirmed by in-vitro sensitivity studies. ⁽¹⁾ Previously, oral sulfonamides or tetracyclines were the treatments of choice. Because of the increasing numbers of treatment failure with standard therapy,

we decided to use Co-trimoxazole in the treatment of smear-positive chancroid in this study.

Materials and methods

The male patients involved in this investigation attended the sexually transmitted diseases clinic at Chulalongkorn Hospital between January 1982 and December 1983. There were 133 presumptive clinical diagnoses of chancroid (figure 1). All patients were interviewed concerning their exposure to STD., the incubation period, demographic data, were routinely subjected to VDRL screening and in positive cases, to FTA-ABs or TPHA to exclude syphilis.

The lesion was thoroughly washed with saline and serous exudate was collected for dark ground microscopy. Serous exudate from the undermined border of the ulcers were examined for *H. ducreyi* after staining with Unna Pappenheim's stain, pus cells staining bluish green and coccoid-bacillary rods, a brilliant red, in short chains or small clusters along strands of mucous (Figure 2). The lesions and

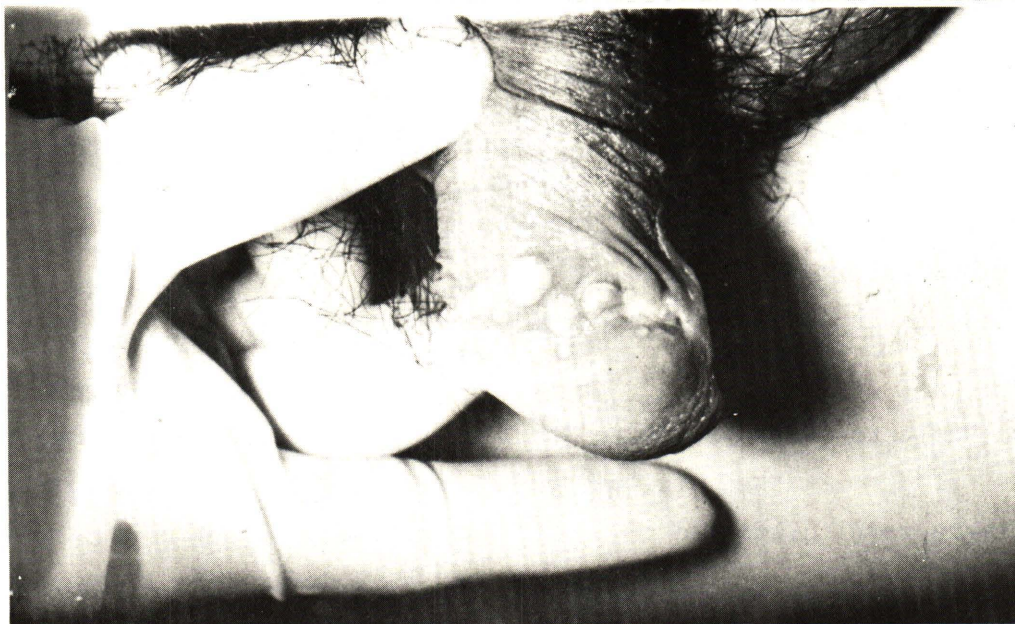

Figure 1 Multiple ulcers in chancroid.

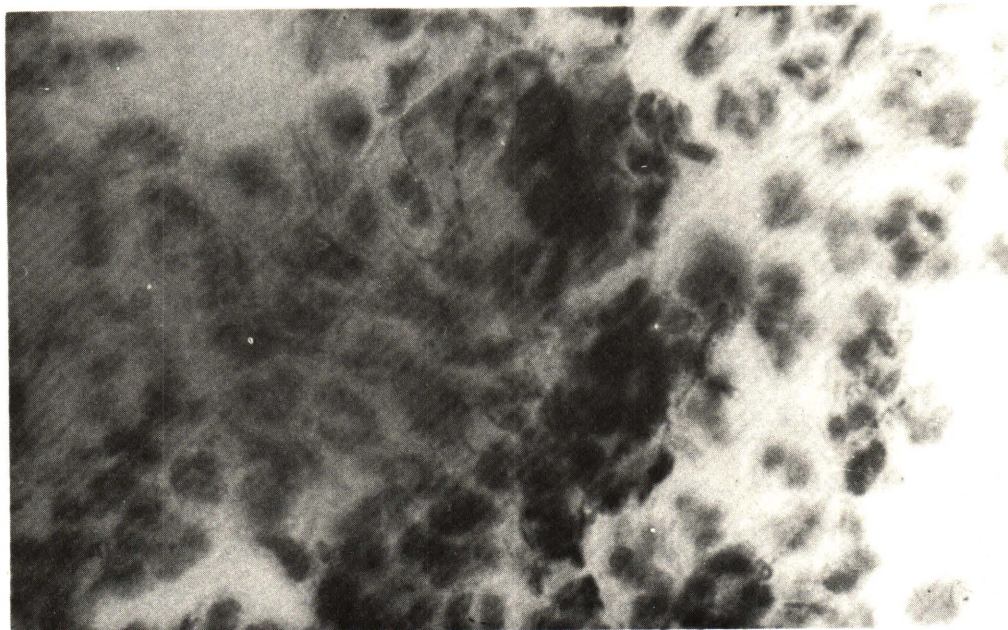


Figure 2 *Haemophilus ducreyi* smeared from chancroid. (Unna Pappenheim's stain x 1.000)

inguinal lymph nodes were carefully examined and their location and numbers were recorded. Culture for *H. ducreyi* were not performed because of our poor previous experience in the successful isolation and our limited facility.

Patients were included in this study if the following criteria were fulfilled :

1. The patient was willing and able to participate in this study, lasting three weeks.
2. Smear was positive for *H. ducreyi* - like organism
3. Darkfield microscopy and VDRL were negative.

Treatment :

Patients were treated with co-trimoxazole 2 tablets twice daily for 1-2 weeks and returned for follow up examination on the 7th and 14th days.

Indication for cure :

1. Smear was negative for *H. ducreyi* - like organism
2. The lesions and inguinal adenitis were healed and the numbers did not increase.

Results

Of all the 133 presumptive clinical diagnoses of chancroid, 56 cases (42 %) had positive smears for *H. ducreyi* - like organism. The mean incubation period was 5.79 days (range 2-15, n = 56, table 2). Patients with multiple lesion were common. There were 10 cases with inguinal adenitis. Of the 56 treated cases, 3 defaulted, 1 was complicated by a drug rash and 52 remained for study. Thirty six patients (69.23 %) were reported cured in the 1st week, 11 (21.15%) on the 2nd week and 5 (9.62) needed additional erythromycin treatment. (Table 3).

Discussion

The diagnosis of chancroid can be difficult and in endemic areas relies on case history and the rather characteristic clinical appearance. In an area where laboratory facility is limited, direct smear may be useful. In this study, the information obtained from the smear was 42% positive for *H. ducreyi*-like organism compared to the 56% posi-

tive for both microscopy and culture.⁽²⁾ In an earlier report, Reymen also found that smears gave a positive result in 50-83% of cases,⁽³⁾ while Nayyar et al gave a positive result of 82%.

The incubation period was difficult to assess exactly because information about the time of exposure and the early lesion was imprecise. The mean incubation period was 5.79 days. (range 2-15 days, n = 56, table 2)

Rajan and Pang have recently reported a prospective study from the Republic of Singapore in which a 95% cure rate was achieved in 56 patients with either oral or IM co-trimoxazole for seven to

fourteen days.⁽⁴⁾ Nayyar et al. have recently reported a retrospective study in Holland with 100% cure rate in 26 patients on oral co-trimoxazole for ten to fourteen days⁽¹⁾.

In this study 47 cases(90.38) were cured with oral co-trimoxazole within two weeks, only 5 (9.62%) failed and were treated successfully with 2 gm. Erythromycin per day for 7 days in 3 cases and 14 days in 2 cases (table 3).

It was concluded that co-trimoxazole was quite promising in the treatment of smear-positive chancroid.

Table 1 Compare the incidence of chancroid in Thailand and Britain during 1977 - 1979.

	1977	1978	1979
Thailand	52,517	56,139	57,822
Britain	49	57	49

Table 2 Range of incubation period

Day	2	3	4	5	6	7	8	9	10	11 - 15
Case	6	11	4	9	3	11	2	1	1	8

Range = 2 - 15, N = 56, Mean = 5.79 days

Table 3 Result of treatment 1st, 2nd week with co-trimoxazole and 3rd, 4th week with erythromycin

Time / week	Cases	%
1 st	36	69.23
2 nd	11	21.15
3 rd and 4 th	5	9.62
Total	52	100

References

1. Nayyar KC, Stolz E, Michel MF. Rising incidence of chancroid in Rotterdam : epidemiological, clinical, diagnostic, and therapeutic aspects. Br J Vener Dis 1979 Dec ; 55(6) : 439-441
2. Tan T, Rajan VS, Koe SL, Tan NJ, Tan BH, Goh AL. Chancroid : a study of 500 cases. Asian J Infect Dis 1977 Jan ; 1(1) : 27-28
3. Reymen F. Studies on the Bacteriology of Haemophilus Ducreyi with Special Reference to the Diagnosis of Chancroid. Copenhagen: Danish Science Press, 1951
4. Rajan VS, Pang R. Treatment of chancroid with bactrim. Ann Acad Med Singapore 1979 Jan ; 8(1) : 63-66

จุฬาลงกรณ์เวชสารได้รับต้นฉบับเมื่อวันที่ 30 เดือนพฤศจิกายน พ.ศ. 2527