

9-1-2013

ULTRASOUND DIAGNOSIS

Phiwipha Kamonrat

Follow this and additional works at: <https://digital.car.chula.ac.th/tjvm>



Part of the [Veterinary Medicine Commons](#)

Recommended Citation

Kamonrat, Phiwipha (2013) "ULTRASOUND DIAGNOSIS," *The Thai Journal of Veterinary Medicine*: Vol. 43: Iss. 3, Article 22.

Available at: <https://digital.car.chula.ac.th/tjvm/vol43/iss3/22>

This Other is brought to you for free and open access by the Chulalongkorn Journal Online (CUJO) at Chula Digital Collections. It has been accepted for inclusion in The Thai Journal of Veterinary Medicine by an authorized editor of Chula Digital Collections. For more information, please contact ChulaDC@car.chula.ac.th.

ULTRASOUND DIAGNOSIS

Phiwipha Kamonrat

History

A seven-month-old, male, Shih Tzu dog was referred to the Chulalongkorn University, Small Animal, Veterinary Teaching Hospital for solving a chronic problem of demodex infestation. The dog was alert, had a normal appetite and showed no other clinical signs. Water intake and urination were normal. Physical examination revealed pink mucous membranes and a slightly tense abdomen on palpation. The result of a complete blood count was within a normal range and a blood parasite was not found. The serum biochemical analyses indicated a mild increase in alkaline phosphatase (ALP) (113 IU) and markedly elevated blood urea nitrogen (104.8 mg%) and creatinine (2.8 mg%) concentrations. Urinalysis was unremarkable. Survey radiography of thorax and abdomen were within normal limits. An abdominal ultrasonography was performed to obtain more specific information of the urinary tract.

Ultrasonographic Findings

Real-time, ultrasonographic images were obtained using an 8 MHz microconvex, phased array transducer with the dog in dorsal recumbency. The overall renal tissue appeared hyperechoic, relative to hepatic and splenic parenchyma, compared at approximately the same depth. Both kidneys had significantly poor corticomedullary distinction and uneven cortical contour, especially the left one (Figure 1 and 2). Linear measurements of right and left kidneys were 2.9x4.3 and 2.5x4.1 cm, respectively. Each kidney contained multifocal, more than 5 cystic lesions throughout the renal parenchyma, mostly in the cortex. These renal cysts appeared as well-defined, 3-15 mm-sized, round- to oval-shaped, anechoic structures, with distal acoustic enhancement. There was a renal pelvic dilation, characterized as an anechoic space around the renal crest, measuring 4.5 and 3.5 mm of the right and left kidneys, respectively. A ureteral dilation was not evident. A thin layer of anechoic fluid was present at the periphery of the cortex of each kidney, indicative of a subcapsular perirenal fluid. The urinary bladder was seen markedly distended with anechoic urine. The urinary bladder wall was smooth, echoic, and 1 mm thick. Liver and spleen were normal in echotexture.

Ultrasonographic Diagnosis

Bilateral polycystic renal disease

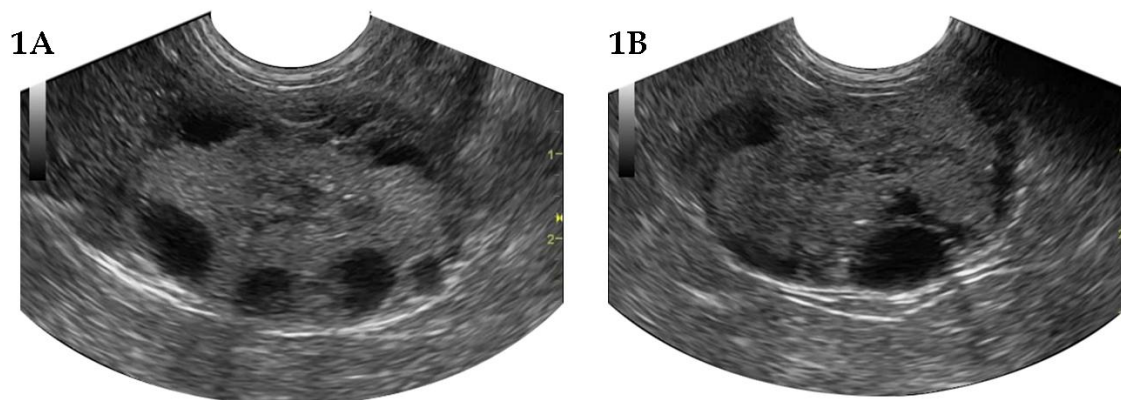


Figure 1 Sagittal and transverse ultrasonographic images of the right (A) and left (B) kidneys of a seven-month-old, male, Shih Tzu dog in dorsal recumbency. Both kidneys had significantly poor corticomedullary distinction and contained multifocal, small, anechoic cysts throughout the renal cortices. Renal pelvic dilation and subcapsular perirenal fluid were also found.

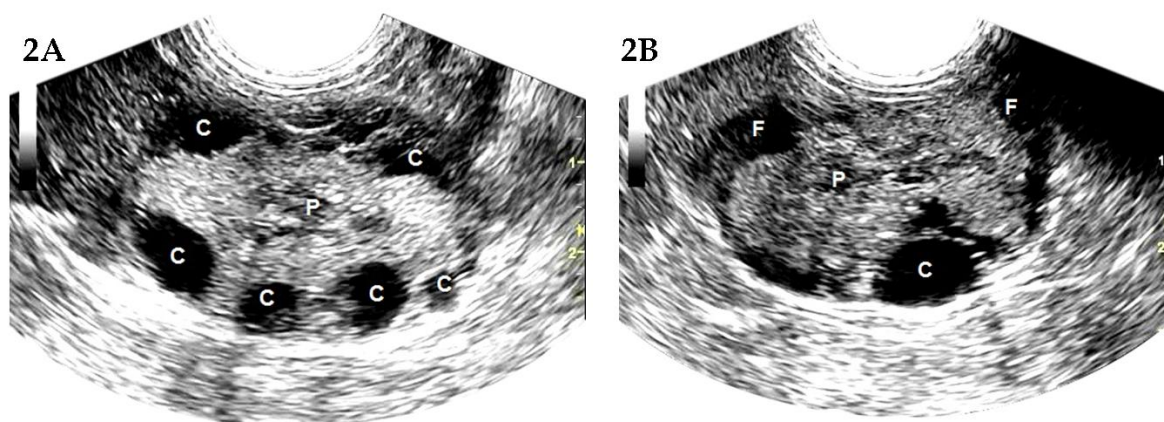


Figure 2 Schematics of the relative positions of the structures scanned in figure 1. C -anechoic cyst; P -anechoic renal pelvis; F - subcapsular perirenal fluid.

Comments

The cause of polycystic renal disease in dogs and cats may be congenital or acquired. Inherited polycystic kidney disease has been reported in Bull Terrier dogs (O'Leary et al., 1999) and Persian cats (Reichle et al., 2002). Acquired cysts are associated with various types of nephropathies. Not all animals with polycystic kidney disease develop clinical signs. Ultrasonography is a noninvasive, sensitive and specific technique for diagnosing a polycystic kidney disease. Ultrasonographic findings that are consistent in appearance with polycystic kidney lesions include multifocal, spherical to ovoid, anechoic structures that are delineated by smooth, thin, echogenic wall, with distinct far-wall border. These cysts are usually bilateral, vary in size and occur throughout the renal cortex and medulla. If they lie near the periphery of the cortex, they can distort the renal outline. Ultrasound artifacts that are helpful in differentiating cystic from solid structures include a strong acoustic enhancement distal to the anechoic cyst and an edge shadowing distal to the lateral margins of the cyst (Penninck, 2002).

In this dog, there had been no clinical signs of renal failure present. However, additional ultrasonographic findings, included a diffuse increase

in renal echogenicity, poor corticomedullary differentiation, renal pelvic dilation and subcapsular perirenal fluid, concurrent with marked elevation of BUN and creatinine concentrations were supportive of nephropathy.

References

- O'Leary CA, Mackay BM, Malik R, Edmondston JE, Robinson WF, Huxtable CR. 1999. Polycystic kidney disease in Bull Terriers: an autosomal dominant inherited disorder. *Aus Vet J* 77:361-366.
- Reichle JK, DiBartola SP, Leveille R. 2002. Renal ultrasonographic and computed tomographic appearance, volume, and function of cats with autosomal dominant polycystic kidney disease. *Vet Radiol Ultrasound* 43:368-373.
- Penninck DG. 2002. Artifacts. In: *Small Animal Diagnostic Ultrasound*. 2nd ed. T.G. Nyland and J.S. Mattoon (eds.) Philadelphia: W.B. Saunders Company. 19-29.