

6-1-2013

## Coccidiosis in a Greater Slow loris (*Nycticebus coucang*)

Wijit Banlunara

Sawang Kedsangsakonwut

Piyaporn Kongmekee

Angkana Sommanustweechai

Follow this and additional works at: <https://digital.car.chula.ac.th/tjvm>



Part of the [Veterinary Medicine Commons](#)

---

### Recommended Citation

Banlunara, Wijit; Kedsangsakonwut, Sawang; Kongmekee, Piyaporn; and Sommanustweechai, Angkana (2013) "Coccidiosis in a Greater Slow loris (*Nycticebus coucang*)," *The Thai Journal of Veterinary Medicine*: Vol. 43: Iss. 2, Article 14.

Available at: <https://digital.car.chula.ac.th/tjvm/vol43/iss2/14>

This Short Communication is brought to you for free and open access by the Chulalongkorn Journal Online (CUJO) at Chula Digital Collections. It has been accepted for inclusion in The Thai Journal of Veterinary Medicine by an authorized editor of Chula Digital Collections. For more information, please contact [ChulaDC@car.chula.ac.th](mailto:ChulaDC@car.chula.ac.th).

## Coccidiosis in a Greater Slow loris (*Nycticebus coucang*)

Wijit Banlunara <sup>1\*</sup> Sawang Kedsangsakonwut <sup>1</sup> Piyaporn Kongmekee <sup>2</sup>  
Angkana Sommanustweechai <sup>2</sup>

### *Abstract*

Since *Eimeria pachylepyron* was firstly described in slow loris (*Nycticebus coucang*) in 1972, there has not been any reports of the disease throughout the world. An adult male 0.8 kg bw greater slow loris (*Nycticebus coucang*) had diarrhea, emaciation and dead. Severe necro-hemorrhagic jejunitis with the presence of coccidian protozoa and secondary bacterial septicemia were the causes of death. Endogenous stages of *E. pachylepyron* were detected exclusively in the jejunal enterocytes especially in the crypt of Lieberkühn. The typical round unsporulated oocysts with homogeneous eosinophilic thick wall were closely related to *E. pachylepyron*. This is the first report to confirm the existence of the protozoan as the pathologic disease in the slow loris.

---

**Keywords:** *Eimeria pachylepyron*, non-human primate, pathology, oocyst, Thailand

<sup>1</sup> Department of Pathology, Faculty of Veterinary Science, Chulalongkorn University, Pathumwan, Bangkok 10330 Thailand

<sup>2</sup> Conservation Research and Education Division, Zoological Park Organization of Thailand, Dusit, Bangkok 10300 Thailand

\*Correspondence author E-mail: [wijit.k@chula.ac.th](mailto:wijit.k@chula.ac.th)

## บทคัดย่อ

### โรคบิดในลิงลม

วิจิตร บรรลุณารา<sup>1\*</sup> สว่าง เกษแดงสกุลวุฒิ<sup>1</sup> ปิยะพร คงเมคี<sup>2</sup> อังคณา สมน์สทวิชัย<sup>2</sup>

ตั้งแต่มีการค้นพบเชื้อบิดชนิด *อัยเมอเรีย พาคีเลไพรอน* ในนางอาย เมื่อปี พ.ศ. 2515 ไม่มีรายงานการเกิดโรคนี้ในโลกอีก ลิงลมโตเต็มวัย เพศผู้ น้ำหนัก 0.8 กก. แสดงอาการทางคลินิก ท้องเสีย ผอมแห้ง และเสียชีวิต สาเหตุของการเสียชีวิตของนางอายเกิดจากลำไส้เล็กอักเสบแบบเนื้อตายปนเลือดร่วมกับบิดและติดเชื้อแบคทีเรียแทรกซ้อนเข้ากระแสเลือด ระยะต่างๆของเชื้อบิด พบในเซลล์เยื่อบุของลำไส้เล็กส่วนกลางโดยเฉพาะส่วนเซลล์อ่อนที่ฐาน โอลิโกซิสต์ที่ยังไม่สมบูรณ์มีลักษณะเฉพาะตัวที่มีเปลือกหนาเหมือนกับเชื้อบิดชนิด *อัยเมอเรีย พาคีเลไพรอน* ผลการศึกษานี้เป็นรายงานครั้งแรกที่ยืนยันการมีอยู่จริงของโรคบิดชนิดนี้ และก่อรอยโรคทางพยาธิวิทยาในลิงลม

คำสำคัญ: *อัยเมอเรีย พาคีเลไพรอน* สัตว์ตระกูลลิง โอลิโกซิสต์ ประเทศไทย

<sup>1</sup> ภาควิชาพยาธิวิทยา คณะสัตวแพทยศาสตร์ จุฬาลงกรณ์มหาวิทยาลัย ปทุมวัน กรุงเทพฯ 10330

<sup>2</sup> สำนักอนุรักษ์ วิจัยและศึกษา องค์การสวนสัตว์ในพระบรมราชูปถัมภ์ ดุสิต กรุงเทพฯ 10300

\*ผู้รับผิดชอบบทความ E-mail: wijit.k@chula.ac.th

### Introduction

Few coccidian species are identified from the family Loridae (loris) of non-human primates. There are only three species; *Eimeria coucangi*, *E. nycticebi* and *E. pachylepyron*, which were found in slow lorises' (*Nycticebus coucang*) feces (Patnaik and Acharjyo, 1970; Colley and Mullin, 1972; Duszynski et al., 1999). The morphology of sporulated *E. pachylepyron* oocyst has a typically rough, irregular striated outer thick wall. However, *E. lemuris* oocysts that were detected from feces of Senegal babybush (*Galago senegalensis*) also have thick wall (Poelma, 1966). Until now, there has not been any report of coccidiosis that was caused by these coccidian protozoa in the slow loris worldwide.

This study is the first report of pathology of the *E. pachylepyron* infection in a greater slow loris (*Nycticebus coucang*).

### Materials and Methods

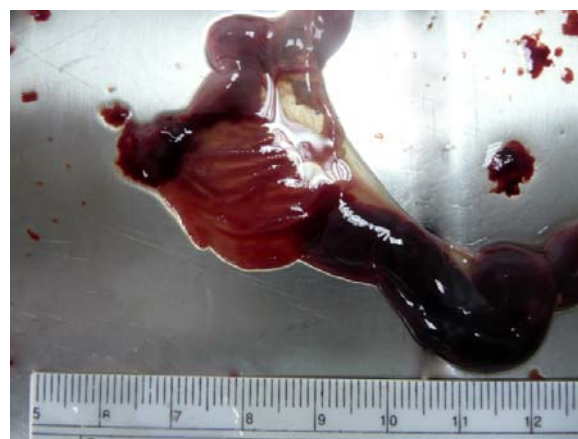An adult male greater slow loris (*Nycticebus coucang*) was given by people who reared it as pet to the opened Khao Keaw Zoo, Chon buri province, Thailand. The animal was clinically emaciated with diarrhea and severe dehydration. The body weight was 0.8 kg. It died in the quarantine area in May 2009. Routine necropsy was performed. The organs were fixed in 10% buffered formalin solution and were allowed to fix for 24 hours. Fixed tissues were routinely processed for histology in paraffin embedding and 4 µm thickness tissue sections were stained with hematoxylin and eosin (H&E). The special stainings, particularly periodic acid Schiff's reaction (PAS) and alcian blue, pH 2.5, were performed at the Department of Pathology, Faculty of Veterinary Science, Chulalongkorn University,

Thailand. The preservative solution of the case was re-collected, centrifuged and observed for oocysts.

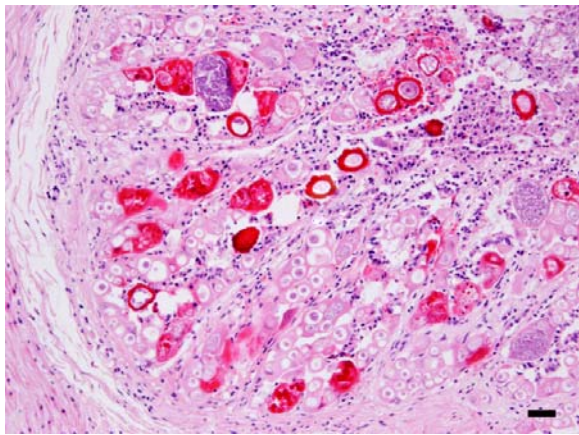
### Results and Discussion

The gross pathological findings demonstrated severe mucohemorrhagic enteritis along the jejunum and ileum that were associated with intussusception of the jejunal part (Fig 1). The carcass was dehydrated carcass with a decrease subcutaneous fat. The liver and spleen were dark red and swollen referring to congestion. Pulmonary congestion was also found.

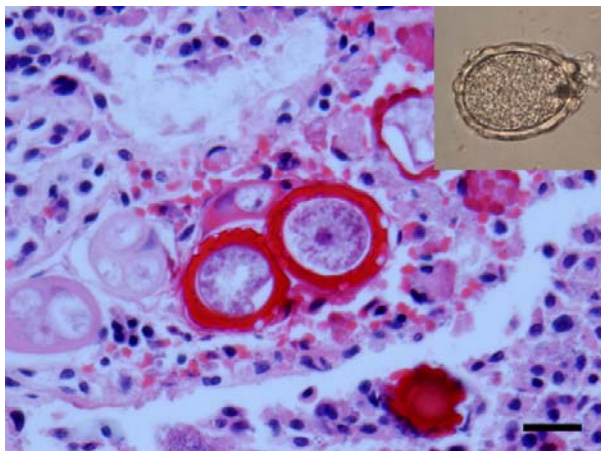
Histopathologically, severe necrohemorrhagic jejunitis was exclusively detected. All gametogony stages; gametocytes, zygotes and



**Figure 1** The lumen of jejunum showed muco-hemorrhagic content and congestion of intestinal mucosa. Ruler in centimeters.



**Figure 2** Various endogenous stages of the coccidian protozoa; gametocytes, unsporulated oocysts, present in the enterocytes. Bar = 100  $\mu$ m



**Figure 3** The unsporulated oocysts presented among the sloughed epithelial cells, bacteria and necrotic debris in the intestinal lumen. H&E stain (inset). A formalin-fixed unsporulated oocyst is spheroid with outer thick wall. Bar = 20  $\mu$ m

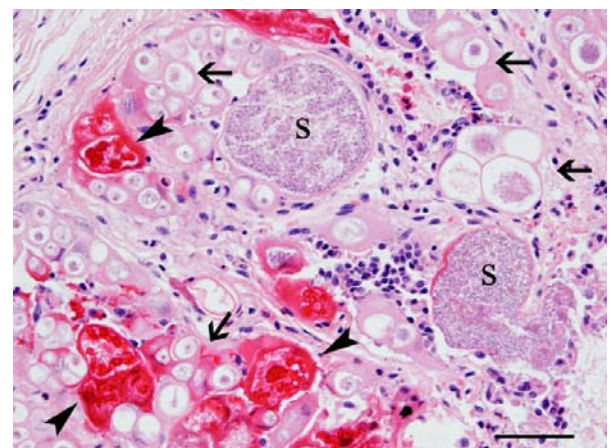
oocyst as well as schizonts of *E. pachylepyron* were presented in the enterocytes (Fig 2). Many unsporulated oocysts were presented in the intestinal lumen with severely sloughed epithelial cells, bacteria and necrotic debris. Moreover, the round unsporulated oocysts of these coccidian protozoa were distinctly irregular to knobbed homogeneous eosinophilic thick outer layer and thin, translucently, smooth inner layer of the oocyst wall (Fig 3). The diameter of round oocysts including with the thick wall in the histologic section were  $32 \pm 9$   $\mu$ m on average (ranging from 28 to 46  $\mu$ m). The outer layer and the inner layer walls were 6-8  $\mu$ m and 1  $\mu$ m thick, respectively with the central round unsporulated oocyst. The outer layer of oocyst wall was strongly PAS-positive despite alcian-blue-negative staining. The size of unsporulated oocysts in formalin solution was spheroid and slightly larger than theirs on histological sections. Most enterocytes throughout the villi were parasitized by immature oocysts, schizonts and macrogamonts, especially the crypt of Lieberkühn was more severely parasitized. A cluster of 2-3 immature oocysts and macrogamonts with eosinophilic wall-forming bodies were commonly found in each enterocyte. The immature oocysts and macrogamonts were approximately 11-41 and 40-46  $\mu$ m in diameter, respectively. The schizonts had thick eosinophilic wall with numerous

merozoites. The size of schizonts was approximately 70-95  $\mu$ m and contained numerous small, 1-1.5  $\mu$ m long, sickle shaped merozoites (Fig 4).

Other histopathological findings were multifocal coagulative necrotic suppurative hepatitis, mild suppurative splenitis with moderate lymphoid necrosis and mild membrano-proliferative glomerulonephritis. There were no pathological findings in the duodenum, lung, heart and stomach.

Previously, all eimeria species in slow loris were retrieved from the feces and intestinal scraping (Patnaik and Acharjyo, 1970; Colley and Mullin, 1972; Duszynski et al., 1999). Since *E. pachylepyron* oocysts were reported from the fecal survey in Malaysia in 1972, there have not been further reports about this coccidian (Colley and Mullin, 1972; Duszynski et al., 1999). This present case was accidentally found in the routine necropsy. The pathomorphology of the unsporulated oocysts was closely similar to *E. pachylepyron* sporulated oocysts than *E. lemuris* sporulated oocysts (Poelma, 1966; Colley and Mullin, 1972). The thick wall of round unsporulated oocysts differed from *E. lemuris* (Poelma, 1966). In addition, this pet was not exposed to any apes of African origin that are the host of *E. kemuris*.

The unsporulated oocysts of this coccidian, which had distinctly irregular eosinophilic thick outer layer of the oocyst, were easily seen in the histopathological sections. The thick outer wall was composed of neutral mucopolysaccharides composition, which was strongly stained by PAS. The size of the unsporulated oocysts in this case was slightly larger than the previous report, which sporulated oocysts were found in the immature stage. Most parasitic organisms in the case were in the gametogony stage and the enterocytes were severely affected. The cycles of this coccidian replication were not declared from the case. Most epithelial cells were possibly damaged and also led to secondary bacterial infection and caused septicemia. Unfortunately, bacterial identification was not successfully cultured. However, the cause of death might be coccidiosis with secondary bacterial septicemia because the liver showed severe hepatic necrosis.



**Figure 4** Immature oocysts (arrows), macrogamonts (arrowheads) and schizonts (S) predominantly presented in the crypt of Lieberkühn. Bar = 50  $\mu$ m

Based on the pathomorphology of the coccidian, this report revealed that the site of *E. pachylepyron* infection was the jejunum, which could possibly be the primary site for replication. This is the first report to confirm the existence of the protozoan and also the pathology in a greater slow loris (*Nycticebus coucang*).

### **Acknowledgements**

The authors would like to thank Mr. Supradit Wangnitham, the technician, for histopathological laboratory assistance.

### **References**

- Colley FC and Mullin SW 1972. *Eimeria pachylepyron* sp. n. (Protozoa: Eimeriidae) from the slow loris in Malaysia. J Parasitol. 58: 110-111.
- Duszynski DW, Wilson WD, Upton SJ and Levine ND 1999. Coccidia (Apicomplexa: Eimeriidae) in the primates and Scandentia. Int J Primatol. 20: 761-797.
- Mullin SW, Colley FC and Welch QB 1975. Ecological studies on coccidia of Malaysian forest mammals. Southeast Asian J Trop Med Public Health. 6: 93-98.
- Patnaik MM and Acharjyo LN 1970. *Eimeria nycticebi* n. sp. and *E. coucangi* n. sp. from Indian slow loris (*Nycticebus coucang*), and notes on *Isospora leonina* from an African lion (*Panthera leo leo*). Orissa Vet J. 5: 13-14.
- Poelma FG 1966. *Eimeria lemuris* n. sp., *E. galago* n. sp. and *E. otolicni* n. sp. from a Galago *Galago senegalensis*. J Protozool. 13: 547-549.