

6-1-2013

Production of Black Goat Using Laparoscopic Artificial Insemination and Embryo Transfer

Nitira Anakkul

Junpen Suwimonteerabutr

Theerawat Tharasanit

Saritvich Panyaboriban

Sarawanee Khunmanee

See next page for additional authors

Follow this and additional works at: <https://digital.car.chula.ac.th/tjvm>



Part of the [Veterinary Medicine Commons](#)

Recommended Citation

Anakkul, Nitira; Suwimonteerabutr, Junpen; Tharasanit, Theerawat; Panyaboriban, Saritvich; Khunmanee, Sarawanee; Thanomsuksinchai, Natthakarn; and Techakumphu¹, Mongkol (2013) "Production of Black Goat Using Laparoscopic Artificial Insemination and Embryo Transfer," *The Thai Journal of Veterinary Medicine*: Vol. 43: Iss. 2, Article 12.

Available at: <https://digital.car.chula.ac.th/tjvm/vol43/iss2/12>

This Article is brought to you for free and open access by the Chulalongkorn Journal Online (CUJO) at Chula Digital Collections. It has been accepted for inclusion in The Thai Journal of Veterinary Medicine by an authorized editor of Chula Digital Collections. For more information, please contact ChulaDC@car.chula.ac.th.

Production of Black Goat Using Laparoscopic Artificial Insemination and Embryo Transfer

Authors

Nitira Anakkul, Junpen Suwimonteerabutr, Theerawat Tharasanit, Saritvich Panyaboriban, Sarawanee Khunmanee, Natthakarn Thanomsuksinchai, and Mongkol Techakumphu¹

Production of Black Goat Using Laparoscopic Artificial Insemination and Embryo Transfer

Nitira Anakkul¹ Junpen Suwimonteerabutr¹ Theerawat Tharasanit¹ Saritvich Panyaboriban¹
Sarawanee Khunmanee² Natthakarn Thanomsuksinchai² Mongkol Techakumphu^{1*}

Abstract

Laparoscopic artificial insemination (LAI) and embryo transfer (ET) were used to produce cross-bred black-colored goat. In Experiment 1, LAI with frozen-thawed semen of black buck (Australian Melaan) was performed in 75% Saanen cross-bred does (white color, n = 70). The total numbers of 68 kids were born from 50 does. The skin colors of kids born were black (10.29%), white (39.71%) and other colors (50%). In Experiment 2, two cross-breeding programs were tested including program I: frozen semen of Australian Melaan inseminated to Black Bengal female (n = 7) and program II: frozen semen of Black Bengal inseminated to 50% Australian Melaan (n = 7). For embryo transfer program, the donors were superovulated and inseminated through laparoscopy with frozen semen at 21 hours after estrus. Thirty embryos at 4-8 cell stages (day 3) were surgically collected and transferred into 30 recipients (75% Saanen cross-breed) at approximately 60 hours following LAI. Pregnancy rates were 30%. Nine kids born from both programs were black in color with 2.56±0.95 kg birth weight. It is concluded that laparoscopic insemination and embryo transfer can be successfully combined to produce and sustain the genetic potential encoding the black colored skin.

Keywords: black goat, embryo transfer, laparoscopic artificial insemination

¹Faculty of Veterinary Science, Chulalongkorn University, Bangkok 10330, Thailand,

²The Office of the Commission on Agricultural Resource Education, Chulalongkorn University, Nan 55000, Thailand

*Corresponding author: E-mail: tmongkol@chula.ac.th

บทคัดย่อ

การผลิตแพะดำด้วยการผสมเทียมด้วยเทคนิคส่องกล้องลาพาโรสโคปและการย้ายฝากตัวอ่อน

นิริรา อนักกุล¹ จันทร์เพ็ญ สุวิมลธีระบุตร¹ อีรวรรณ ธาราศานิต¹ สฤณีวิชัย ปัญญาภิบาล¹ ศราวณี ชันมณี²
ณัฐกานต์ ถนนอมสุขสินชัย² มงคล เตชะก่ำฟู^{1*}

การศึกษาในครั้งนี้ได้นำเอาการผสมเทียมด้วยเทคนิคส่องกล้องลาพาโรสโคปและการย้ายฝากตัวอ่อนมาใช้ในการผสมข้ามพันธุ์เพื่อผลิตแพะสีดำ ในการทดลองที่ 1 ทำการผสมเทียมด้วยเทคนิคส่องกล้องลาพาโรสโคปโดยใช้น้ำเชื้อแช่แข็งจากพ่อแพะสีดำพันธุ์ออสเตรเลียผสมเมลาณกับแพะสีขาวพันธุ์ซาเนน (75%) จำนวน 70 ตัว แพะตั้งท้อง 50 ตัว ได้ลูกแพะจำนวนรวม 68 ตัว โดยเป็นลูกแพะสีดำร้อยละ 10.29 สีขาวร้อยละ 39.71 และสีอื่น ๆ ร้อยละ 50 ในการทดลองที่ 2 ทำการศึกษาการผสมข้ามพันธุ์ใน 2 รูปแบบ คือ รูปแบบแรกทำการผสมเทียมแพะเพศเมียสีดำพันธุ์แบล็คเบงกอลจำนวน 7 ตัวด้วยน้ำเชื้อแช่แข็งจากพ่อแพะสีดำพันธุ์ออสเตรเลียผสมเมลาณ และรูปแบบที่สองทำการผสมเทียมแพะเพศเมียสีดำซึ่งเป็นลูกผสมออสเตรเลียผสมเมลาณ (50%) จำนวน 7 ตัวด้วยน้ำเชื้อแช่แข็งจากพ่อแพะสีดำพันธุ์แบล็คเบงกอล โดยในการย้ายฝากตัวอ่อน แพะเพศเมียตัวให้ดังกล่าวจะถูกกระตุ้นการตกไข่และได้รับการผสมเทียมด้วยเทคนิคส่องกล้องลาพาโรสโคปที่ 21 ชั่วโมง หลังแสดงอาการเป็นสัด ทำการผ่าตัดเก็บตัวอ่อนภายหลังการผสมไปแล้วประมาณ 60 ชั่วโมง ได้ตัวอ่อนจำนวน 30 ใบที่ระยะ 4 ถึง 8 เซลล์ (อายุ 3 วัน) อัตราการตั้งท้องจากการย้ายฝากไปยังแพะตัวรับจำนวน 30 ตัวเท่ากับร้อยละ 30 ลูกแพะทั้งหมด 9 ตัวที่ผลิตได้จากทั้งสองรูปแบบการผสมมีสีดำ มีน้ำหนักแรกเกิดเฉลี่ย 2.56 ± 0.95 กก. สามารถสรุปได้ว่าการนำเอาการผสมเทียมด้วยเทคนิคส่องกล้องลาพาโรสโคปมาใช้ร่วมกับการย้ายฝากตัวอ่อนประสบความสำเร็จในการผลิตและรักษาศักยภาพทางพันธุกรรมในการรักษาลักษณะการแสดงออกของสีดำ

คำสำคัญ: แพะสีดำ การย้ายฝากตัวอ่อน การผสมเทียมด้วยเทคนิคส่องกล้องลาพาโรสโคป

¹ ภาควิชา สัตวศาสตร์ เชนเวชวิทยา และ วิทยาการสืบพันธุ์ คณะสัตวแพทยศาสตร์ จุฬาลงกรณ์มหาวิทยาลัย กรุงเทพฯ 10330

² สำนักงานคณะกรรมการการศึกษาวิจัยทรัพยากรการเกษตร จุฬาลงกรณ์มหาวิทยาลัย จังหวัดน่าน 55000

*ผู้รับผิดชอบบทความ E-mail: tmongkol@chula.ac.th

Introduction

In Thailand, black goats are in demand and more expensive compared to other colors. However, when black goats are mated with goats in other colors, coat colors of offspring are remarkably variable (Asdell and Buchanan Smith, 1928). This is due to the fact that white, brown and tan colors are dominant over black color (Asdell and Buchanan Smith 1928; Adalsteinsson et al., 1994; Sponenberg and LaMarsh, 1996). Skin color is genetically controlled by the presence of two subtypes of melanin pigments (eumelanin and phaeomelanin). The eumelanin is predominantly produced from tyrosine and represents black color while the other pigment typically expresses reddish brown or tan color. Although melanocytes can produce both types of pigments, eumelanin is genetically recessive (Asdell and Buchanan Smith, 1928). In order to produce black offspring, mating between two breeds of black goats should be performed (Sponenberg et al., 1998). Australian Melaan (AM) is a black goat breed developed in Australia. This breed is considered hardy, disease resistant and high production. Black Bengal (BB) is a common name for a small breed black goat found in Bangladesh and Northeast India. Its

skin softness and excellent meat quality are main characteristics (Amin et al., 2000). Genetic improvement of the BB goat could be achieved by selection and cross-breeding (Amin et al., 2000).

Cross-breeding by the application of assisted reproduction technologies (ART) results in the utilization of hybrid vigor for commercial production. Artificial insemination (AI) is a basic tool for genetic improvement worldwide especially with frozen-thawed semen (Leboeuf et al., 2000). In order to get higher pregnancy rates with post-thaw semen, the spermatozoa should be deposited directly into the uterus using laparoscopic artificial insemination (LAI) (Sohnrey and Holtz, 2005). While this cross-bred LAI improves the genetics via male germplasm, superovulation followed by embryo recovery and embryo transfer (ET) is a successful method for distributing superior female genes (Isthwar and Memon, 1996). There are two techniques for collecting and transferring embryos, regarding the stage of embryo development. The embryos beyond eight-cell stage should be collected and transferred to the uterus, while early stage (embryos containing less than 8 cells) should be transferred into the oviducts (Ramon-Ugalde et al., 2008). A higher recovery rate and viability of embryos were reported when

embryos were collected in the early stage via oviductal flushing (Ramon-Ugalde et al., 2008). Therefore, this study aimed at examining whether or not the production of black goat offspring using LAI, superovulation as well as ET techniques were efficiently performed.

Materials and Methods

Experimental animals: This study was approved by the Institutional Animal Care and Use Committee (IACUC), Chulalongkorn University (Approval No. 11310030). All female goats, aged between 2 to 4 years old, were used in this experiment. Animal facility was located at the CU-Network for Academic Opportunities and Services, Chulalongkorn University (Nan Province, Thailand, 18°N latitude and 100°E longitude). The animals were fed on concentrates containing 14% (w/w) protein, ad libitum of grass with free access to mineral salt blocks and water.

Experimental design:

Experiment 1: LAI with frozen-thawed semen of AM was performed in 75% Saanen cross-bred does (n = 70) in order to study the offspring's coat color.

Experiment 2: Two cross-breeding programs were tested using LAI and ET techniques. These included program I: frozen semen of AM inseminated to BB female (n = 7) and program II: frozen semen of BB inseminated to 50% AM (black color does born from Experiment 1) (n = 7). Donors from both programs were inseminated using LAI technique. Embryos were collected at 60 hours after LAI and then transferred to recipients does (75% Saanen crossbred does).

Estrus synchronization: The does in experiment 1 (n = 70) were estrus synchronized using intravaginal sponge (Sincro-gest sponges; 65 mg of medroxyprogesterone, Ovejero®, Spain) for 13 days together with an injection of 300 IU pregnant mare serum gonadotropin (PMSG, Folligon®, Intervet Schering-Plough Animal Health, The Netherlands) before sponge removal.

The recipient does in experiment 2 (n = 40) were estrus synchronized at the same period as the donors. The program was as described above with an injection of 200 IU human chorionic gonadotropin (hCG; Chorulon®, Intervet Schering-Plough Animal Health, The Netherlands) when the estrus sign was detected in order to induce an ovulation.

Superovulation: The donors in Experiment 2 (n = 14) were synchronized and superovulated as previously described by Shin et al. (2008) and Lehloenya and Greyling (2010) with minor modifications. The estrous cycle of the donors was controlled by an intravaginal progesterone sponge (Sincro-gest sponges; 65 mg of Medroxyprogesterone, Ovejero®, Spain) for 13 days. A total of 200 mg of follicle stimulating hormone (FSH; Folltropin V®, Bioniche Animal Health, Vetrepharm, Canada) was divided into 7 doses (50, 25, 25, 25, 25, 25 and 25 mg). The FSH was then twice-daily administrated. The first dose was started on day 10 after the progesterone sponge insertion. Two doses of

cloprostenol (125 µg/ml, Estrumate®, Schering-Plough Animal Health, NJ, USA) were administered intramuscularly at the time of the sixth and seventh FSH injections. Estrus signs were detected every 6 hours using apronized bucks. When the does were in estrus, 200 IU of hCG (Chorulon®, Intervet Schering-Plough Animal Health, The Netherlands) was given to induce ovulation and the LAI was then performed 21 hours later.

Laparoscopic artificial insemination (LAI): All does submitted to the operation were restricted from feed for 24 hours and water for 12 hours (Mobini et al., 2012). They were intravenously anesthetized with xylazine HCl (0.1 mg/kg) and ketamine HCl (4.4 mg/kg). The analgesic drug (0.04 mg/kg phenylbutazone) and antibiotic (20,000 IU/kg penicillin-streptomycin) were also given intramuscularly. The does were positioned on a trolley in dorsal recumbency with the head tilted down at about 45° angle. After ovarian observation to confirm the presence of graafian follicles, post-thaw sperm (60×10^6 spermatozoa in 0.25 ml) were inseminated into the lumen of each uterine horn at halfway between the utero-tubular junction (UTJ) and the bifurcation (Ritar et al., 1990).

Embryo transfer (ET): Approximately 60 hours following AI, the embryos were surgically collected from the donors. The goats were anesthetized as described in LAI. The numbers of recovered embryos were recorded in relation to the number of corpus luteum (CL). The reproductive tract of a donor was accessed through a mid-ventral incision. Embryos at 4-8 cell stages (day 3) were collected from superovulated donors by oviductal flushing with sterile phosphate-buffered saline infiltrated through butterfly needle (25G, 19 mm) (Fig 1A and 1B). The flushing medium was collected via a polyethylene tube with outer diameter of 1.57 mm and inner diameter of 1.14 mm (Intramedic®, Becton, Dickinson and Company, NJ, USA). The flushing

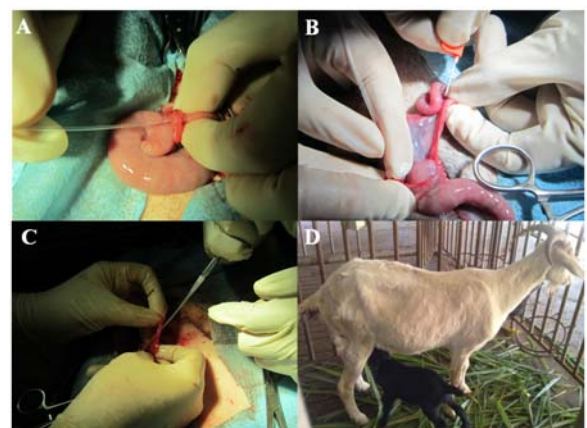


Figure 1 Oviductal flushing in superovulated donors. A: insertion of the polyethylene tube via fimbria and infundibulum and holding with fingers. B: infiltration the flushing medium at utero-tubular junction using a butterfly needle. C: insertion of an IVF catheter into the oviduct via the infundibulum of recipient to transfer the embryo. D: black kid was born by transfer the embryo to crossbred Saanen.

fluid was recovered in a sterile plastic Petri dish and the embryos were immediately searched and counted under a stereomicroscope (80x) (Nikon SMZ645, Japan). The recovered embryos were classified according to the gross morphology and only excellent and good embryos were used for ET. The fresh embryos were transferred into the oviducts of recipients ipsilateral to the presence of CL via the insertion of an IVF catheter (Veterinary Concepts®, Australia) into the oviduct (Fig 1C).

Pregnancy diagnosis: Pregnancy was confirmed at 45 days after LAI or ET by real time B-mode ultrasonography (HS-2000, Honda Electronics Co, Ltd, Japan). Skin color and birth weight of kids were recorded.

Statistical analysis: Data were descriptively analyzed. Percentage of goat showing estrus sign, pregnancy and embryo recovery are reported. The birth weights of kids are presented as mean±SD. The frequency of kids in each color was expressed as a percentage of the total number of kids born.

Results

Experiment 1: A total numbers of 68 kids were born from 50 does (pregnancy rates = 71.43%). The number of kids with black colored skin was lower than other colors (Table 1). Thirty-five does (70%) delivered one kid while the other 15 does gave birth to twins and triplets (12 and 3 does, respectively). Differences in colors were observed among twin and triplet. The average of birth weight was 2.87±0.61 kg.

Experiment 2: All donors and recipients does (35 from 40, 87.50%) came into estrus after synchronization. The mean number of CL (ovulation) in the donors was 13±6.6 (ranging from 8 to 32) while the recovery rate (unfertilized oocytes and embryos) varied from 0 to 100% (55.85±35.69%). The transferable embryos, at 2-8 cell stages when collected, were performed on day 3 after LAI. The number of embryos collected from two breeding programs (Table 2). Thirty good embryos from 11 donors (BB = 7, 50%AM = 4; 0% recovery rate in three donors) were transferred into 30 recipient does. The pregnancy rates were 30% (9/30). All nine kids were healthy and black in color (Fig 1D) with 2.56±0.95 kg birth weight.

Discussion

We found that the LAI and ET were successfully performed to maintain the phenotypic expression of black offspring when black goats were mated together. Therefore, when frozen semen of AM was inseminated to white Saanen does, the lower percentages of black kids were born as shown in experiment 1. This is due to the recessive eumelanin which controls black color, mating between black and black goats produces black offspring whereas mating between black goats and goats of other colors results in variable coat colors (Asdell and Smith, 1926; Adalsteinsson et al., 1994; Sponenberg et al., 1998).

In the embryo collection, the wide range of the success in recovery rate was in agreement with a

previous study, indicating that the results can vary from complete failure to extremely high success (Baldassarre and Karatzas, 2004). It was noted that high recovery rates were mostly obtained in does that had never received hormonal treatment. Moreover, we found that repeated treatments especially for PMSG and FSH (porcine origin) negatively affected the ovarian responses and also embryo recovery rate as remarked by Remy et al. (1991) and Cognie (1999). In addition, internal organ adhesion from previous LAI and surgical ET also impair the procedure during embryo collection (Suyadi et al., 2000).

All black offspring born from both breeding programs were healthy with higher birth weight (2.56±0.95) than the average birth weight of BB kids born at this breeding center (1.81±0.26 kg) or in Bangladesh (1.08±0.06 kg, Paul et al., 2011) but slightly lower than kids born in Experiment 1 (2.87±0.61). This black colored skin is controlled by the production of melanin pigments from melanocytes in response to the alpha melanocyte stimulating hormone (Jackson, 1994; Hoekstra, 2006). Although melanocytes can produce both eumelanins and pheomelanins, the phenotypic expression of the black colored hair and skin is mediated by only eumelanin. While the mechanism that controls the hair and skin color is well described in mouse, similar mechanisms remain to be studied in goat. Practically, our study demonstrated that crossbred black goats can be produced via LAI and ET. The production of these cross-bred goats would be phenotypically and genetically beneficial means of climate adaptation, disease tolerance and also meat production. LAI and ET combined technique provides valuable practical opportunity to improve reproductive efficiency and to enhance genetic improvements.

Table 1 Skin colors of goat offspring from Australian Melaan (frozen semen) and 75% Saanen cross-bred does.

Offspring	Skin			Total
	Black	White	Other	
n	7	27	34	68
%	10.29	39.71	50	

Table 2 Number of embryos collected from two breeding programs.

Breeding program	Frozen semen	Donor	No. of donors	No. of embryos	No. of kids
1	AM	BB	7/7	18	6
2	BB	50%AM	4/7*	12	3

AM: Australian Melaan, BB: Black Bengal

*Recovery rate: 0 in three donors

Acknowledgements

This work was supported by the grant of Chulalongkorn University Centenary Academic Development Project, RGJ-PhD-industrial link program, Thailand Research Fund (PHD/0156/2550) and The 90th Anniversary of Chulalongkorn University Fund (Ratchadaphiseksomphot Endowment Fund).

References

- Adalsteinsson S, Sponenberg DP, Alexieva S and Russel AJF 1994. Inheritance of goat coat colors. *J Hered.* 85: 267-272.
- Amin MR, Husain SS and Islam ABMM 2000. Evaluation of Black Bengal goats and their cross with the Jamunapari breed for carcass characteristics. *Small Rumin Res.* 38: 211-215.
- Asdell SA and Buchanan Smith AD 1928. Inheritance of color, beard, tassels and horn in the goat. *J Hered.* 19: 425-430.
- Baldassarre H and Karatzas CN 2004. Advanced assisted reproduction technologies (ART) in goats. *Anim Reprod Sci.* 82-83: 255-266.
- Cognie Y 1999. State of the art in sheep-goat embryo transfer. *Theriogenology* 51: 105-116.
- Hoekstra HE 2006. Genetics, development and evolution of adaptive pigmentation in vertebrates. *Heredity* 97: 222-234.
- Ishwar AK and Memon MA 1996. Embryo transfer in sheep and goats: a review. *Small Rumin Res.* 19: 35-43.
- Jackson IJ 1994. Molecular and developmental genetics of mouse coat color. *Annu Rev Genet.* 28: 189-217.
- Leboeuf B, Restall B and Salomon S 2000. Production and storage of goat semen for artificial insemination. *Anim Reprod Sci.* 62: 113-141.
- Lehloeny KC and Greyling JPC 2010. The ovarian response and embryo recovery rate in Boer goat does following different superovulation protocols, during the breeding season. *Small Rumin Res.* 88: 38-43.
- Mobini S, Heath AM and Pugh DG 2012. *Theriogenology of sheep and goats.* In: *Sheep and Goat Medicine.* 2nd ed. DG Pugh and N Baird (eds). USA: WB Saunders Company. 129-186.
- Paul S, Khandoker MAMY, Moinuddin MA and Paul RC 2011. Characterization of Black Bengal goat. *J Bangladesh Agril Univ.* 9: 61-66.
- Ramon-Ugalde JP, Folch J, Cocero MJ, Piña-Aguilar RE and Alabart, J.L. 2008. Embryo recovery from the oviduct in superovulated ewes: A method to improve MOET systems. *Czech J Anim Sci.* 53: 145-151.
- Remy B, Baril G, Vallet JC, Dufour R, Chouvet C, Saumande J, Chupin D and Beckers JF 1991. Are antibodies responsible for a decreased superovulatory response in goats which have been treated repeatedly with porcine follicle-stimulating hormone? *Theriogenology* 36: 389-399.
- Ritar AJ, Ball PD and O'May PJ 1990. Examination of methods for the deep freezing of goat semen. *Reprod Fertil Dev.* 2: 27-34.
- Shin ST, Jang SK, Yang HS, Lee OK, Shim YH, Choi WI, Lee DS, Lee GS, Cho JK, Lee YW 2008. Laparoscopy vs. laparotomy for embryo transfer to produce transgenic goats (*Capra hircus*). *J Vet Sci.* 9: 103-107.
- Sohnrey B and Holtz W 2005. Technical Note: Transcervical deep corneal insemination of goats. *J Anim Sci.* 83: 1543-1548.
- Sponenberg DP, Alexieva S and Adalsteinsson S 1998. Inheritance of color in Angora goats. *Genet Sel Evol.* 30: 385-395.
- Sponenberg DP and LaMarsh C 1996. Dominant and recessive brown in goats. *Gen Sel Evol.* 28: 117-120.
- Suyadi, Sohnrey B and Holtz W 2000. Transcervical embryo collection in Boer goats. *Small Rumin Res.* 36: 195-200.

