

10-1-1985

Severe tuberculous kyphosis : a new method of correction

P. Itiravivong

Follow this and additional works at: <https://digital.car.chula.ac.th/clmjournal>



Part of the [Medicine and Health Sciences Commons](#)

Recommended Citation

Itiravivong, P. (1985) "Severe tuberculous kyphosis : a new method of correction," *Chulalongkorn Medical Journal*: Vol. 29: Iss. 10, Article 9.

DOI: 10.58837/CHULA.CMJ.29.10.9

Available at: <https://digital.car.chula.ac.th/clmjournal/vol29/iss10/9>

This Case Report is brought to you for free and open access by the Chulalongkorn Journal Online (CUJO) at Chula Digital Collections. It has been accepted for inclusion in Chulalongkorn Medical Journal by an authorized editor of Chula Digital Collections. For more information, please contact ChulaDC@car.chula.ac.th.

Severe tuberculous kyphosis : a new method of correction

Pibul Itiravivong*

Itiravivong P. Severe tuberculous kyphosis : a new method of correction. Chula Med J 1985 Oct; 29 (10) : 1121-1129

Two teenaged patients with severe tuberculous kyphosis are presented in detail with a new proposed method for the correction of a rigid deformity. The procedures consisted of, firstly, a wide posterior laminectomy and anterior curettage and decompression, and secondly, a controllable, adjustable, extendable, made to measure plaster bed for the patient to lie down in for the correction. The last stage may be an anterior or posterior fusion with Harrington instrumentation, after completion of the correction. Clinically, the method was demonstrated to be neurologically safe and effective. Radiologically, a following up of over one year revealed a more than 50% correction of the initial 90° , 100° kyphotic angles.

พิบูลย์ อธิระวิวงศ์. กระดูกสันหลังโก่งจากวัณโรค : การผ่าตัดแก้หลังโก่งแผนใหม่. จุฬาลงกรณ์เวชสาร 2528 ตุลาคม; 29 (10) : 1121 - 1129

วัณโรคกระดูกสันหลังชนิดโก่งรุนแรงเป็นภาวะที่ทำให้ผู้ป่วยได้รับความทุกข์ทรมานมาก ทั้งนี้จากกระดูกสันหลังที่โก่งมากทำให้ปวดหลังได้ตลอดเวลา และมีโอกาสจะโก่งมากขึ้นจนทำให้เกิดไขประสาทสันหลังเป็นอัมพาตได้ ผู้รายงานได้รายงานผู้ป่วยวัยรุ่น 2 รายที่มีกระดูกสันหลังโก่ง 90 และ 100 องศาจากวัณโรคกระดูกสันหลัง และได้เสนอวิธีการผ่าตัด 3 ขั้นตอนคือ ขั้นตอนแรก wide posterior laminectomy และ anterior curettage and decompression ขั้นที่สอง ให้ผู้ป่วยนอนราบใน plaster bed ซึ่งสามารถทำให้แน่นเพื่อแก้ไขกระดูกสันหลังตรงขึ้นทีละน้อย ขั้นที่สาม ผ่าตัดเชื่อมกระดูกสันหลังทางด้านหน้าเสริมด้วยกระดูก หรือผ่าตัดเชื่อมกระดูกสันหลังทางด้านหลังแล้วใส่โลหะ Harrington rod จากวิธีการนี้สามารถแก้ไขกระดูกสันหลังโก่งในผู้ป่วยทั้งสองรายได้มากกว่า 50 เปอร์เซ็นต์

Tuberculosis of the spine is not an uncommon disease, especially in developing countries. In Thailand, though the exact figure is not known, in the past three years there has been approximately 28 cases per year at just one medical university hospital, Chulalongkorn.

Tuberculosis of the spine can be successfully treated medically, if detected early. In late tuberculosis of the spine where parts of the vertebra or a few vertebrae are involved and with abscess formation, conservative management is usually not adequate and has to be supplemented with surgical curettage. The posterior surgical approach, by means of cleaning and debridement in an attempt to get rid of the diseased tissue, has proved to be an ineffective procedure in most cases. Anterior surgical curettage and decompression^(1,2) is a more logical approach as it directly attack the abscess and non-vitalized vertebrae. In the same procedure rib grafts are usually seated into the vertebral gap to give some stability and to promote healing. However, such a procedure of anterior approach and rib grafts is not capable of correcting cases of tuberculosis of the spine with severe kyphosis.^(1,3,2) A more radical approach has to be employed in treating such severe deformities, which may be a combination of laminectomy, anterior decompression and or Harrington instrumentation.^(4,1,2) These are extensive procedures with a high risk and great danger to the neural tissue. Some employ a Halo-pelvic apparatus^(5,3,2) to correct this severe kyphotic deformity in the initial stage. This is an external fixator employing

many pins anchored into the skull and pelvic bones, to apply a distraction force to the deformity and is also not without great danger.⁽³⁾ Though it has proved to be very successful in some specialized spinal centers, it can not be universally put to use as the procedure is very complicated and not-advisable in ill-prepared and ill-equipped centres. In order to avoid the danger of cranial nerve injury from a Halo-pelvic apparatus, some surgeons choose the Halo-femoral traction.^(5,6) But again, this apparatus is mechanically unsound, because the femoral traction is distant from the diseased area and thus, not able to exert enough distraction force to effectively correct the kyphotic deformity. It is not within the scope of this article to discuss in detail the advantages and disadvantages of all mentioned procedures, as they are already covered in many literatures.

If one looks into all these methods, there is one thing in common, that is, they all try to find a way of correcting the nasty kyphotic deformity effectively and safely. The aim of this paper is to propose a new method of correction. It is an effective and safe procedure, and can perhaps be employed in any general hospital with some spinal facility. The method includes a surgical posterior decompressive laminectomy an anterior decompression, and a readily applicable made-to-measured plaster bed. The rigid kyphotic deformity is made loose by the anterior and posterior resections of vertebral structures and the created vertebral instability is controlled by the plaster bed. (Fig. 1)

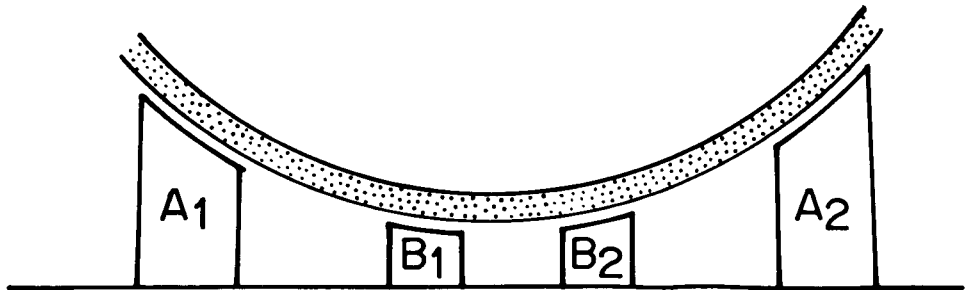


Figure 1. Made-to-measure plaster bed.

The plaster bed, which is supported by two wooden bars, is then transversely

broken at the point of maximal angulation. (Fig. 2)

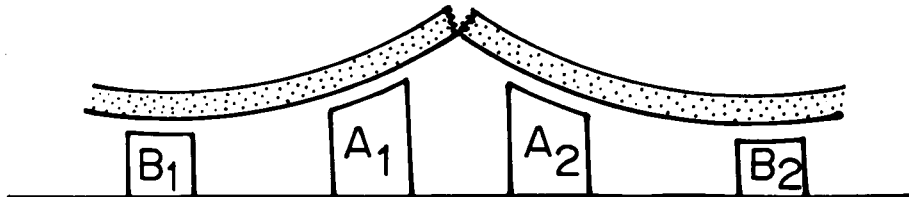


Figure 2. Plaster bed broken for correction.

The gradual extension of the plaster bed is then brought about with the help of gravity and by replacing the initial tall wooden bars with shorter ones. The neurological status can be monitored at any time during this correction. As the patient is fully awake most of the time, there is no risk at all to the spinal cord and cauda equina and one would be surprised to see the amount of correction obtained by such means. Once the final correction is achieved, another operation is performed

to add bone grafts to the newly aligned and more-straightened vertebrae in order to create stability and promote further permanent bony healing.

Case Demonstration 1

A fifteen year old girl was admitted with a three year history of deformed back and pain at the right buttock. There was no back pain but frequent attacks of the pain in the buttock was noted recently. She was weak and occasionally was unable to walk due to the pain a few

days prior to admission. Examination revealed a clinically-ill patient with short body. There was a markedly rigid kyphoscoliosis in the thoracolumbar region but no neurological deficit of lower limbs was detected. No sign of upper motor neurone lesions was demonstrated and other systems were normal. Chest films showed that the heart and lungs were within normal limit. The thoracolumbar films revealed bone destruction of the bodies of T12, L1 and L2, involving the disc spaces and the collapsed vertebrate. (Fig. 3,4) and showed a paravertebral mass with calcification at the level of T12-L2, bilaterally. Marked Kyphoscoliosis of the thoracolumbar spines

was observed, measuring 90° in kyphosis. Her blood picture was 8600 WBC, 63% segmented neutrophils, 35% lymphocytes 2% monocytes, ESR 79 mm/hr. There was no problem in the diagnosis as this was obviously a classical case of spinal tuberculosis. The main problem was how the rigid kyphosis could be treated effectively. Initially, the patient received anti-tuberculous drugs with supportive measures to regain her general health. A month later, surgical resection of the kyphos at T12, L1, L2 was performed by means of a wide laminectomy. After two weeks, a mild degree of correction was noted with an 82° kyphotic angle on X-rays. (Fig. 5)

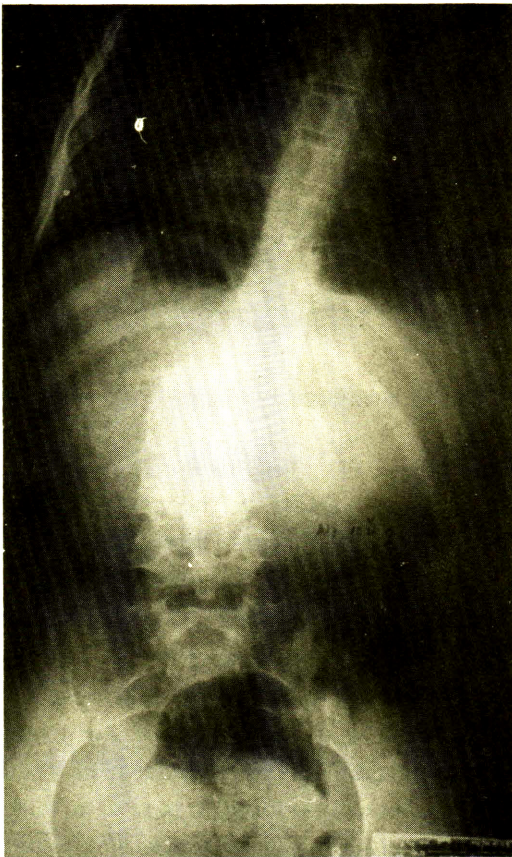


Figure 3. AP view of tubercular spine.

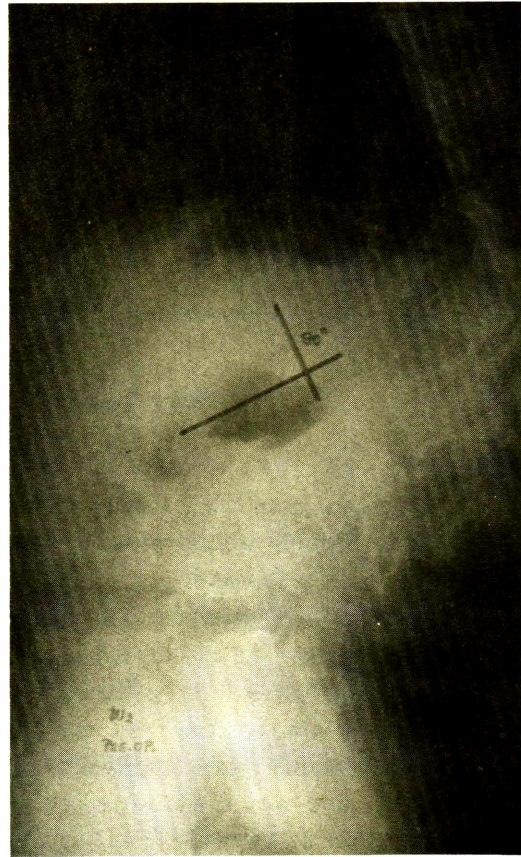

Figure 4. Pre-operative view : 90° kyphosis.

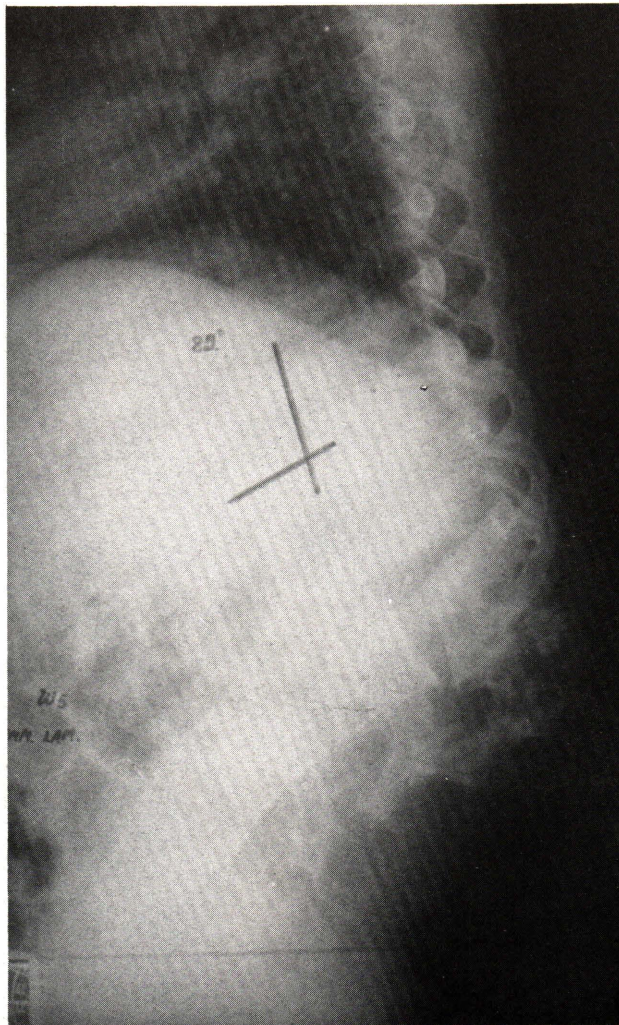


Figure 5. Post wide laminectomy.

Once the wound healed, a plaster bed was built, made-to-measure, and the patient practiced lying in it several times a day. Three weeks after the first operation, a second stage, anterior spinal curettage and decompression of the diseased vertebrae T12, L1, L2 was carried out. The patient was placed into the plaster bed immediately after surgery. The rigidly severe kyphotic deformity now made loose and unstable by the two operations, could now be con-

trolled by the properly-fitted plaster bed. When the patient fully recovered from anesthesia and was in less pain, the correction was begun. Because of the pre-cut of the plaster bed as mentioned, the correction was commenced by the gradual extension of the plaster bed with different lengths of wooden bars. Neurological status was examined daily. After a period of three weeks, maximal correction was accomplished. Posterior fusion was performed,

stabilized by double Harrington rods. X-ray films now showed a reduction of kyphotic

angle to 45° (Fig. 6).

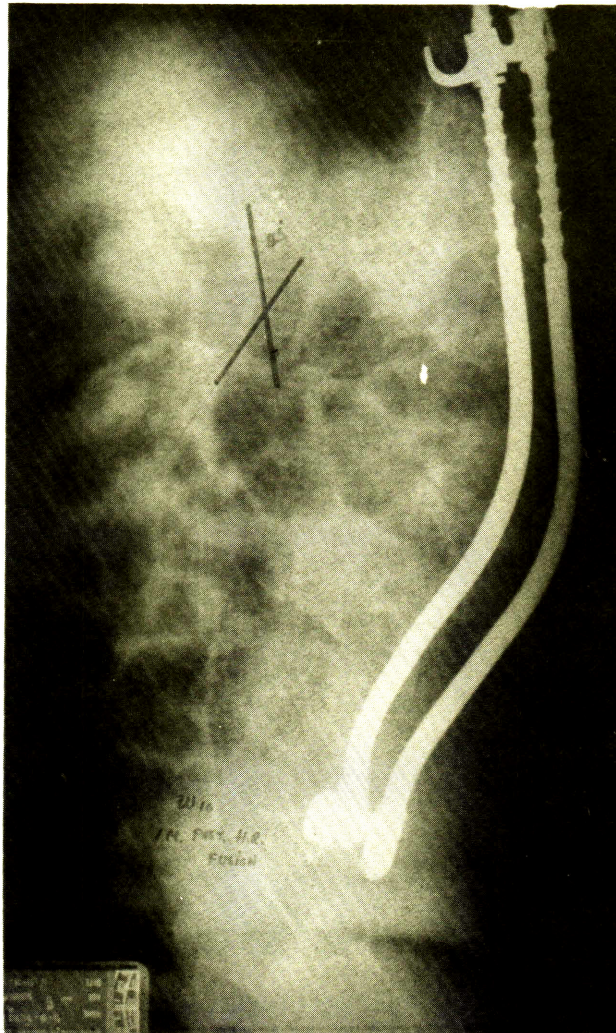


Figure 6. Final correction.

This meant that 50% correction was achieved without any damage to the neural tissue. The patient was then ambulated with spinal jacket and was self-independent. The last step of the procedure would have been an anterior fusion for the vertebral gap by the insertion of iliac bone graft. Unfortunately, the patient was so happy

with her condition after correction that she asked for a postponement. Presently at the follow-up of 14 months, a slight loss of correction was noted and the kyphotic angle was 50° (Fig. 7).

Case Demonstration 2

A thirteen year old boy was noticed to have a prominent back since the age

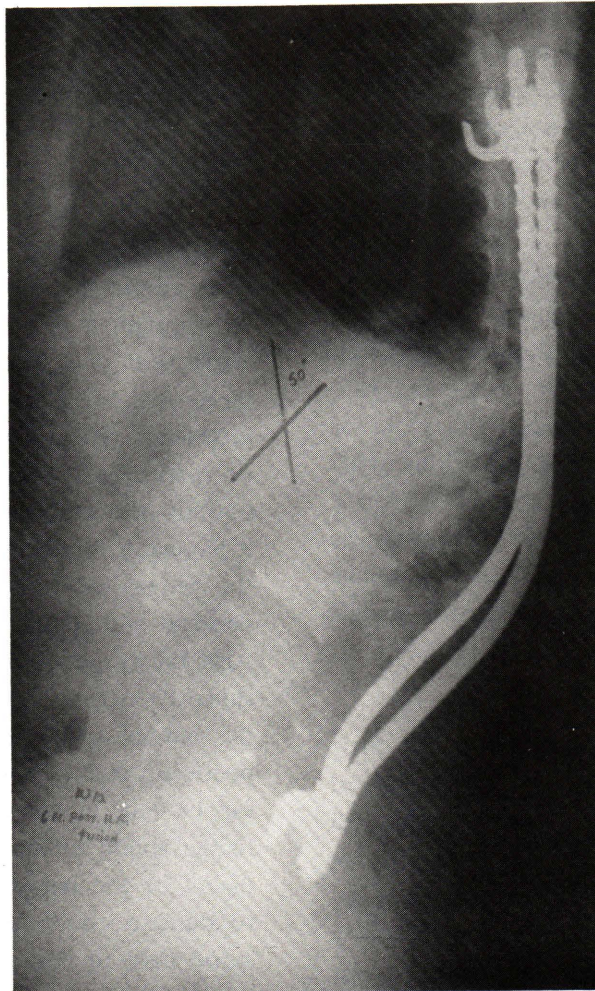


Figure 7. 14 months post-operative.

of three after an accidental fall. The prominence deteriorated with time and became an obvious kyphosis at the age of ten. This patient was seen in consultation because of the deformed spine and progressive weakness of his left lower extremity. Physical examination revealed a hard kyphosis at the thoracolumbar region and grade II motor power of the left lower limb. Chest X-rays showed no pulmonary infiltration and a normal limit for his heart. Thoracolumbar spinal a X-rays showed fragmentation of the bodies of T12, L1, L2, L3

and a kyphotic angle of 100° , which varied between 100° to 95° on flexion and extension. After a period of antituberculous chemotherapy and supportive measures, a wide posterior laminectomy from T10 to L3 was performed. This initial surgery reduced the kyphotic angle to 75° . Two weeks later, anterior curettage and decompression were carried out as a second stage and the patient was immediately put into a trial plaster spinal jacket. The spinal jacket was fitted with a turn-buckle apparatus aimed to assist the correction but

did not work, had to be abandoned and the patient was placed into the made-to-measure plaster bed. Gradual extension was carefully initiated in a similar manner to case I. More correction was obtained by this method and after three weeks, the kyphotic angle was 45° . We interpreted this as more than 50% correction without clinical signs of neurological damage. The patient was then ambulated in a spinal jacket, which he was able to do independently in a very short period. A plan for an anterior spinal fusion with iliac graft was designed for this patient within a month. Due to unforeseen circumstances this has not been done, and up to a follow up period of 12 months there was a gradual loss of correction from 45° to 70° .

Discussion

In most cases of spinal tuberculosis without severe deformity, anterior surgical curettage and rib graft can be performed with good results.^(4,1,2) To correct cases with rigid kyphotic deformity is not an easy task, especially when the deformity is so severe, as in the two demonstrated cases. To achieve up to about 50% correction is considered highly satisfactory⁽²⁾, if such correction does not create any neurological damage. Avoiding injury to the neural tissue is very important. It is far better for the patients, to remain kyphosed and self ambulant than to have straighter back and paralysed. There is no rush when treating a rigid kyphotic deformity of spine. Both the Halo-pelvic apparatus and Halo-pelvic traction takes time for the gradual correction after which another period is required for the accompanying anterior and or posterior decompression and spinal fusion. As mentioned,

only specialized centres have the right to employ such a sophisticated apparatus without encountering a lot of complications^(6,3,2) and perhaps irreversible neural damage.

The proposed method in this article is quite simple and safe. It can be universally employed in any general hospital. All through it requires time for a gradual correction in a plaster bed, it takes no longer than the Halo-pelvic or Halo-femoral procedures. When one thinks of the amount of correction obtained, the safety of the patient and the burden to the surgeon, it is quite a remarkable procedure. However, the patient has to be informed, must understand and co-operate during throughout. Also the surgeon must have the necessary skill to perform these spinal surgeries^(4,2) i.e., anterior spinal decompression and wide posterior resection of the kyphosis which can be done in one or two stages according to the ability of the surgeon and the condition of the patient. One must be able to build a good plaster bed and understand how to operate it during the correction. Initially, the author selected the one stage-operation, starting with a wide posterior laminectomy at the kyphosis, followed by anterior spinal curettage and decompression two to three weeks later. The plaster bed was applied immediately at the end of the second operation. Anterior spinal fusion with iliac bone graft had been planned at maximal correction, approximately after another three weeks. During the correction period the neurological condition was monitored daily which was quite easy as the patient was fully awake. Any neurological deficit that might have occurred could have been effectively

prevented by controlling the extension of the break in the plaster bed. There were no complications in this series. The co-operation of the patient was an important factor. In the second case, the kyphotic deformity had been corrected to more than 50%, but unfortunately, due to lack of understanding, the final step of anterior spinal fusion with an iliac graft had not been performed and this resulted in a gradual loss of 20% of correction by the end of one year. This would not have happened if co-operation had been maintained.

Summary

A new method of correcting severe

tuberculous kyphosis is proposed. The initial step is to make loose the rigid kyphotic deformity by a posterior resection of the kyphose and an anterior curettage and decompression of the diseased vertebrae. The second step consisted of controlling the loosely unstable vertebrae segments in an adjustable plaster bed and of correcting the kyphotic deformity by the gradual extension of the plaster bed with the aids of the patient's own body weight and gravity. The two demonstrated cases of 90° and 100° kyphotic angles showed more than 50% corrections. The method had proved to be neurologically safe, effectively, and could be universally employed in any general hospital.

อ้างอิง

1. O'Brien JP. Kyphosis secondary to Infections Disease. Clin Orthop 1977 Oct; 128 : 56-64
2. Yau CMC, Hsu LCS, O'Brien JP, Hodgson AR. Tuberculous Kyphosis : correction with spinal osteotomy with spinal osteotomy, halo-pelvic distraction, and anterior and posterior fusion. J Bone Joint Surg 1974 (Am) Oct; 56 A (7) : 1419-1434
3. O'Brien JP, Yau CMC, Smith TK, Hodgson AR. Halo-pelvic traction. J Bone Joint Surg 1971 (Br) May; 53 B (2) : 217-229
4. Bradford DS, Winter RB, Lonstein JB, Moe JH. Techniques of anterior spinal surgery for management of kyphosis. Clin Orthop 1977 Oct; 128 : 129-139
5. DeWald RL, Ray RP. Skeletal traction for the treatment of severe scoliosis : the University of Illinois halo-hoop apparatus. J Bone Joint Surg (Am) 1970 Mar ; 52 A (2) : 233-238
6. Kostuik JP. Indications for the use of the Halo-Immobilization. Clin Orthop 1981 Jan-Feb; 154 : 46-50