

3-1-2013

## ECG Quiz

Chollada Buranakarl

Suwanakiet Sawangkoon

Chutamas Benjanirut

Monkon Trisiroj

Thanusorn Phakhawambodee

Follow this and additional works at: <https://digital.car.chula.ac.th/tjvm>



Part of the [Veterinary Medicine Commons](#)

---

### Recommended Citation

Buranakarl, Chollada; Sawangkoon, Suwanakiet; Benjanirut, Chutamas; Trisiroj, Monkon; and Phakhawambodee, Thanusorn (2013) "ECG Quiz," *The Thai Journal of Veterinary Medicine*: Vol. 43: Iss. 1, Article 8.

Available at: <https://digital.car.chula.ac.th/tjvm/vol43/iss1/8>

This Other is brought to you for free and open access by the Chulalongkorn Journal Online (CUJO) at Chula Digital Collections. It has been accepted for inclusion in The Thai Journal of Veterinary Medicine by an authorized editor of Chula Digital Collections. For more information, please contact [ChulaDC@car.chula.ac.th](mailto:ChulaDC@car.chula.ac.th).

## ECG Quiz

**Chollada Buranakarl<sup>1</sup> Suwanakiet Sawangkoon<sup>1</sup> Chutamas Benjanirut<sup>1</sup> Monkon Trisiriroj<sup>2</sup>  
Thanusorn Phakhawambodee<sup>2</sup>**

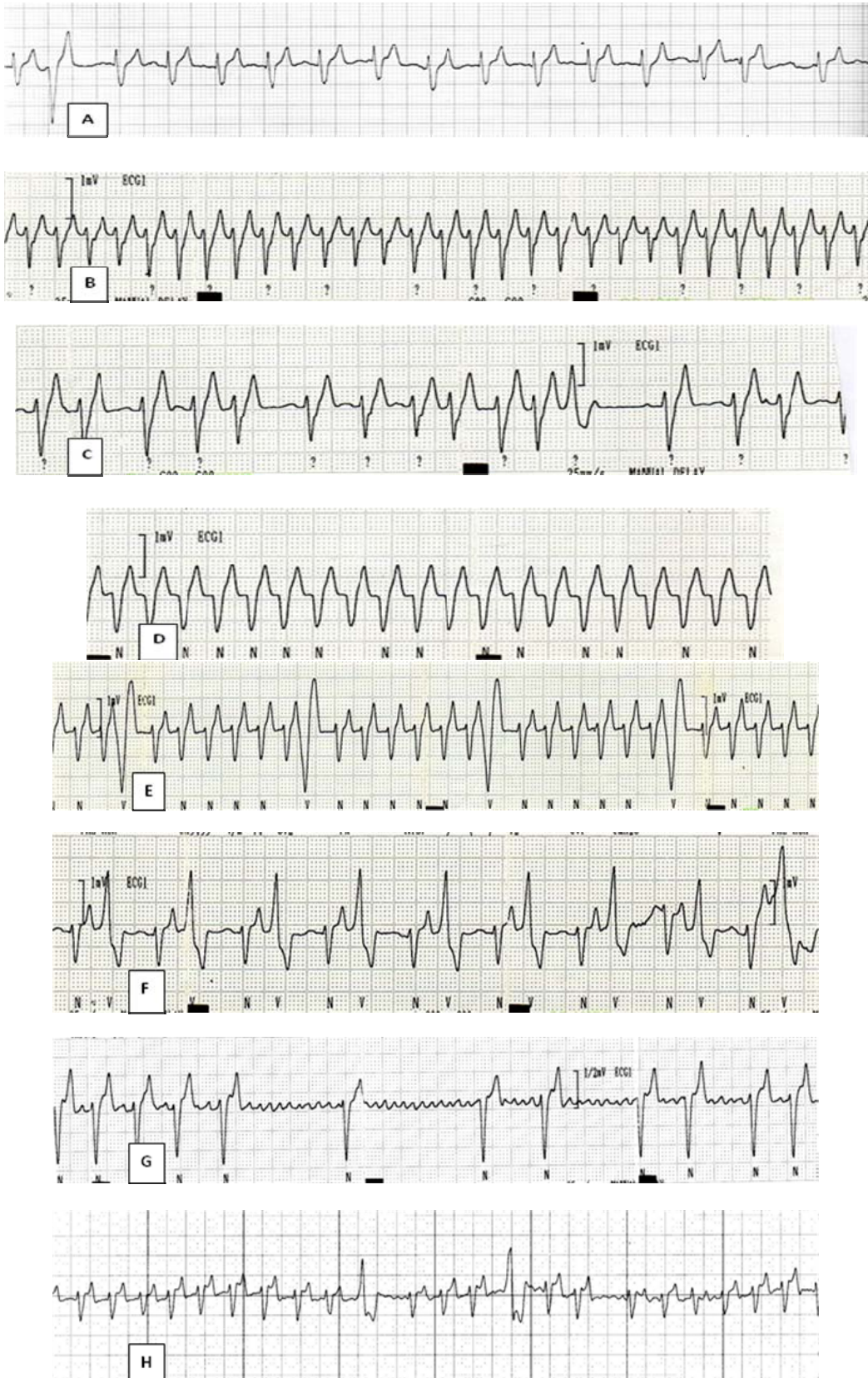
### *History*

The twelve years old female spayed Saint Bernard weighting 53 kg. was presented at the Small Animal Teaching Hospital, Chulalongkorn University on the 3, Dec 2012 with history of generalized jaundice and abdominal pain. The ECG was recorded as seen in tracing A. The complete blood count showed mild anemia (PCV = 35%) with white blood cell count of 16,100 cells/mm<sup>3</sup>. The hepatic enzyme (Alanine transaminase, ALT) increased to 823 units while the alkaline phosphatase was 937 units. The total bilirubin increased to 9.8 mg/dl. The concentrations of plasma creatinine and blood urea nitrogen were 0.7 mg/dl and 8 mg/dl, respectively. The platelet count was 263,000 cells/mm<sup>3</sup>. Ehrlichia spp., was found from the blood smear. Leptospirosis results both from antibody titer and by performing PCR that showed negative results. The abdominal ultrasonography showed that the hepatic parenchyma was mildly heterogeneous. The gall bladder wall was irregularly thickened with edema; bile sediment was found. There were diffused hypoechoic splenic masses with the greatest diameter of 7.5 x 9.0 cm. No evidence of peritoneal fluid was found. The dog was treated with doxycycline and was given the hepatic support drugs along with fluid therapy. On 7, Dec 2012, the dog was still lethargy and platelet count declined to 26,000 cell/mm<sup>3</sup>. The platelet transfusion was performed on that day. The jaundice became less remarked and liver enzyme declined within 2 weeks. On 19, Dec 2012 the packed cell volume dropped to 28%. Plasma concentrations of total protein and albumin were 5.8 g/dl and 2.5 g/dl, respectively. The platelet count was 383,000 cells/mm<sup>3</sup>. However, the dog had episodes of periodic fever and hyperpnea. The peripheral edema was noticed at both highlimbs. The enterobacter spp. was found from hemoculture along with numerous toxic neutrophils. On 21, Dec 2012 splenectomy was performed. The heart rate during anesthesia was more than 250 beats/minute while the systolic blood pressure was 90 mmHg.

Histopathologic finding of the spleen revealed only nodular hyperplasia. Heart rate and electrocardiogram were monitored continuously after the operation. The ECG after the operation showed the paroxysm type and the heart rate could be accelerated from 150 to more than 300 beats/minute. The duration of tachycardia was sustained for more than 2 hours each time. Beside antibiotic therapy, antiarrhythmic drugs, amiodarone and carvedilol were prescribed along with other cardiac drugs for treatment of underlying dilated cardiomyopathy. The ECGs on day 1 after administration of antiarrhythmic drugs were shown in tracing B and C. The heart rate was still high on the next day; another pattern of ECG was found as shown in tracing D. The basal heart rate was declined with the maximum of 250, 220 and 200 on days 4, 11 and 18 after drug administrations, respectively. However, on day 8 after operation dog had severe peripheral edema. The total protein and albumin were declined to 5.0 and 2.3 g/dl, respectively, while the central venous pressure (CVP) was risen (> 20 cm H<sub>2</sub>O). Dog showed sign of tachypnea with low arterial blood oxygen content. The thoracic radiograph revealed pleural effusion especially on the right side of the thorax. Thoracocentesis was performed and 480 ml of fluid was removed. Digitalis glycoside was added on day 11 after amiodalone treatment in order to control tachycardia. It was noticed that sustained paroxysm seemed to be shorten along with the reduction in the maximal heart rate. Examples of ECG with arrhythmia on day 12 and 23 after operation were shown in tracing E and F. The ECG on 21, Jan 2013, 4 days before discharge was shown in tracing G. The dog was healthier; neither peripheral edema nor pleural effusion was found. The blood collection results showed normal CBC and blood chemistries. The ECG was re-performed on 28, Feb 2013 as shown in tracing H.

---

<sup>1</sup>Department of Veterinary Physiology, <sup>2</sup>Small Animal Hospital, Faculty of Veterinary Science, Chulalongkorn University



Please answer before turning to the next page.

## Interpretation

- Tracing A - Right bundle block with supraventricular and ventricular premature complexes
- Tracing B - Supraventricular tachycardia
- Tracing C - Respiratory sinus arrhythmia with one premature ectopic complex
- Tracing D - Supraventricular or ventricular tachycardia
- Tracing E - Sinus rhythm with periodic ventricular complexes
- Tracing F - Ventricular bigeminy
- Tracing G - Atrial flutter
- Tracing H - Atrial fibrillation and periodic VPCs.

Tracing A showed the usual baseline ECG of this dog with dilated cardiomyopathy (DCM) before splenectomy. The heart rate was approximately 150 beats/minute. The deep S-wave with a slow conduction indicated the presence of right bundle block in this dog. The abnormal bizarre shape of a complex at the beginning of the tracing (star) indicated ventricular premature complex, while the complex with similar shape which occurred prematurely, corresponded to the supraventricular premature complex (solid circle). The height of p-waves was too low to be seen and may be confused with atrial fibrillation. After splenectomy was performed (tracing B), the heart rate was accelerated and increased up to 250-300 beats/minute. The cause of increased heart rate was unknown but the presence of ventricular ectopic beats with accelerated rate could be seen in some situation eg. gastric dilation valvulus or splenic mass. The circulation inside the abdominal organs with sympathetic nerve activation was suspected. The shape of the complexes in tracing B was similar to the pattern of ventricular tachycardia (VT). However, this sustained tachycardia lasted for almost 1 week. Its shape and the normal sinus complexes with right bundle branch block were alike in this dog. Therefore, complexes were emerged from supraventricular origin. Tracing C was recorded on the same day as B when the heart rate was switching back to slow rate. The sinus complexes were seen with one ectopic beat (small arrow). The origin of ectopic focus could not be determined but the vector of ventricular excitation was pointed out toward the positive electrode of lead II (left leg). The closely couple between ectopic beat and preceding normal beat may accentuate ventricular contraction causing more blood ejected through the semilunar valve before its closing. Thus, the pulse deficit may occur. Tracing D indicated tachycardia in which the shape of ECG complex was different from tracing B. It is possible that these complexes were originated either from the same site shown in tracing B or from ventricular ectopic focus which was called "ventricular tachycardia; VT). If the VT was present, it was the malignant ECG waveform that created the hemodynamic instability especially when the rate was high. Antiarrhythmic drugs should be considered if

the dog had signs of tachypnea or cyanosis.

In tracing E although the dog was recovered from the operation, ventricular ectopic complexes were still seen. The pattern may be varied which in this case would be emerged after 4 beats of sinus complexes. The fixed intervals between VPCs and the preceding sinus complexes made these VPCs come from the mechanism of re-entry. This re-entry may be present as sinus complexes followed by alternating VPCs as seen in tracing F (bigeminy pattern). The closely couple VPCs after normal sinus beats made the semilunar valve still opened; and 2 complexes were created one systole with one pulse. Thus, the pulse rate or heart rate measured by an auscultation was only half of the complexes measured from ECG. Tracing G indicated sinus arrhythmia with a slow rate (83 beats/minute). Please notice the saw tooth-like pattern of p-waves (big arrow). This pattern was called "atrial flutter" which was seen when the ectopic foci were originated from the atrial myocardial cells. Impulses travelled toward atrioventricular node many times before some would be able to pass into the ventricle while the AV node was not in refractoriness. This ECG was considered as one type of the atrio-ventricular block. The bombarding of impulses made the varying degree of the refractory period of the AV node. Thus, the R-R interval in case of animal with atrial flutter and/or atrial fibrillation was inconsistent. Tracing H showed the ECG after 2 months of recovery. The right bundle branch block was still present with some VPCs. The unseen p-wave and flatten line in front of QRS complexes indicated that there was no p-wave. The inconsistent R-R intervals were also used as a marker for atrial fibrillation. Impulses may be originated from many ectopic sites inside the atrium and could be travelled in many directions causing the sum of vectors pointed isopotentially. Atrial contraction could not occur simultaneously which was not contributed to diastolic ventricular filling. After 3 months of recovery, the dog had mild exercise intolerance but could be able to walk for a short distance. Prolongation of amiodarone was withheld since it raised the hepatic enzyme in this dog but the beta-blocker, carvedilol, was still maintained along with other cardiac drugs for DCM.



