

12-1-2012

## In Field Fracture Management in Horses

Carstanjen Bianca

Siewruk Kasia

Gajewski Zdzislaw

Follow this and additional works at: <https://digital.car.chula.ac.th/tjvm>



Part of the [Veterinary Medicine Commons](#)

---

### Recommended Citation

Bianca, Carstanjen; Kasia, Siewruk; and Zdzislaw, Gajewski (2012) "In Field Fracture Management in Horses," *The Thai Journal of Veterinary Medicine*: Vol. 42: Iss. 4, Article 1.

Available at: <https://digital.car.chula.ac.th/tjvm/vol42/iss4/1>

This Article is brought to you for free and open access by the Chulalongkorn Journal Online (CUJO) at Chula Digital Collections. It has been accepted for inclusion in The Thai Journal of Veterinary Medicine by an authorized editor of Chula Digital Collections. For more information, please contact [ChulaDC@car.chula.ac.th](mailto:ChulaDC@car.chula.ac.th).

## **In Field Fracture Management in Horses**

**Carstanjen Bianca\* Siewruk Kasia Gajewski Zdzislaw**

### *Abstract*

Veterinary practitioners can be confronted with limb fractures in all types of horses. Immediate evaluation of the horse's vital parameters, diagnosis, medication and stabilization of the fractured limb with splint bandages or fiberglass cast are of uppermost importance for a possible therapy. Adequate professional transportation of the horse with a fracture to a specialized referral center for diagnosis and therapy is crucial for a positive treatment strategy. This summary article describes in field emergency management of the equine patient with a fracture.

---

**Keywords:** emergency therapy, fracture, horse, transport

*Department of Large Animal Disease, Faculty of Veterinary Medicine, Warsaw University of Life Sciences, 02-786 Warsaw, Poland*

**\*Corresponding author E-mail:** bcarstanjen@web.de

## บทคัดย่อ

### การจัดการภาวะกระดูกหักในสนามม้า

Carstanjen Bianca\* Siewruk Kasia Gajewski Zdzislaw

สัตวแพทย์ผู้ซึ่งปฏิบัติการในท้องที่มักพบปัญหากระดูกหักในม้าได้ค่อนข้างบ่อย หลักสำคัญในการประเมินความสำคัญในการให้การรักษาคือ การประเมินสภาพสัตว์ การวินิจฉัย การให้การรักษาทันที การยึดตามข้อต่อที่เสียหาย นอกจากนี้การขนย้ายสัตว์ ไปยังโรงพยาบาลอื่นๆ เพื่อการวินิจฉัยและการรักษา นับเป็นสิ่งสำคัญยิ่ง ดังนั้นในบทความนี้จะกล่าวการจัดการปัญหากระดูกหักในม้าในภาวะฉุกเฉิน

คำสำคัญ: การรักษาในภาวะฉุกเฉิน กระดูกหัก ม้า การขนส่ง

Department of Large Animal Disease, Faculty of Veterinary Medicine, Warsaw University of Life Sciences, 02-786 Warsaw, Poland

\*Corresponding author E-mail: bcarstanjen@web.de

### Introduction

Fractures of the appendicular skeleton occur in sport, pleasure and pasture horses (Walmsley, 1996; Parkin et al. 2005). A variety of limb fractures can be successfully treated in specialized referral centers (Table 1) (Carter et al. 1993; Nixon, 1996<sup>a</sup>). Factors that affect prognosis are fracture type and location, open or closed fracture, degree of vascular and soft tissue damage, the horse's temperament, age, weight and time frame between injury and fracture repair (Nixon, 1996<sup>a</sup>). The referring veterinarian plays a key role, as inappropriate initial treatment and transport of the patient with a fracture might make a planned surgical intervention impossible (Mudge and Bramlage, 2006). Emergency management of the horse with a fracture should aim to avoid further damage to the injured limb and allow the horse to a safe, painless and as stress free as possible transportation to the referral center (Bramlage, 1996; Walmsley, 1996; Mudge and Bramlage; 2006; Fürst et al. 2009; Carstanjen and Rattenhuber, 2010). This article describes the investigation of a horse with a fracture, the stabilization of fore- and hindlimb fractures, the medication and the adequate transport of to a referral center.

### Examination of horse with suspected fracture

Horses with a suspicion of a fracture should be thoroughly examined in a quiet atmosphere (Walmsley et al., 1996). At competitions and events, curious spectators should be kept away from the injured horse. General physical examination shows the horse's vital signs such as body temperature, heart and respiratory rate and mucous membranes. Cases of deaths from fracture-associated blood loss and fatigue are described (Walmsley, 1996). Examination of the musculoskeletal system follows the general

examination. Uncooperative, anxious and painful patients must often be restrained to examine the injured region of the limb (Mudge and Bramlage, 2006). Extremely painful patients should obtain systemical non steroidal anti-inflammatory drugs (NSAIDs), for example flunixin meglumine, phenylbutazone or ketoprofen, before limb stabilization; otherwise NSAIDs are applied for its anti-inflammatory and analgetic effect after the stabilization. Furthermore, an adequate stabilization of the fracture reduces anxiety and pain of the patient.  $\alpha$ -2-agonists should only be used with extreme care in selected cases because it might produce a transient uncontrollable weight bearing of the affected limb associated with ataxia.

The skin around the fracture site is examined for skin and soft tissue lesions because additional injuries influence the horse's prognosis negatively. Each acutely severely lame horse must be treated as a

**Table 1** Main therapy options and prognoses of principal fractures in horses.

| Fracture location          | Treatment | Prognosis            |
|----------------------------|-----------|----------------------|
| Distal phalanx             | M or S    | Good to guarded      |
| Middle phalanx             | M or S    | Guarded              |
| Proximal phalanx           | S (M)     | Excellent to guarded |
| Proximal sesamoids         | S (M)     | Good to poor         |
| Metacarpal/<br>-tarsal III | S         | Excellent to poor    |
| Radius                     | S (M)     | Good to poor         |
| Ulna                       | S         | Good to guarded      |
| Humerus                    | M         | Excellent to poor    |
| Scapula                    | S         | Guarded to poor      |
| Tibia                      | S         | Good to poor         |
| Patella                    | S         | Guarded to good      |
| Femur                      | S (M)     | Guarded to poor      |

M: Medical treatment; S: Surgical treatment (Modified according to McIlwraith and Orsini, 2003; Frisbie, 2012).

patient with a fracture until a fracture or a fissure can be excluded. In horses with a fracture combined with a wound, the fracture stabilization with a splint bandage or a fiberglass cast has uppermost priority; to limit the risk of soft tissue trauma and fracture dislocation. The wound care should be restricted to wound exploration and cleaning. Systemic antimicrobial therapy, for example penicillin and gentamicin, should be started in cases with an open fracture or severely traumatized soft tissue. The tetanus protection of the horse must be guaranteed. For unknown vaccination status the tetanus titer should be evaluated or the animal should be treated with tetanus antitoxin.

### Diagnostic imaging techniques

The affected limb of patients with unstable fractures should be firstly stabilized by external coaptation and by using radiolucent materials such as wooden rods, polyvinyl chloride (PVC) splints or fiberglass cast material. In the second step, the stabilized limb is evaluated with radiographs (two or more diagnostic directions). Under field condition, and without the possibility to perform radiographs, the veterinarian should professionally stabilize the horse suspicious for a fracture and refer it to a specialized referral center for diagnosis and possible therapy.

### Prognosis

The outcome of horses treated for fractures depends upon various factors such as fracture type and localization, the horse's weight and temperament, and the surgical skills of the veterinarians (Nixon, 1996<sup>a,b</sup>; Walmsley, 1996). Proximal forelimb fractures in horses weighing more than 300kg are difficult to treat (Walmsley, 1996). The increased body weight and the associated increased forces on the corresponding injured bone increase the risk for complications, implant failure and laminitis of the contra-lateral limb. An overview concerning the therapeutic outcome of principal fractures is shown in Table 1. Hopeless cases with a very poor prognosis should no longer be transported. These horses should be euthanized, with the owner's agreement, at or near the accident site for welfare reasons (Fürst et al., 2009). The horse owners should be noted that an official pathological evaluation might be necessary in some liability and insurance issues.


### Stabilization of the limb

Horses with suspicion of a fracture/fissure must be immobilized and stabilized properly, since such a lesion can turn into an open fracture with a poor prognosis. The principle in emergency fracture stabilization is to include the joints next to the fracture in the stabilizing bandage to ensure adequate immobilization of the affected location. The Robert Jones bandage is a bandage with a diameter of at least three times the diameter of the limb and serves for the immobilization of a limb. However, the Robert Jones bandage is insufficient to stabilize a broken limb (Campbell, 1996). For stabilization of a fractured limb,

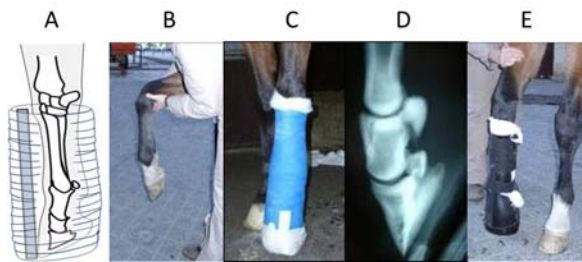materials, for example PVC splints, wooden or metal rods, are used. These inexpensive, but poorly moldable splint materials are combined with an adequate limb bandage. The professionally applied bandage is extremely important, as the traumatized tissue will swell after the trauma, which can lead to complications such as bruising and strangulation. Depending on the fracture/fissure location, the splints are usually attached at a 90 degree angle between each other and by using non-elastic adhesive tape. Improperly performed stabilization may lead to slippage of the splints with potentially irreversible and fatal consequences. Another option for fracture stabilization is the fiberglass cast. The cast consists of an elastic fiber or polyester fabric that is coated with plastic resin. The fiberglass cast is light weight and is usually easier to apply than conventional splints; however, the high price is a disadvantage.

For external emergency stabilization, the horse's limbs are functionally divided in four zones (zones I to IV; Bramlage, 1996; Fig 1).

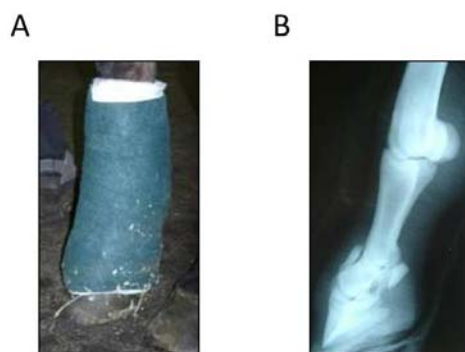
Fore- and hindlimb stabilization is treated differently because of the anatomical and biomechanical differences of these limbs. The forelimb Zone I ranges from the hoof to the distal cannon bone. The objective of stabilization of a fracture of Zone I is to stabilize the dorsal aspects of the pastern, fetlock and cannon bone in a nearly straight line (Fig 2A-E) to minimize the risk of fracture segment dislocation (Fig



**Figure 1** Functional division for external coaptation of limb fractures (Zone I to IV; modified according to Bramlage, 1996). Forelimb: Zone I: Distal cannon bone to the hoof (Distal bandage with dorsal splint), Zone II: Distal cannon bone to the distal radius (Full limb Robert Jones bandage with caudal and lateral splint), Zone III: Distal radius to the elbow joint (Full limb Robert Jones bandage with long lateral splint), Zone IV: Proximal to the elbow joint (Full limb bandage with caudal splint to lock the carpus in extension in case of triceps disruption; otherwise no immobilization is necessary). Hindlimb: Zone I: Distal cannon bone to the hoof (Distal bandage with plantar splint), Zone II: Distal cannon bone to the hock (Full limb Robert Jones bandage with plantar and lateral splint), Zone III: Hock to stifle (Full limb Robert Jones bandage with long lateral splint); Zone IV: Proximal to the stifle (No immobilization is necessary).



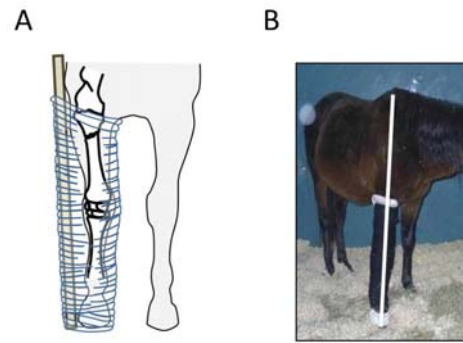
**Figure 2** Heel elevation and distal limb bandage with dorsal splint for stabilization of zone I fracture (P2 fracture) of the forelimb. Schematically (modified according to Bramlage, 1996) (A), Application of a heel wedge (B), Distal limb fiberglass cast (C) and the corresponding radiographic image of the distal phalanges. The phalanges are aligned (D). Splinting of the distal limb with a Monkey-splint (E).



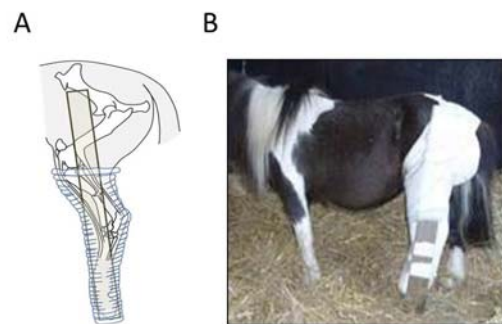
**Figure 3** Improper application of a fiberglass cast without heel elevation for stabilization of a fracture in Zone I (P2 fracture; A). The corresponding radiographic image shows fragment dislocations (B).

3A-B). A high heel wedge is applied to the hoof (Fig 2C). A splint-bandage is applied to the distal limb with the splint attached at the dorsal aspect of the limb extending from the hoof to the proximal metacarpal region (Fig 2A). Alternatively, a fiberglass cast can be applied which includes the foot with a high heel wedge and extends to the proximal cannon bone. The commercially available Monkey- or Kimzey splint (Fig 2E) can be used for emergency stabilization instead of using the non-moldable splint or an expensive fiberglass cast. Advantage of these commercially available splints is the cost-effectiveness and the ease in use. Disadvantage of this splinting system is the absent/reduced latero-medial stability of the distal limb, which makes the Kimzey-splint inappropriate for emergency condylar fracture or fissure stabilization (Mudge and Bramlage, 2006).

The forelimb Zone II ranges from the distal cannon bone to the distal radius. The stabilization of cannon bone or distal radius fractures is performed with a full limb Robert Jones bandage with caudal and lateral splint ranging from the hoof to the elbow joint. Alternatively, a full limb fiberglass cast is applied. The forelimb Zone III ranges from the distal radius to the elbow joint. The limb extensors are located at the lateral and dorsal aspect of the limb, whereas the medial aspect of the radius is not covered by muscles.



**Figure 4** Stabilization of a forelimb fracture (Zone III). Schematic design (modified, according to Bramlage, 1996) (A) and stabilization of a distal radius fracture using a full limb Robert Jones bandage and a caudal and lateral splint. The lateral splint reaches from the hoof to the scapula to counteract limb abduction (B).



**Figure 5** Stabilization of a hindlimb fracture (Zone III). Schematic view (modified according to Bramlage, 1996) by means of a lateral stabilizing wooden splint (A). Stabilization of a distal tibial fracture of the left hindlimb. The wooden splint reaching from the hoof to the *tuber coxae* and acts against an abduction of the limb (B).

Therefore, the stabilization of fractures of Zone III has the aim to avoid the abduction of the limb with medial perforation of the skin by fracture segments. A full limb Robert Jones or fiberglass cast with a lateral splint ranging from the hoof to the scapula is applied for this purpose (Fig 4A-B). The forelimb Zone IV is proximal to the elbow joint. In case of olecranon fractures with disruption of the *triceps brachii muscle*, the horse shows a lowered elbow, flexed fetlock and carpal joints (Nixon, 1996<sup>b</sup>). In this case a full limb bandage with caudal splint will lock the carpus in extension and therefore reduces the horse's anxiety by allowing weight bearing. Otherwise, Zone IV is well protected by muscles and emergency fracture immobilization/stabilization of humerus or scapula is not possible respectively necessary.

The forelimb Zone II ranges from the distal cannon bone to the distal radius. The stabilization of cannon bone or distal radius fractures is performed with a full limb Robert Jones bandage with caudal and lateral splints ranging from the hoof to the elbow joint. Alternatively, a full limb fiberglass cast is applied. The forelimb Zone III ranges from the distal radius to the elbow joint. The limb extensors are located at the lateral and dorsal aspect of the limb, whereas the medial aspect of the radius is not covered

by muscles. The stabilization of fractures of Zone III has, therefore, the aim to avoid the abduction of the limb with medial perforation of the skin by fracture segments. A full limb Robert Jones or fiberglass cast with a lateral splint ranging from the hoof to the scapula is applied for this purpose (Fig 4A-B). The forelimb Zone IV is proximal to the elbow joint. In case of olecranon fractures with disruption of the *triceps brachii muscle*, the horse shows a lowered elbow, flexed fetlock and carpal joints (Nixon, 1996<sup>b</sup>). In this case a full limb bandage with caudal splint will lock the carpus in extension and therefore reduces the horse's anxiety by allowing weight bearing. Otherwise, Zone IV is well protected by muscles and emergency fracture immobilization/stabilization of humerus or scapula is not possible respectively necessary. The hind limb Zone I range from the hoof to the distal cannon bone. Fractures in Zone I are stabilized as follows: The distal phalanges are slightly flexed by using a heel wedge. A distal limb bandage is applied with a plantar or dorsal splint ranging from the hoof to the height of the calcaneus. A fiberglass cast or a commercially available splint (see forelimb) can be alternatively applied. The hind limb Zone II ranges from the distal cannon bone to the hock. Fractures in Zone II are stabilized with a full limb Robert Jones bandage with a plantar and lateral splint that extends from the hoof to the stifle. A Full limb fiberglass cast can be alternatively applied. The horse's temperament must be considered because falling with a full limb cast might produce further injuries, for example rupture of the *peroneus tertius muscle* or a hip dislocation or femur fracture. The hind limb Zone III ranges from the hock to the stifle. Tibia fractures are difficult to stabilize because of the reciprocal apparatus. Aim of Zone III stabilization is to prevent limb abduction with skin injuries at the medial aspect of the tibia. A full limb Robert Jones bandage is applied with an extended lateral splint ranging from the hoof up to the *tuber coxae* (Fig 5A-B). Alternatively a full limb cast with a laterally extended splint can be applied. The hindlimb Zone IV is proximal to the stifle. Because of the anatomical location and the large muscles around the femur, no immobilization and stabilization is possible.

#### Transport of injured horse to a referral clinic

The transport of a horse having a fracture or having a suspicion of a fracture should be performed in a sufficiently large trailer with a front exit ramp (Mudge and Bramlage, 2006). There are vehicles that were designed for the transport of emergency horses and are equipped with special facilities such as front exit ramp, winch, or belts. An uppermost important thing is that horses are being loaded and unloaded with no loading ramp slope. Driver should avoid strong acceleration and braking maneuvers because both maneuvers increase the weight bearing/shocks on the injured limb (Mudge and Bramlage, 2006). Horses with hind limb fractures should be transported with the head in the direction of travel. Head and neck should be loosely fixed, allowing the horse to keep in balance (Bramlage, 1996). In normal horse trailers, the middle-wall can be removed to

allow the horse to better stay in balance (Rattenhuber, personal communication). Horses with forelimb fractures can be transported in specially equipped trailers with the head against the direction of travel to avoid uncontrolled excessive movements and weight bearing of the forelimb during unpredictable braking (Bramlage, 1996). Forelimb fractured patients are transported as described for hind limbs in case of availability of a normal horse-trailer for transportation. In field fracture management is essential for a successful fracture therapy in horses. Hopeless cases should be directly euthanized for ethical reason.

#### References

- Bramlage, L.R. 1996. First aid and transportation of fracture patients. In: Equine fracture repair. 1<sup>st</sup> ed. A.J. Nixon (ed). WB Saunders Company. 36-42.
- Campbell, N. 1996. Application of a Robert Jones Bandage. In: A guide to the management of emergencies at equine competitions. 1<sup>st</sup> ed. S. Dyson (ed). British Equine Veterinary Association. 21-28.
- Carstanjen, B. and Rattenhuber, S. 2010. Erstversorgung von Pferden mit Frakturverdacht. *Pferdespiegel* 13: 108-114 (in German).
- Carter, B.G., Schneider, R.K., Hardy, J., Bramlage, L.R. and Bertone, A.L. 1993. Assessment and treatment of equine humeral fractures: Retrospective study of 54 cases (1972-1990). *Equine Vet J.* 25: 203-207.
- Frisbie, D.D. 2012. Surgical treatment of joint disease. In: Equine Surgery. 4<sup>th</sup> ed. J.A. Auer and J.A. Stick (eds). Elsevier. 1123-1130.
- Fürst, A.E., Jackson, M., Keller, R. and Von Salis, B. 2009. Notfallversorgung und Transport des Frakturpferdes. *Pferdeheilkunde* 25: 302-309 (in German).
- McIlwraith, C.W., Orsini, J.A. 2003. Musculoskeletal system. In: Manual of Equine Emergencies. 2<sup>nd</sup> ed. J.A. Orsini and T.J. Divers (eds). WB Saunders Company. 343-387.
- Mudge, M.C. and Bramlage, L.R. 2006. Field fracture management. *Vet Clin Equine* 23: 117-133.
- Nixon, A.J. 1996<sup>a</sup>. General considerations in selecting cases for fracture repair. In: Equine Fracture Repair. 1<sup>st</sup> ed. A.J. Nixon (ed). WB Saunders Company. 30-35.
- Nixon, A.J. 1996<sup>b</sup>. Fractures of the ulna. In: Equine Fracture Repair. 1<sup>st</sup> ed. A.J. Nixon (ed). WB Saunders Company. 231-241.
- Parkin, T.D., Clegg, P.D., French, N.P., Proudman, C.J., Riggs, C.M., Singer, E.R., Webbon, P.M. and Morgan, K.L. 2005. Risk factors for fatal lateral condylar fracture of the third metacarpus/metatarsus in UK racing. *Equine Vet J.* 37: 192-199.
- Walmsley, J. 1996. Management of a suspected fracture. In: A Guide to the Management of Emergencies at Equine Competitions. 1<sup>st</sup> ed. S. Dyson (ed). British Equine Veterinary Association. 13-20.