

9-1-2012

ULTRASOUND DIAGNOSIS

Phiwipha Kamonrat

Follow this and additional works at: <https://digital.car.chula.ac.th/tjvm>



Part of the [Veterinary Medicine Commons](#)

Recommended Citation

Kamonrat, Phiwipha (2012) "ULTRASOUND DIAGNOSIS," *The Thai Journal of Veterinary Medicine*: Vol. 42: Iss. 3, Article 23.

Available at: <https://digital.car.chula.ac.th/tjvm/vol42/iss3/23>

This Other is brought to you for free and open access by the Chulalongkorn Journal Online (CUJO) at Chula Digital Collections. It has been accepted for inclusion in The Thai Journal of Veterinary Medicine by an authorized editor of Chula Digital Collections. For more information, please contact ChulaDC@car.chula.ac.th.

ULTRASOUND DIAGNOSIS

Phiwipha Kamonrat

History

A ten-year-old, intact, female, English Cocker dog was presented at the Chulalongkorn University, Small Animal, Veterinary Teaching Hospital for an evaluation of a progressive abdominal enlargement with an increasing liver enzyme for more than a year. The dog had been treated for skin problems and had recently showed clinical signs of anorexia, weakness, panting and intermittent vomiting. Physical examination revealed pink mucous membranes, a murmur heart sound, increased lung sound and a mild abdominal cramp. A firm mass, about 3 x 4 cm in diameter, of the right cranial mammary gland was found on palpation. Hematological profiles indicated a normal hemogram. Blood parasite was not found. Elevated alanine aminotransferase (ALT) (661 IU) and alkaline phosphatase (ALP) (1,800 IU) activities were identified on the serum biochemical analyses. Survey radiographic examinations of thorax and abdomen were performed. There were two intra-thoracic, discrete, soft tissue masses, measured 6 x 8 and 4 x 5 cm, located in the right and left caudal lung lobes, respectively. A focal area of markedly increased soft tissue opacity was also seen at the cranioventral portion of an abdomen and kidneys were caudally displaced, suggesting a condition of hepatomegaly or hepatic masses. Abdominal ultrasonography was performed to obtain more specific information.

Ultrasonographic Findings

Sagittal and transverse scans of the liver showed enlargement with rounding of the caudoventral edge. The overall liver was hypoechoic to the spleen and hyperechoic to the kidneys and falciform fat. The echogenic portal vein margin appeared less prominent compared with the hepatic parenchyma. There were two ill-defined large masses, measured about 6 and 7 cm in diameter, at the mid and left portion of the liver, respectively (Figs 1 and 2). These masses were heterogeneously hyperechoic relative to surrounding hepatic parenchyma, with irregular contour. Several hypoechoic coalescing nodules and hyperechoic patches were found within the masses. The left adrenal size was within a normal range, measured 7.4 mm thick, but the right one was enlarged, measured 18 mm thick. Ultrasonography of other abdominal organs appeared normal in echotexture. A freehand, ultrasound-guided, fine-needle aspiration of the mass in the left portion of the liver was taken (Figs 1B and 2B) and a cellular diagnosis of hepatic cirrhosis was suggested.

Diagnosis

Ultrasonographic diagnosis – Hepatic cirrhosis.

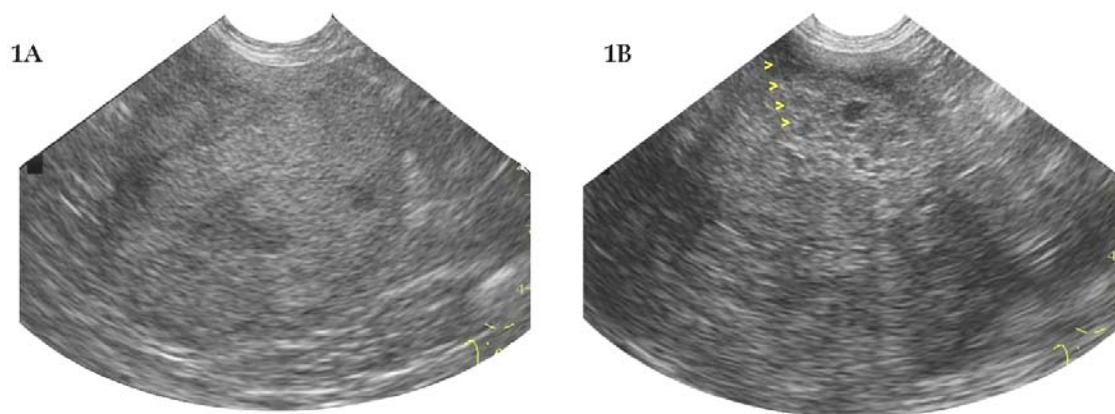


Figure 1 A. A longitudinal sonogram of the heterogeneous mass in the mid portion of the liver of a ten-year-old, intact, female, English Cocker dog in dorsal recumbency. This mass was irregular, ill-defined and containing some hypoechoic nodules and diffuse areas of patchy hyperechogenicity. B. A longitudinal image obtained during freehand, ultrasound-guided, fine-needle aspiration of the inhomogeneously hyperechoic mass in the left portion of the liver. The hyperechoic fine needle could be seen obliquely into the mass (arrowheads).

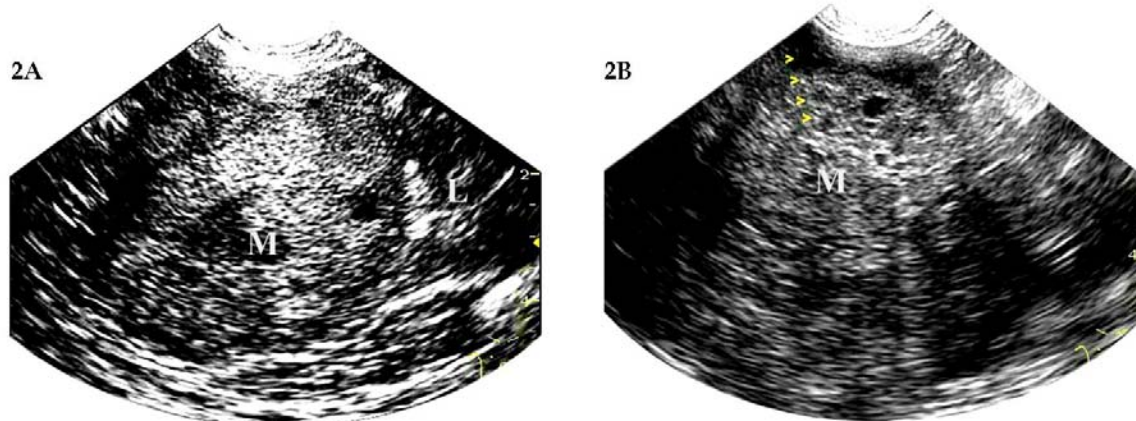


Figure 2 Schematics of the relative positions of the structures scanned in figure 1. M -heterogeneously hyperechoic mass; L -relatively hypoechoic surrounding liver parenchyma.

Comments

Ultrasonography is a valuable method for evaluating the hepatic parenchymal abnormalities in animals. Diffuse disorders are more difficult to detect than focal processes because they cause less distortion of normal hepatic architectural landmarks. Normal hepatic parenchyma ultrasonographically appears slightly hyperechoic or isoechoic to the renal cortex and hypoechoic to the spleen. Diseases that commonly cause an increase in hepatic echogenicity include fatty change, steroid hepatopathy and cirrhosis (Biller et al., 1992). Hepatic cirrhosis commonly shows a small liver with irregular border, as opposed to enlargement and smooth border of liver with fatty change. A cirrhotic liver is not always small and sometimes demonstrates multifocal lesions similar to a hepatic neoplasia (Vörös et al., 1991). A more definite diagnosis is usually based on information obtained from the history, clinical signs, physical examination, laboratory data, ultrasonography and cytological or histopathological results.

The cytologic and histologic appearances of hepatic lesions may be non-diagnostic or difficult to distinguish specifically, an ultrasound-guided liver aspiration or biopsy is mainly performed to rule out neoplasia. The pulmonary masses presented in this dog were more likely associated with the lesion of the right cranial mammary gland because percutaneous aspiration samples obtained from the gland lesion were diagnosed as adenocarcinoma.

References

- Biller, D.S., Kantrowitz, B. and Miyabayashi, T. 1992. Ultrasonography of diffuse liver disease: A review. *J Vet Int Med.* 6(2): 71-76.
- Vörös, K., Vrabély, T., Papp, L., Horváth, L. and Karsai, F. 1991. Correlation of ultrasonographic and pathomorphological findings in canine hepatic diseases. *J Small Anim Pract.* 32(12): 627-634.