

12-1-2011

Induction of Cervical Relaxation for Artificial Insemination in Sheep

Sukanya Leethongdee

Follow this and additional works at: <https://digital.car.chula.ac.th/tjvm>



Part of the [Veterinary Medicine Commons](#)

Recommended Citation

Leethongdee, Sukanya (2011) "Induction of Cervical Relaxation for Artificial Insemination in Sheep," *The Thai Journal of Veterinary Medicine*: Vol. 41: Iss. 4, Article 2.

Available at: <https://digital.car.chula.ac.th/tjvm/vol41/iss4/2>

This Article is brought to you for free and open access by the Chulalongkorn Journal Online (CUJO) at Chula Digital Collections. It has been accepted for inclusion in The Thai Journal of Veterinary Medicine by an authorized editor of Chula Digital Collections. For more information, please contact ChulaDC@car.chula.ac.th.

Induction of Cervical Relaxation for Artificial Insemination in Sheep

Sukanya Leethongdee

Abstract

In general, artificial insemination (AI) in sheep using frozen-thawed (FT) semen in commercial scale is limited due to the fact that the FT semen of sheep needs to be deposited into the uterus to achieve an acceptable fertility rate. Laparoscopic insemination with FT semen gives commercially acceptable fertility rates, however it is not economical and animal friendly. An alternative method is trans-cervical AI (TCAI). However, the unusual anatomy of the sheep cervix is a major limitation to this technique. In ewe, the cervical lumen has a convoluted and tortuous structure that looks like a corkscrew consisting of internal cervical rings. The internal folds of the cervix form a funnel-like shape with a narrow opening projecting caudally into the cervical lumen which limits the passage of inseminating pipette through cervical canal. The induction of cervical relaxation is investigated to allow deeper cervical penetration. The most significant factor in cervical relaxation is the rearrangement of collagen fibres in cervical extra cellular matrix and the changes in smooth muscle function. The application of exogenous substance increases the depth of cervical penetrability. Follicle Stimulating hormone (FSH), Hyaluronan, Misoprostol, Prostaglandin E2 (PGE2) or oxytocin is likely to induce the cervical relaxation during the periovulatory period in ewes. The greater cervical penetrability ensures the success of TCAI.

Keywords: cervix, ewe, estrous, prostaglandin-E2, transcervical artificial insemination

Department of Veterinary Clinical Science, Faculty of Veterinary and Animal Sciences, Mahasarakham University, Muang, Mahasarakham, 44000, Thailand.

Corresponding author E-mail: *sukanya.l@msu.ac.th*

บทคัดย่อ

การเหนี่ยวนำให้เกิดการคลายตัวของคอมดลูกเพื่อการผสมเทียมแบบสอดท่อผ่านคอมดลูกในแกะ

สุกัญญา ลีทองดี

การผสมเทียมโดยใช้น้ำเชื้อแช่แข็งในแกะยังไม่ประสบความสำเร็จมากนัก เนื่องจากวิธีการผสมเทียมนั้นจำเป็นต้องปล่อยน้ำเชื้อในตัวมดลูกจึงจะได้อัตราการผสมติดในระดับที่ยอมรับได้ วิธีการผสมเทียมโดยการปล่อยน้ำเชื้อในปีกมดลูกโดยการเจาะผนังช่องท้องนั้นสามารถให้ผลการผสมติดที่ยอมรับได้ แต่มีค่าใช้จ่ายสูงและส่งผลเสียต่อสวัสดิภาพสัตว์ ดังนั้นการปล่อยวางน้ำเชื้อในตัวมดลูกโดยการสอดท่อน้ำเชื้อผ่านทางคอมดลูกจึงเป็นแนวทางใหม่ที่กำลังได้รับการพัฒนาและวิจัย อย่างไรก็ตามลักษณะทางกายวิภาคอันซับซ้อนของคอมดลูกเป็นอุปสรรคสำคัญที่ทำให้การสอดท่อผสมเทียมผ่านคอมดลูกไม่สามารถทำได้อย่างมีประสิทธิภาพ เนื่องจากคอมดลูกแกะนั้นมีลักษณะคดไปมา และมีชั้นขวางอยู่ภายใน โดยทั่วไปช่องในคอมดลูกของแกะมีแนวโน้มจะเอียงตัวออกจากแนวกลาง และรอยพับภายในคอมดลูกยังทำให้เกิดลักษณะคล้ายกรวยซึ่งทำให้ยากต่อการผ่านของท่อผสมเทียม นอกจากนี้โครงสร้างทางจุลกายวิภาคของเนื้อเยื่อคอมดลูกของแกะยังเกิดจากการรวมกันของกล้ามเนื้อเรียบและเนื้อเยื่อเกี่ยวพันที่มีความแข็งแรง ทำให้ยากต่อการสอดผ่านของท่อผสมเทียม ดังนั้นการทำให้คอมดลูกคลายตัวจะสามารถทำให้การสอดท่อผสมเทียม เพื่อปล่อยน้ำเชื้อในตัวมดลูกสามารถทำได้มีประสิทธิภาพมากขึ้น การใช้สารเคมีหรือฮอร์โมนที่สามารถทำให้เกิดการคลายตัวของคอมดลูก เช่น ฮอร์โมน Follicle Stimulating Hormone (FSH) สาร hyaluronan สาร misoprostol ฮอร์โมนโพรสตาแกลนดิน อีทู (prostaglandin E2) หรือ ฮอร์โมนออกซิโตซิน (oxytocin) สามารถทำให้เกิดการคลายตัวของคอมดลูกได้ ซึ่งทำให้เกิดการเรียงตัวของกล้ามเนื้อเรียบและเนื้อเยื่อเกี่ยวพันอันเป็นโครงสร้างหลักของเนื้อเยื่อในคอมดลูก ทำให้การสอดผ่านท่อผสมเทียมสามารถกระทำได้ง่ายขึ้น และทำให้การผสมเทียมแบบการปล่อยน้ำเชื้อในตัวมดลูกโดยผ่านทางคอมดลูกประสบความสำเร็จได้

คำสำคัญ: คอมดลูก แกะ การเป็นสัด โพรสตาแกลนดินอีทู การผสมเทียมแบบสอดท่อผ่านคอมดลูก

ภาควิชาคลินิกทางสัตวแพทย์ คณะสัตวแพทยศาสตร์และสัตวศาสตร์ มหาวิทยาลัยมหาสารคาม อ.เมือง จ.มหาสารคาม 44000

*ผู้รับผิดชอบบทความ E-mail: sukanya.l@msu.ac.th

Introduction

The main role of artificial insemination (AI) in sheep production is to increase the rate of genetic improvement and allow extensive use of the superior rams. AI ensures good paternal control and fertilization of groups of female by males of different genotypes is easily achieved. In addition, AI takes advantage of estrous synchronization with its precise control of ovulation and parturition and allows the advantage of out of season breeding. This technique avoids disease transmission and reduces the risk of spreading sexually transmitted genital infections. To maximize the extensive use of superior rams, AI with frozen-thawed (FT) semen is developed. However, fertility rate from AI with FT semen is low and unaccepted commercially. At present there are three AI methods, vaginal AI, cervical AI and laparoscopic AI, all with FT semen or fresh semen. The first two techniques give poor fertility rates compared to laparoscopic AI. Eventhough the laparoscopic AI gives high fertility rate, it is not economical and animal friendly. Therefore, the transcervical AI (TCAI) technique, which semen is deposited within the uterine body through the cervical canal, is an

alternative. However, the anatomical complexity of the sheep cervix limits the success of TCAI. The induction of cervical relaxation increases the success rate of TCAI with FT semen in ewe.

Gross anatomy of sheep cervix

The sheep cervix is surrounded by a thick musculo-connective tissue wall (Moré, 1984) which an average length of the cervical canal studied in the Canadian crossbreed ewe is 6.7 ± 1.1 cm and contains 4.9 ± 1.0 funnel-shaped rings (Halbert et al., 1990) (Fig 1). The cervix has a convoluted and tortuous corkscrew-like structure consisting of internal cervical rings (Halbert et al., 1990; Naqvi et al., 2005; Kaabi et al., 2006). The internal folds of the cervix form a funnel-like shape with the narrow opening projecting caudally into the cervical lumen (Halbert et al., 1990; Naqvi et al., 2005). It is common that the second fold is eccentric to the other concentric folds and thus acts as an anatomical and physiological barrier (Moré, 1984). The cervical lumen is misaligned in 74.43% of ewes with the presence of eccentric folds. The most common eccentricity occurs at the second cervical ring (75%), but the third (14%) and first ring (11%) can

also be eccentric (Kaabi et al., 2006). The complexity of the cervix limits the passage of the inseminating pipette through the cervical canal. The difficulty of cervical penetration in sheep prevents the development of the trans-cervical artificial insemination, which the frozen-thawed semen is attempted to deposit intra uterine of sheep.

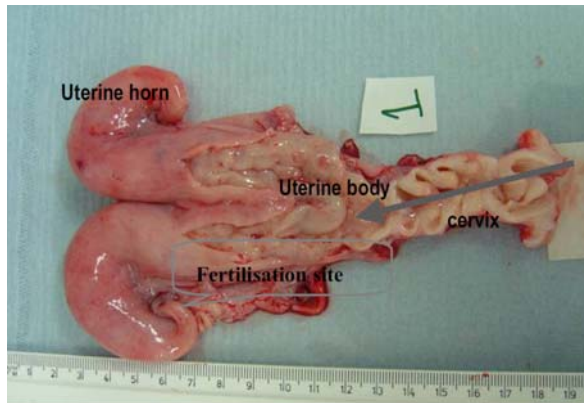


Figure 1 Morphology of sheep cervix during the periovarulatory period of estrus (Leethongdee, 2010)

Histological anatomy of the sheep cervix

The sheep cervical canal is lined by epithelium comprising of non-secretory tall columnar cells and mucous secreting goblet cells. Beneath the epithelium lies the cervical stroma made up of fibroblast-like stromal cells and thick bundles of collagen fiber orientated in all directions. The blood vessels and smooth muscle cells are embedded between the collagen bundles and other components of the extracellular matrix (ECM) such as proteoglycans, glycosaminoglycans (Dobson, 1988). Generally, in transverse section, the sheep cervix comprises three layers: 1) a luminal epithelium 2) a collagen layer of collagen bundles, stromal and smooth muscle cells and 3) an outer layer called the serosa (Moré, 1984).

1. The epithelium: The lumen of the cervix is lined with a mucosal epithelium. At the external os the cervical lumen is lined by stratified squamous epithelium of 4 to 6 layers. The epithelium gradually changes to a simple columnar epithelium at the internal os (the entrance to the uterus). Three morphologically distinct cell types have been identified by electron microscopy; tall ciliated cells, non-ciliated secretory cells and wedge-shaped peg cells (William, 1979). The epithelium is arranged over the cervical rings and does not form coiled or tubular glands as in the uterus. The cyclic changes of the estrous cycle influence the appearance of the epithelium as in all the parts of the female reproductive tract (Dobson, 1988). The height of epithelium is maximal during estrus when mucoid secretory activity is also maximal.

2. The cervical musculature lies between the surface epithelium and serosa, and comprises five well-defined tissue layers (Moré, 1984).

2.1) The sub-epithelial stroma immediately lying beneath the surface epithelium is a thin layer of loose connective tissue. It is about 600-750 μm thick. This layer contains fibroblasts and some longitudinal smooth muscle fibres embedded in ECM made up of reticular collagenous fibres and other components of connective tissue and a ground substance comprising of proteoglycans and glycosaminoglycans. The reticular collagen fiber is predominant in this layer.

2.2) The dense, thick layer which is about 4,000-5,500 μm thick and lies beneath the sub-epithelium stroma. This layer is composed of mixed bundles of regularly arranged smooth muscle cells in a predominantly circular arrangement, sometimes they can also be arranged in oblique and transverse orientations. The smooth muscle bundles are surrounded by dense collagenous connective tissue that also contains fibroblasts and ground substance.

2.3) The loose connective tissue layer lies beneath the thick, dense layer, with a thickness of 2,000-2,500 μm . This third layer contains smooth muscle fibers arranged in a mainly longitudinal orientation. This layer also contains the large blood vessels supplying the cervix.

2.4) The dense, regular longitudinal muscle layer whose thickness is about 1,000-1,100 μm . This layer contains thin collagenous fibers arranged longitudinally. The 3rd and 4th layers have been described previously as two separate muscle layers; the loose connective tissue layer and the dense connective tissue layer, both containing longitudinal smooth muscle fibers (Moré, 1984). Due to the difficulty of defining the difference between these two layers, in this thesis these layers are considered as a single layer named as the longitudinal smooth muscle layer.

2.5) The outer muscle layer is 750-800 μm thick and composed of dense fibrous connective tissue and occasional smooth muscles bundles with a mixture of transverse and oblique orientations. Throughout this thesis it is named as the transverse smooth muscle layer.

2.6) Serosa: The outer surface of cervix, is covered externally by the peritoneum that limits the cervical shape. It consists of a thin layer of loose areolar connective tissue which connects the serosa to the underlying transverse smooth muscle layer. The areolar connective tissue contains collagen fibers, elastin fibers and fibroblasts covered with mesothelial cells (Moré, 1984).

The above information shows that the smooth muscle, the collagen bundles and the other components of connective tissue such as fibroblasts, proteoglycans and glycosaminoglycans are distributed throughout the cervix. The differential orientation of smooth muscle determines the state of relaxation of the cervix. For example, contraction of the circular muscle may widen the cervical lumen. Alternatively, longitudinal muscle in contraction may tighten the cervical lumen and widen the cervical lumen when it relaxes as well as transverse and oblique smooth muscle. Apart from smooth muscle,

fibroblasts, collagen bundles and connective tissue are the other common components of cervical tissue. The changing proportion of smooth muscle and collagen during the estrous cycle suggests that the collagen bundles and connective tissue are involved with cervical function (Kershaw et al., 2007) and that cyclic hormonal changes of the estrous cycle affect the arrangement of smooth muscle and collagenous connective tissue in the cervix resulting in cervical relaxation at estrus and cervical constriction in the luteal phase of the estrous cycle.

Trans-cervical artificial insemination

TCAI is a technique that semen is deposited deep in the cervix or within the uterus through the cervical canal. The greater the depth of insemination, the higher the expected pregnancy and lambing rates (Eppleston and Maxwell, 1993; Salamon and Maxwell, 1995). The anatomical complexity of the sheep cervix limits the success of TCAI. The passage of inseminating pipette can damage the cervical canal (Campbell et al., 1996) which may cause low fertility rate. When the new TCAI catheter was used in a comparison with laparoscopic AI, with F-T semen the results showed that there was no difference between fertilization rates (59.3%). This suggests that in the future TCAI may replace laparoscopic AI. The use of the exogenous cervical dilators in sheep such as oxytocin, estradiol (Khalifa et al., 1992; Stellflug et al., 2001), Follicle stimulating hormone, prostaglandin E1 (Leethongdee et al., 2007) or hyaluronan (Perry et al., 2010) have been investigated to increase cervical relaxation during the periovulatory period and then increase the success rate of TCAI.

Induction of cervical relaxation

There is a degree of cervical relaxation naturally during estrus which facilitates trans-cervical penetration in some multiparous sheep (Kershaw et al., 2005). This relaxation is most probably induced by the changing pattern of the reproductive hormones progesterone, estradiol, LH, FSH and oxytocin during the peri-ovulatory period, acting on the cervix. Increase in oxytocin receptor expression during estrus are detectable in luminal epithelial cells of the cervix (Ayad et al., 2004) and exogenous oxytocin (Khalifa et al., 1992) can dilate the cervix of the ewe. The bovine cervix, at the time of peak peri-ovulatory concentrations of FSH has high levels of cervical FSH-R and responds to FSH by increasing PGE2 synthesis (Mizrachi and Shemesh, 1999; Shemesh, 2001). The expression of FSH-R, LH-R and COX-2 is reported in non pregnant ewe during the periovulatory oestrus (Leethongdee et al., 2007). The increase in PGE2 can induce the softening and ripening of the cervix (Fuchs et al., 1984) by inducing more widely dissociated connective tissue bundles and increasing ground substance in the ECM (Topozada et al., 1987). The local intra-vaginal application of the PGE1 analogue, Misoprostol to non pregnant sheep (Leethongdee et al., 2010) reported evidence of a PGE-mediated mechanism of cervical relaxation during the periovulatory period. The cervical changes observed

following the local application of Misoprostol were increased levels of the mRNAs for LH-R, FSH-R and COX-2 and an increased concentration of HA (Leethongdee et al., 2010). These cervical changes is associated with the increased cervical relaxation (Leethongdee et al., 2007). Hyaluronan fragments can also induce prostanoid production via increased COX-2 (Kobayashi et al., 1998) which regulates the production of PGE2. Cervical dilatation requires a change in collagen within the cervical stroma (fibroblasts and smooth muscle) from the highly organized network of tightly bound collagen fibrils under the influence of high progesterone levels to a much looser arrangement at estrus (Calder, 1994) that may facilitate cervical passage of an AI pipette. The use of human IL-8 (huIL-8) to dilate the cervix of estrus sheep (Croy et al., 1999) facilitate passage of a rod into the uterus and also induced cervical neutrophils implying that neutrophils may be associated with dilatation of the cervix.

Unquestionably, PGE2 has a critical role in the mechanism cervical relaxation both at term (Calder, 1994) and thus also at estrus. Prostaglandins are produced naturally during labor and cervical ripening which is achieved by the modification of cervical collagen and change in the concentrations of cervical GAGs (Rath et al., 1993). Prostaglandin E2 has been used to soften the cervix in sheep. The infusion of PGE2 into a cervical artery increased the extensibility of a strip of ovine cervical tissue (Ledger et al., 1983). The intravaginal application of a PGE2 gel induced a four-fold increase in cervical extensibility and a two-fold reduction in stretch of the sheep cervix (Owiny and Fitzpatrick, 1990). The application of PGE2 increases the cervical softening with the absence of increases in uterine contraction (Owiny and Fitzpatrick, 1990). During the estrous cycle, the application of intra-cervical FSH or PGE2 dilated the cervix and allow trans-cervical AI in sheep (Leethongdee et al., 2007) and also increase in the concentration of HA in the cervical tissue (Leethongdee et al., 2010). The mechanism by which LH and FSH affects the regulation of PGE2 production by the cervix and thus regulates cervical dilation at estrus is not fully understood; the mechanism requires further investigation.

Conclusion

The intra-cervical application of FSH and PGE2 induced cervical relaxation in the non-pregnant ewe. Gonadotrophin treatment also increased COX-2 which is the rate limiting enzyme in the pathway for the PGE2 in the cervix. The increased HA concentration induced by PGE2 analogue led to the relaxation of the cervix. Relaxation of the cervix probably involves several mechanisms such as increased activity of collagenolytic enzymes and leukocytic infiltration associated with inflammatory reactions. These influence alternative or supplementary mechanisms also alter collagen fibers, proteoglycans and GAGs in cervical ECM. The success in the induction of cervical relaxation can enhance the success of TCAI in sheep and the results can be contributed to animals which face the same difficulty like goat.

References

- Ayad, V.J., Leung, S.T., Parkinson, T.J. and Wathes, D.C. 2004. Coincident increases in oxytocin receptor expression and EMG responsiveness to oxytocin in the ovine cervix at oestrus. *Anim Reprod Sci.* 80: 237-250.
- Calder, A.A. 1994. Prostaglandins and biological control of cervical function. *Aust New Zealand J Obstetrics & Gynaecology* 34: 347-351.
- Campbell, J.W., Harvey, T.G., McDonald, M.F. and Sparksman, R.I., 1996. Transcervical insemination in sheep: An anatomical and histological evaluation. *Theriogenology* 45: 1535-1544.
- Croy, B.A., Prudencio, J., Minhas, K., Ashkar, A.A., Galligan, C., Foster, R.A., Buckrell, B. and Coomber, B.L. 1999. A preliminary study on the usefulness of huIL-8 in cervical relaxation of the ewe for artificial insemination and for embryo transfer. *Theriogenology* 52: 271-287.
- Dobson, H. 1988. Softening and dilation of the uterine cervix. *Oxford Rev Reprod Biol.* 10: 491-514.
- Eppleston, J. and Maxwell, W.M.C. 1993. Recent attempts to improve fertility of frozen ram semen inseminated into the cervix. *Wool Technol Sheep Breed* 41: 291-302.
- Fuchs, A.R., Goeschen, K., Rasmussen, A.B. and Rehnstrom, J.V. 1984. Cervical ripening and plasma prostaglandin levels. Comparison of endocervical and extra-amniotic PGE₂. *Prostaglandins.* 28: 217-227.
- Halbert, G.W., Dobson, H., Walton, J.S. and Buckrell, B.C. 1990. The structure of the cervical canal of the ewe. *Theriogenology* 33: 977-992.
- Kaabi, M., Alvarez, M., Anel, E., Chamorro, C.A., Boixo, J.C., de Paz, P. and Anel, L. 2006. Influence of breed and age on morphometry and depth of inseminating catheter penetration in the ewe cervix: A postmortem study. *Theriogenology* 66: 1876-1883.
- Kershaw, C.M., Khalid, M., McGowan, M.R., Ingram, K., Leethongdee, S., Wax, G. and Scaramuzzi, R.J. 2005. The anatomy of the sheep cervix and its influence on the transcervical passage of an inseminating pipette into the uterine lumen. *Theriogenology* 64: 1225-1235.
- Kershaw, C.M., Scaramuzzi, R.J., McGowan, M.R., Wheeler-Jones, C.P. and Khalid, M. 2007. The expression of prostaglandin endoperoxide synthase 2 messenger RNA and the proportion of smooth muscle and collagen in the sheep cervix during the estrous cycle. *Biol Reprod.* 76: 124-129.
- Khalifa, R.M., Sayre, B.L. and Lewis, G.S. 1992. Exogenous oxytocin dilates the cervix in ewes. *J Anim Sci.* 70: 38-42.
- Kobayashi, H., Sun, G.W. and Terao, T. 1998. Production of prostanoids via increased cyclooxygenase-2 expression in human amnion cells in response to low molecular weight hyaluronic acid fragment. *Biochim Biophys Acta.* 1425: 369-376.
- Ledger, W.L., Ellwood, D.A. and Taylor, M.J. 1983. Cervical softening in late pregnant sheep by infusion of prostaglandin E-2 into a cervical artery. *J Reprod Fertil.* 69: 511-515.
- Leethongdee, S. 2010. Development of trans-cervical artificial insemination in sheep with special reference to anatomy of cervix. *Suranaree J Sci Technol* 17: 57-69.
- Leethongdee, S., Kershaw-Young, C.M., Scaramuzzi, R.J. and Khalid, M. 2010. Intra-cervical application of Misoprostol at estrus alters the content of cervical hyaluronan and the mRNA expression of follicle stimulating hormone receptor (FSHR), luteinizing hormone receptor (LHR) and cyclooxygenase-2 in the ewe. *Theriogenology* 73: 1257-1266.
- Leethongdee, S., Khalid, M., Bhatti, A., Ponglowhapan, S., Kershaw, C.M. and Scaramuzzi, R.J. 2007. The effects of the prostaglandin E analogue Misoprostol and follicle-stimulating hormone on cervical penetrability in ewes during the peri-ovulatory period. *Theriogenology* 67: 767-777.
- Mizrachi, D. and Shemesh, M. 1999. Follicle-stimulating hormone receptor and its messenger ribonucleic acid are present in the bovine cervix and can regulate cervical prostanoid synthesis. *Biol Reprod.* 61: 776-784.
- More, 1984. Anatomy and histology of the cervix uteri of the ewe: New insights. *Acta Anatomica* 120: 156-159.
- Naqvi, S.M., Pandey, G.K., Gautam, K.K., Joshi, A., Geethalakshmi, V. and Mittal, J.P. 2005. Evaluation of gross anatomical features of cervix of tropical sheep using cervical silicone moulds. *Anim Reprod Sci.* 85: 337-344.
- Owiny, J.R. and Fitzpatrick, R.J. 1990. Effect of intravaginal application of prostaglandin E₂ gel on the mechanical properties of the ovine cervix uteri at term. *Am J Obstet Gynecol.* 163: 657-660.
- Perry, K., Haresign, W., Wathes, D.C. and Khalid, M. 2010. Intracervical application of hyaluronan improves cervical relaxation in the ewe. *Theriogenology* 74: 1685-1690.
- Rath, W., Osmers, R., Adelman-Grill, B.C., Stuhlsatz, H.W., Szevereny, M. and Kuhn, W. 1993. Biochemical changes in human cervical connective tissue after intracervical application of prostaglandin E₂. *Prostaglandins* 45: 375-384.
- Salamon, S. and Maxwell, W.M.C. 1995. Frozen storage of ram semen II. causes of low fertility after cervical insemination and methods of improvement. *Anim Reprod Sci.* 38: 1-36.
- Shemesh, M. 2001. Actions of gonadotrophins on the uterus. *Reproduction* 121: 835-842.
- Stellflug, J.N., Wulster-Radcliffe, M.C., Hensley, E.L., Cowardin, E.A., Seals, R.C. and Lewis, G.S. 2001. Oxytocin-induced cervical dilation and cervical manipulation in sheep: effects on laparoscopic artificial insemination. *J Anim Sci.* 79: 568-573.
- Topozada, M., el-Ghazzawi, E., Gaweesh, S., el-Abd and M., Samaha, A. 1987. Effect of prostaglandins E₂ and 15-methyl F₂ alpha on human pregnant and non-pregnant cervix. *Eur J Obstet Gynecol Reprod Biol.* 26: 27-32.
- William, P.W. 1979. Cyclic changes in the surface structure of the cervix from the ewe as revealed by scanning electron microscopy. *Tissue Cell* 11: 359-370.

