

7-1-2011

WHAT IS YOUR DIAGNOSIS

Pranee Tuntivanich

Suwicha Chuthatep

Follow this and additional works at: <https://digital.car.chula.ac.th/tjvm>



Part of the [Veterinary Medicine Commons](#)

Recommended Citation

Tuntivanich, Pranee and Chuthatep, Suwicha (2011) "WHAT IS YOUR DIAGNOSIS," *The Thai Journal of Veterinary Medicine*: Vol. 41: Iss. 2, Article 20.

Available at: <https://digital.car.chula.ac.th/tjvm/vol41/iss2/20>

This Other is brought to you for free and open access by the Chulalongkorn Journal Online (CUJO) at Chula Digital Collections. It has been accepted for inclusion in The Thai Journal of Veterinary Medicine by an authorized editor of Chula Digital Collections. For more information, please contact ChulaDC@car.chula.ac.th.

WHAT IS YOUR DIAGNOSIS

Pranee Tuntivanich Suwicha Chuthatep

Signalment

A 12-year-old female spayed Miniature Pincher dog

History

The dog had been presented with gradual enlargement of abdominal cavity during the past 2 months. Previous ultrasonographic result indicated a large soft tissue mass in the splenic body. She showed a progressive respiratory distress with open mouth breathing. She could not lie down on her side position.

Clinical Examination

A large soft tissue mass could be localized via abdominal palpation. Anemia and thrombocytopenia were detected from blood profile. Cyanosis could easily be observed from color of tongue and oral mucosa.

Radiographic Examination

Plain right lateral and ventrodorsal views of the thoracic and abdominal radiographs were taken to evaluate respiratory disturbance and abdominal abnormality.

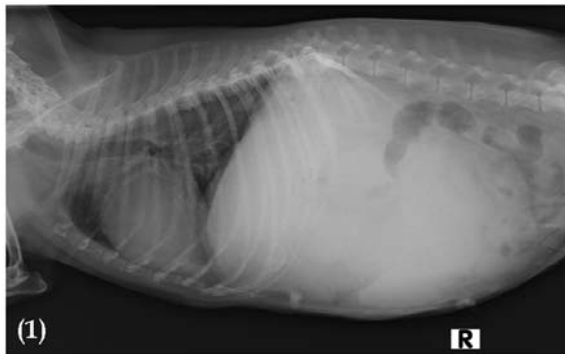


Figure 1 Right lateral radiograph

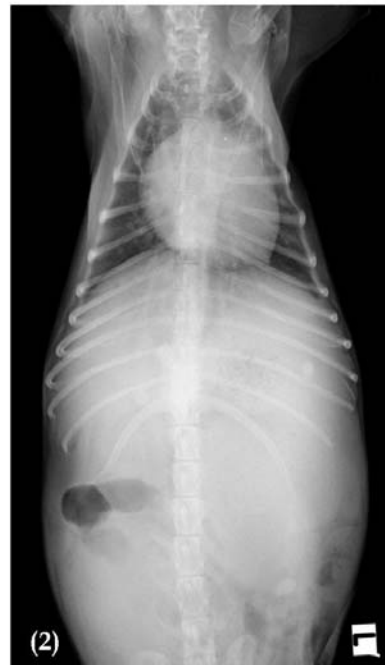

Figure 2 Ventrodorsal radiograph

Give your diagnosis and turn to the next page.

Radiographic findings

The right lateral radiograph (Fig 1) revealed an increase of the tracheal and bronchial wall radiopacity. Also, there was mild irregular tracheal alignment. Generalized mild interstitial infiltration of lung field could be noted. The vertebral heart size was within normal limits but there was an abnormal cardiac shape. The caudodorsal border of the heart was higher than usual with bulging appearance (Fig 3). Moreover, a large space-occupying soft tissue mass was detected in abdomen which results in cranial displacement of diaphragmatic crura and caudodorsal displacement of the small bowel loops. Ventral spondylosis of T6-T7 and T11-T13 were present associated with narrowing intervertebral disc spaces. A mild diverged bronchial bifurcation of both caudal bronchi was observed in ventrodorsal radiograph (Fig 2). Right-caudal displacement of small bowel loops could also be detected.

Radiographic diagnosis

Bronchiectasis, Tracheal and bronchial mineralization, Left atrial enlargement

Space-occupying soft tissue mass in abdomen

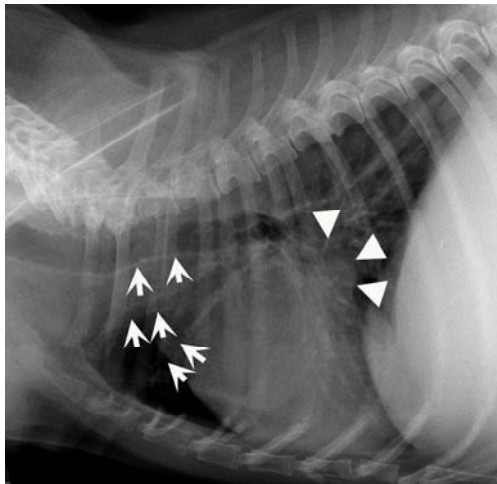


Figure 3 Close-up radiograph of the right lateral thorax that reveals mild thickening and dilation of the tracheal and bronchial walls (white arrows). There are an increase in height of the caudodorsal border of the heart and slight concavity at the location where the left atrium meets the left ventricle (white arrow heads), which indicates the left atrial enlargement.

References

Lamb, C.R. 2002. The canine and feline lung. In: Textbook of Veterinary Diagnostic Radiology. 4th ed. D.E. Thrall (ed.). Pennsylvania: W.B. Saunders Company: 431-449.

Discussion

Calcification of the bronchial cartilage (bronchial mineralization) without thickening of the wall can usually be found in middle-aged and old dogs. In case of bronchial diseases, thickening of bronchial wall and increasing of bronchial lumen diameter can indicate bronchiectasis. Radiograph can be used to investigate the thickening of the side on and the end on of the affected bronchi, severe or advanced stage of bronchial dilation. In case of early stage of bronchiectasis, the use of computed tomography or bronchography will be more effective.

Lateral radiograph can be used to investigate the left atrial enlargement; an increase in height of the caudodorsal border of the heart, dorsal deviation of the left main stem bronchus, a slight concavity of the location where the left atrium meets the left ventricle (Fig.3).