

The Thai Journal of Veterinary Medicine

Volume 41
Issue 2 July, 2011

Article 18

7-1-2011

Ophthalmology Snapshot

Nalinee Tuntivanich

Follow this and additional works at: <https://digital.car.chula.ac.th/tjvm>



Part of the [Veterinary Medicine Commons](#)

Recommended Citation

Tuntivanich, Nalinee (2011) "Ophthalmology Snapshot," *The Thai Journal of Veterinary Medicine*: Vol. 41: Iss. 2, Article 18.

Available at: <https://digital.car.chula.ac.th/tjvm/vol41/iss2/18>

This Other is brought to you for free and open access by the Chulalongkorn Journal Online (CUJO) at Chula Digital Collections. It has been accepted for inclusion in The Thai Journal of Veterinary Medicine by an authorized editor of Chula Digital Collections. For more information, please contact ChulaDC@car.chula.ac.th.

Ophthalmology Snapshot

Nalinee Tuntivanich

History

A 1 year-old male Beagle had red eye. He had been prescribed with topical dexamethasone eye drop twice daily together with systemic anti-inflammatory drug for 2 weeks. The owner shortly brought him to the Ophthalmology Clinic, Small Animal Teaching Hospital, Veterinary Science, Chulalongkorn University because there was no improvement regarding to his previous treatment.

Ophthalmic examinations revealed 17 and 18 mm wetness of the STT I on the right and left eye, respectively. Hypertrophy of the gland of the third eyelid was observed on the right eye while protrusion of the third eyelid was observed in the contra lateral eye. Both third eyelids were examined. Further investigation of the third eyelid was performed under general anesthesia on the day of treatment (Fig 1).

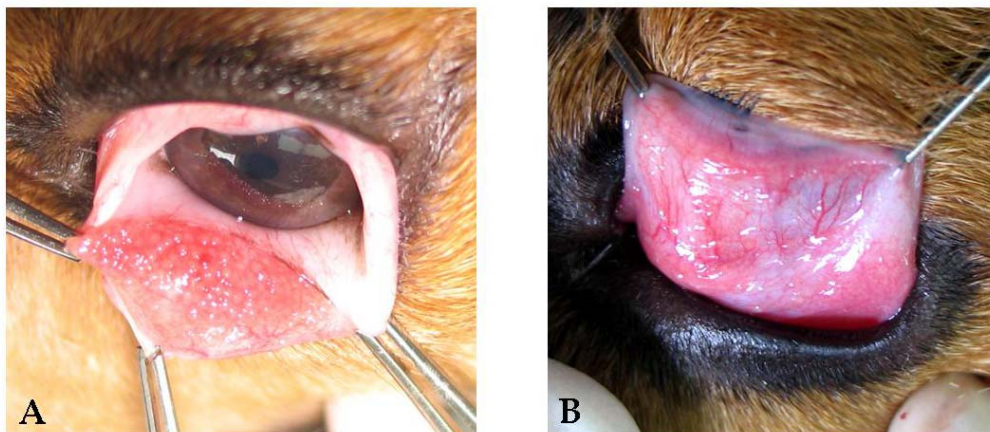


Figure 1 Bulbar conjunctiva; inner part (1A) and palpebral conjunctiva; outer part (1B) of the nictitating membrane of the left eye at time before treatment.

(For better quality, figures can be viewed in the TJVM website)

Question

Give the diagnosis of the left eye.

Please turn to the next page for answers

*Answer***Diagnosis:**

Follicular conjunctivitis

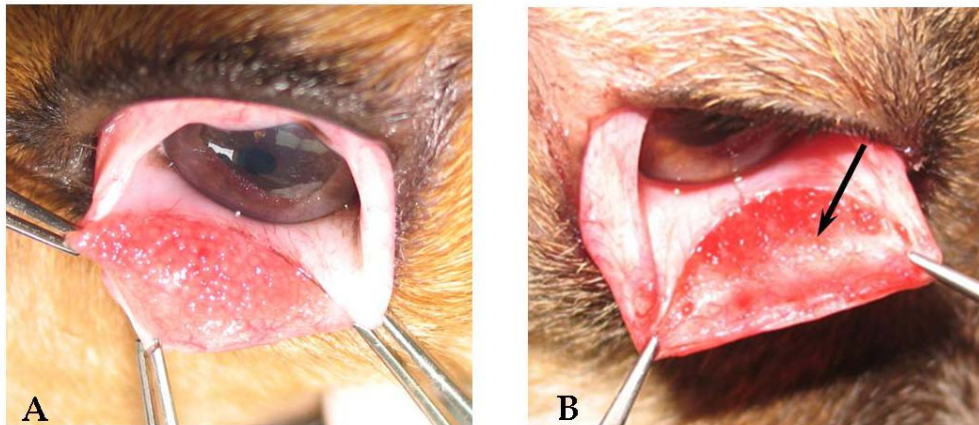


Figure 2 Follicular conjunctivitis on the bulbar surface of the left third eyelid before treatment (2A) and after partial debridement (arrow) (2B).

Comments

Nictitating membrane (nictitan or third eyelid) is a membranous organ located nasally behind the lower eyelid in dogs. It is a fold of conjunctiva that contains cartilage, gland and lymphoid follicles. When abnormal, it is necessary to examine outer (palpebral) and inner (bulbar) part of it. Chronic irritation/inflammation can initiate proliferation of the follicles, called follicular conjunctivitis, a reaction of lymphoid hyperplasia. When present, follicles can be found on both surfaces of conjunctiva but mostly the bulbar aspect (Fig 2A). Other symptoms include conjunctival hyperemia, swelling of the third eyelid, tearing, blinking and squinting of the eye. Infection does not usually involve. However, secondary bacterial infection may occur in some cases.

Treatment should be considered instantaneously after diagnosis. Administration of topical corticosteroid with/without antibiotic can be considered to reduce inflammation of the conjunctiva and further infection. Eye cleansing is very helpful to minimize mucous ocular discharge. In case of severe or medical nonresponsive, follicles should be mechanically debrided (Fig 2B) with blunt applicator. Owner should be educated with the cause of the disease as well as its prevention to avoid recurrence.

Reference

Hendrix, D.V.H. 2007. Canine conjunctiva and nictitating membrane. In: Veterinary Ophthalmology. 4th ed. K.N. Gelatt (ed). Ames: Blackwell Publishing: 165.