

7-1-2011

Aquapuncture using Vitamin B Complex on Intraocular Pressure in Two Dogs with Cataracts and Low Intraocular Pressure

Wei-Yau Shia

Yun-Hsia Hsiao

Ming-Wei Lee

Li-Shiue Shiu

Shiun-Long Lin

See next page for additional authors

Follow this and additional works at: <https://digital.car.chula.ac.th/tjvm>



Part of the [Veterinary Medicine Commons](#)

Recommended Citation

Shia, Wei-Yau; Hsiao, Yun-Hsia; Lee, Ming-Wei; Shiu, Li-Shiue; Lin, Shiun-Long; and Lee, Wei-Ming (2011) "Aquapuncture using Vitamin B Complex on Intraocular Pressure in Two Dogs with Cataracts and Low Intraocular Pressure," *The Thai Journal of Veterinary Medicine*: Vol. 41: Iss. 2, Article 14.
Available at: <https://digital.car.chula.ac.th/tjvm/vol41/iss2/14>

This Short Communication is brought to you for free and open access by the Chulalongkorn Journal Online (CUJO) at Chula Digital Collections. It has been accepted for inclusion in The Thai Journal of Veterinary Medicine by an authorized editor of Chula Digital Collections. For more information, please contact ChulaDC@car.chula.ac.th.

Aquapuncture using Vitamin B Complex on Intraocular Pressure in Two Dogs with Cataracts and Low Intraocular Pressure

Authors

Wei-Yau Shia, Yun-Hsia Hsiao, Ming-Wei Lee, Li-Shiue Shiu, Shiun-Long Lin, and Wei-Ming Lee

Aquapuncture using Vitamin B Complex on Intraocular Pressure in Two Dogs with Cataracts and Low Intraocular Pressure

**Wei-Yau Shia¹ Yun-Hsia Hsiao¹ Ming-Wei Lee¹ Li-Shiue Shiu¹
Shiun-Long Lin^{1,2} Wei-Ming Lee^{1,2*}**

Abstract

Two mixed breed dogs, aged 13 years old and 12 years old, with low intraocular pressure are described. These dogs presented with low intraocular pressure (IOP) and cataract. Cataracts were treated for one year by VT Phak®. For the IOP, it was 6 mmHg in both eyes of dog A and 8 mmHg in both eyes of dog B. According to our evaluation and based on owner's consent, the dogs should be treated with aquapuncture using vitamin B complex every two weeks. Thereafter, the intraocular pressure of these two dogs was evaluated every two months. The local acupoints were BL-1 (Jing Ming), BL-2 (Cuan Zhu), TH-23 (Si Zhu-kong), ST-1 (Cheng Qi), ST-2 (Si Bai), BL-18 (Gan Shu) and LIV-3 (Tai Chong). After 10 months of treatment, the IOP of the left and right eye in dog A were 14 mmHg and 11 mmHg, respectively and those in dog B were 20 mmHg and 23 mmHg, respectively. Thus, it is suggested that aquapuncture using vitamin B complex might be an alternative therapy to improve the intraocular pressure in dogs with low intraocular pressure.

Keywords: aquapuncture, dog, intraocular pressure, vitamin B complex

¹ Department of Veterinary Medicine, College of Veterinary Medicine, National Chung-Hsing University, 250, Kuo Kuang Rd., 402 Taichung, Taiwan

² Veterinary Medical Teaching Hospital, National Chung-Hsing University, 250-1, Kuo Kuang Rd., 402 Taichung, Taiwan

*Corresponding author E-mail: wmllee@dragon.nchu.edu.tw

บทคัดย่อ

การฝังเข็มร่วมกับการให้ไวดะมินปี 12 ต่อความดันในลูกตาในสุนัขที่มีภาวะต้อกระจก

Wei-Yau Shia¹ Yun-Hsia Hsiao¹ Ming-Wei Lee¹ Li-Shiue Shiu¹ Shiun-Long Lin^{1,2} Wei-Ming Lee^{1,2*}

ทำการศึกษาในสุนัขพันธุ์ผสม อายุ 12 และ 13 ปี ที่มีภาวะความดันในลูกตาดำ และร่วมกับภาวะต้อกระจก และความดันในลูกตาดำ ภาวะต้อกระจกได้รับการรักษาด้วย VT Phak® เป็นระยะเวลา 1 ปี ค่าความดันในลูกตา (IOP) ของสุนัขหมายเลข A มีค่า 6 มิลลิเมตรปรอท และสุนัขหมายเลข B มีค่า 8 มิลลิเมตรปรอท สุนัขได้รับการรักษาโดยการฝังเข็มร่วมกับการให้ไวดะมินปี 12 ต่อเนื่องทุก 2 สัปดาห์ และทำการวัดค่าความดันในลูกตา ทุก 2 เดือน ตำแหน่งของการฝังเข็มประกอบด้วย BL-1 (Jing Ming), BL-2 (Cuan Zhu), TH-23 (Si Zhu-kong), ST-1 (Cheng Qi), ST-2 (Si Bai), BL-18 (Gan Shu) และ LIV-3 (Tai Chong) ผลการศึกษาในระยะเวลา 10 เดือน พบว่าสุนัขหมายเลข A มีค่า IOP 14 มิลลิเมตรปรอทในตาข้างซ้าย และ 12 มิลลิเมตรปรอทในตาข้างขวา สุนัขหมายเลข B มีค่า IOP 20 มิลลิเมตรปรอทในตาข้างซ้าย และ 23 มิลลิเมตรปรอทในตาข้างขวา จากผลการศึกษา อาจกล่าวได้ว่า การฝังเข็มร่วมกับการให้ไวดะมินปี 12 นำมาใช้เป็นการรักษาแนวทางเลือกที่ช่วยเพิ่มความดันในลูกตาในสุนัข

คำสำคัญ: การฝังเข็ม สุนัข ความดันในลูกตา ไวดะมินปี 12

¹ Department of Veterinary Medicine, College of Veterinary Medicine, National Chung-Hsing University, 250, Kuo Kuang Rd., 402 Taichung, Taiwan

² Veterinary Medical Teaching Hospital, National Chung-Hsing University, 250-1, Kuo Kuang Rd., 402 Taichung, Taiwan

*ผู้รับผิดชอบบทความ E-mail: wmllee@dragon.nchu.edu.tw

Case history

Two dogs (dog A, 13 years old, 13 kg/body weight, castrated; dog B, 12 years old, 12.6 kg/body weight, neutered) with cataracts and low intraocular pressure were presented. The chief complaint of these dogs was ocular problem according to Veterinary Teaching Hospital, National Chung Hsing University, Taichung, Taiwan.

Clinical examination: Besides cataracts, these dogs presented normal condition after physical examination. Normal results were shown after complete slit-lamp biomicroscopy (Kowa SL-14, Kowa Company, Tokyo, Japan) and indirect ophthalmoscopy (Keeler®, Keeler instruments, Inc. USA). However, low intraocular pressure (IOP) of these two dogs was noted after tonometry (Tonopen XL®, comp, country).

Method of treatment: Both dogs received the treatment for cataracts by VT Phak® (Generic name, Virbac, France) topically for one year, but the effect was limited. After evaluation and owner's consent, aquapuncture was applied on these dogs. We stimulated acupoints BL-1 (Jing Ming, located at the 0.1 cun dorso-medial canthus of the eye), BL-2 (Cuan Zhu, located at the supraorbital notch directly dorsal BL-1), TH-23 (Si Zhu-kong, in the depression on the rim of the orbital at the end of the eyebrow extended

to the lateral canthus), ST-1 (Cheng Qi, directly ventral to the center of the pupil just inside the infra-orbital ridge), ST-2 (Si Bai, rostral to the eye in the depression at the center of the infra-orbital foramen), BL-18 (Gan Shu, on the dorsolateral aspect of the spine, 1.5 cm the caudo-lateral border of the dorsal spinous process of T10) and LIV-3 (Tai Chong, on the medial side of the pelvic limb, proximal metatarsophalangeal joint between the second and third metatarsal bones) by 1 ml syringe containing vitamin B complex (Tai Yu®, Taiwan, 0.1 ml/point) every two weeks in both dogs. The value of IOP of these two dogs was measured every two months for 10 months.

Results and Discussion

Table 1 Comparison between the improvement of IOP before and after 10 months of aquapuncture treatment in dog A and dog B.

month(s)	Dog A		Dog B	
	OD	OS	OD	OS
0	6	6	8	8
1	6	6	8	8
3	8	8	10	10
5	8	9	10	10
7	12	10	13	14
10	11	14	23	20

0, before treatment; 1, one month after treatment; 3, three months after treatment; 5, five months after treatment; 7, seven months after treatment; 10, ten months after treatment.

OD, the IOP value measured on right eye; OS, the IOP value measured on left eye.




Figure 1 Facial view of dog A and acupoints, BL-1, BL-2, TH-23, ST-1 and ST-2, used for the treatment of low intraocular pressure.

The IOP of both eyes of dog A was 6 mmHg and of dog B was 8 mmHg (Table 1). Low intraocular pressure presented in these two cases. Tonopen XL® is a standardized tonometry method for routine clinical use for canine eyes (Leiva et al. 2006), but diverse results of IOP may be measured by different veterinarians (Lin et al., 2009). In order to prevent artificial errors, only one veterinarian did the tonometer examination for these two dogs. Normal results were shown in this study after complete slit-lamp biomicroscopy and indirect ophthalmoscopy examination, but low intraocular pressure was found. The real cause of low intraocular pressure of these two dogs was unknown. The level of intraocular pressure in dog A reached the level of hypotony, but that in dog B did not. It has been reported that hypotony may mostly be caused by excess filtration after glaucoma filtering surgery (Maruyama and Shirato, 2008). However, there are many methods that have been issued to improve the phenomena of hypotony such as intrableb injection of autologous blood (Leen et al. 1995; Tittler et al. 2008), compressing suture (Haynes and Alward, 1999), bleb excision (Myers et al., 2000), free conjunctival autograft (Buxton et al. 1994), and transconjunctival scleral flap resuturing (Maruyama and Shirato, 2008). The owner did not prefer these two dogs for cataract surgery. Therefore, aquapuncture was suggested for these dogs after evaluation and owner's consent. The application of acupuncture has been reported in human ophthalmology, especially for the treatment of glaucoma (Dabov et al. 1985; Kurusu et al. 2005; Law

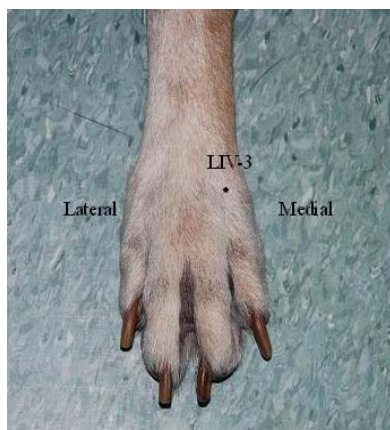


Figure 3 Acupoint of LIV-3.

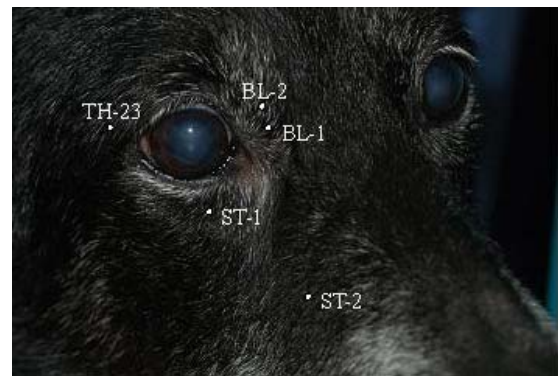


Figure 2 Facial view of dog B and acupoints, BL-1, BL-2, TH-23, ST-1 and ST-2, used for the treatment of low intraocular pressure.

and Li, 2007; Xu et al. 2008). In addition, acupuncture has been used on a dog with Hornor's syndrome (Chou and Kim, 2008). In this study, we stimulated acupoints BL-1, BL-2, TH-23, ST-1 and ST-2 by 1 ml syringe containing vitamin B complex (Tai Yu®, Taiwan, 0.1 ml/point) in dog A (Fig 1) and dog B (Fig 2), as well as acupoint LIV-3 (Fig 3) and BL-18 (Fig 4). After 10 months of treatment, the IOP of the left and right eye in dog A were 14 mmHg and 11 mmHg, respectively and those in dog B were 20 mmHg and 23 mmHg, respectively (Table 1). The improvement of intraocular pressure of these dogs was found by the treatment of aquapuncture using vitamin B complex.

The attributes and indication of acupuncture, for example conjunctivitis (BL-1, BL-2, ST-1, ST-2), uveitis (BL-1, BL-2, ST-1, ST-2), visual disturbance (BL-2), ocular diseases (TH-23, BL-18), ocular discharge or swelling (ST-1) and abnormal tear production (ST-1) (Xie and Vanessa, 2007) can benefit from acupuncture used in this study. In addition, the effect of LIV-3 on the ocular disorder is indirectly. LIV-3 is benefit on the liver Qi stagnation that can be associated with ocular disorder (Xie and Vanessa, 2007). Additionally, the improvement of IOP in dog B may be resulted by some ingredients of vitamin B complex used in this study. Each ml of vitamin B complex consists of thiamine HCl 100 mg, riboflavin 5 mg, pyridoxine HCl 2 mg, niacinamide 50 mg and

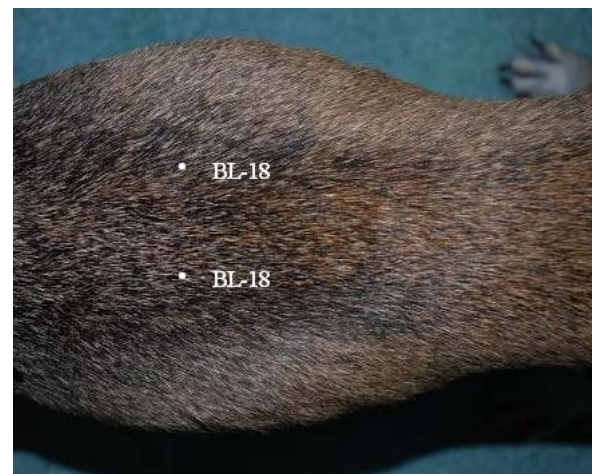

Figure 4 Acupoint of BL-18.

dexpantenol 5 mg. The elevation of IOP benefit from riboflavin (Kymionis et al., 2010) and niacinamide (Wise, 1993).

In conclusion, aquapuncture using vitamin B complex is useful for the improvement of intraocular pressure and may be an alternative medical treatment in veterinary medicine.

Acknowledgements

The authors would like to thank Dr. Shu-Hao Chang, who helped us with IOP measurement by Tonopen XL® tonometer and English critical reading by Dr. Amelia M. M. Jack.

References

- Buxton, J.N., Lavery, K.T., Lieberman, J.M., Buxton, D.F. and Ritch, R. 1994. Reconstruction of filtering blebs with free conjunctival autograft. *Ophthalmology*. 101: 635-639.
- Chou, S.J. and Kim, O. 2008. Acupuncture treatment for idiopathic Horner's syndrome in a dog. *J. Vet. Sci.* 9: 117-119.
- Dabov, S., Goutoranov, G., Ivanova, R. and Petkova, N. 1985. Clinical application of acupuncture in ophthalmology. *Acupunct Electrother Res.* 10: 79-93.
- Haynes, W.L. and Alward, W.L.M. 1999. Combination of autologous blood injection and bleb compression sutures to treat hypotony maculopathy. *J Glaucoma*. 8: 384-387.
- Kurusu, M., Watanabe, K., Nakazawa, T., Seki, T., Arai, H., Sasaki, H., Fuse, N. and Tamai, M. 2005. Acupuncture for patients with glaucoma. *Explore (NY)*. 1: 372-376.
- Kymionis, G.D., Grentzelos, M.A., Kounis, G.A., Portaliou, D.M., Detorakis, E.T., Magarakis, M., Karampatakis, V.E. and Pallikaris, I.G. 2010. Intraocular pressure measurements after corneal collagen crosslinking with riboflavin and ultraviolet A in eyes with keratoconus. *J Cataract Refract Surg.* 36: 1724-1727.
- Law, S.K. and Li, T. 2007. Acupuncture for glaucoma. *Cochrane Database Syst Rev.* 17: CD006030.
- Leen, M.M., Moster, M.R., Katz, L.J., Terebuh, A.K., Schmidt, C.M. and Spaeth, G.L. 1995. Management of overfiltering and leaking blebs with autologous blood injection. *Arch Ophthalmol.* 113: 1050-1055.
- Leiva, M., Naranjo, C. and Pena, M.T. 2006. Comparison of the rebound tonometer (ICare®) to the applanation tonometer (Tonopen XL®) in normotensive dogs. *Vet Ophthalmol.* 9: 17-21.
- Lin, S.L., Cheng, F.P., Lin, Y.C. and Wang, W.S. 2009. The Tonopen XL® tonometer and observers. *Taiwan Vet J.* 35: 15-20.
- Maruyama, K. and Shirato, S. 2008. Efficacy and safety of transconjunctival scleral flap resuturing for hypotony after glaucoma filtering surgery. *Graefes Arch Clin Exp Ophthalmol.* 246: 1751-1756.
- Myers, J.S., Yang, C.B., Herndon, L.W., Allingham, R.R. and Shields, M.B. 2000. Excisional bleb revision to correct overfiltration or leak. *J Glaucoma.* 9: 169-173.
- Tittler, E.H., de Barros, D.S., Navarro, J.B., Freitas, D.G., Gheith, M.E., Siam, G.A. and Spaeth, G.L. 2008. Oral niacin can increase intraocular pressure. *Ophthalmic Surg Lasers Imaging.* 39: 341-342.
- Wise, J.B. 1993. Treatment of chronic postfiltration hypotony by intrableb injection of autologous blood. *Arch ophthalmol.* 111: 827-830.
- Xie, H. and Vanessa, P. 2007. *Xie's Veterinary Acupuncture*. Oxford: Blackwell: 129-215.
- Xu, H., Liu, J., Xu, S.W., Zong, L. and Zhang, R. 2008. Analysis on literature of acupuncture and moxibustion treatment of intractable eye diseases. *Zhongguo Zhen Jiu.* 28: 625-628.