

3-1-2011

## WHAT IS YOUR DIAGNOSIS

Pranee Tuntivanich

Suwicha Chuthatep

Follow this and additional works at: <https://digital.car.chula.ac.th/tjvm>



Part of the [Veterinary Medicine Commons](#)

---

### Recommended Citation

Tuntivanich, Pranee and Chuthatep, Suwicha (2011) "WHAT IS YOUR DIAGNOSIS," *The Thai Journal of Veterinary Medicine*: Vol. 41: Iss. 1, Article 7.

Available at: <https://digital.car.chula.ac.th/tjvm/vol41/iss1/7>

This Other is brought to you for free and open access by the Chulalongkorn Journal Online (CUJO) at Chula Digital Collections. It has been accepted for inclusion in The Thai Journal of Veterinary Medicine by an authorized editor of Chula Digital Collections. For more information, please contact [ChulaDC@car.chula.ac.th](mailto:ChulaDC@car.chula.ac.th).

## WHAT IS YOUR DIAGNOSIS

Pranee Tuntivanich Suwicha Chuthatep

### *Signalment*

An 11-year-old female spayed mixed breed dog

### *History*

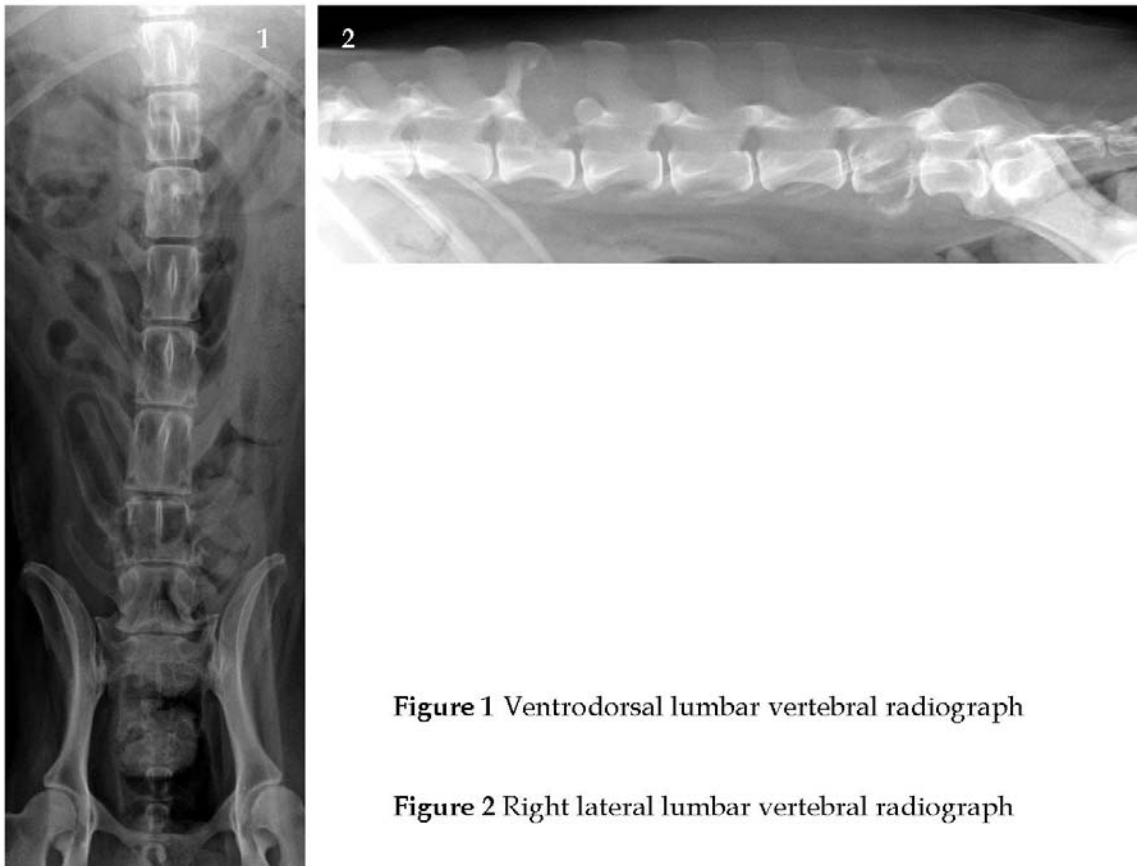
There was a small mass (approximately 4 cm length) above the cranial lumbar area. This dog had presented with both hind limb paralysis during the past 3 weeks without traumatic history. She could not control both urination and defecation. It was painful when touching on her back.

### *Clinical Examination*

She lost all her spinal reflexes in both hind limbs. Thrombocytopenia and increasing of the serum alkaline phosphates were detected from blood examination. Negative result from bacterial culture examination was shown in sample from lumbar mass aspiration.

### *Radiographic Examination*

Plain ventrodorsal and right lateral radiographs of the lumbar vertebral column were taken to evaluate the vertebral alignment and other spinal bone abnormalities.



**Figure 1** Ventrodorsal lumbar vertebral radiograph

**Figure 2** Right lateral lumbar vertebral radiograph

Give your diagnosis and turn to the next page.

### **Radiographic findings**

Ventrodorsal and right lateral vertebral radiographs (Fig. 1, 2) revealed an increase of radiolucency of the 6<sup>th</sup> lumbar vertebrae. The lumbar vertebrae were in normal alignment. On lateral radiograph (Fig. 2), an obvious pathological fracture of the 6<sup>th</sup> lumbar vertebrae was detected as a decrease of the vertebral body length, partial loss of vertebral lamina and severe bone destruction. Similarity in the 2<sup>nd</sup> lumbar vertebrae also presented severe bone destruction of the spinous process and caudal articular facet (Fig. 3). Moreover, the osteophyte formation can be seen between the ventral portion of the 7<sup>th</sup> lumbar vertebrae and sacral spine.

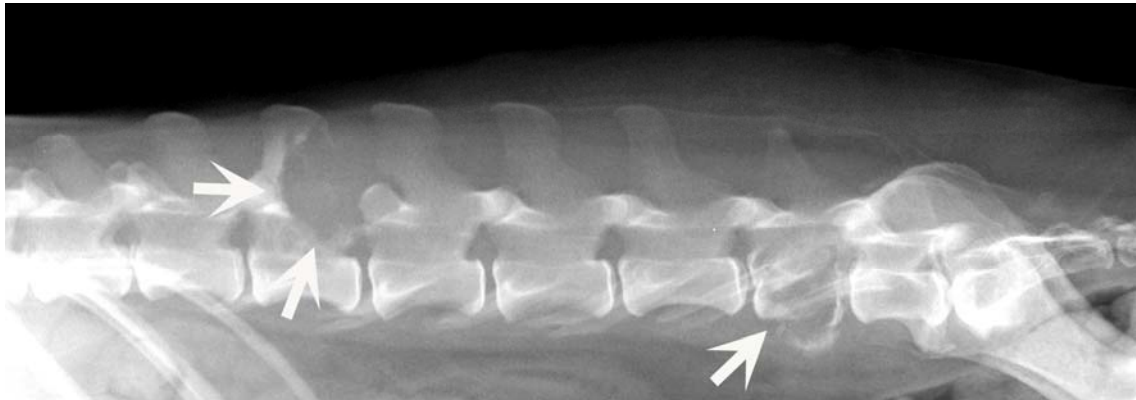
### **Radiographic diagnosis**

Spinal tumor

### **Discussion**

Spinal tumor can occur in various locations of the spine including spinal body, spinal canal, dural sac and spinal cord. The tumor can primarily be originated from the spine or be metastatic in the same frequency. Spinal tumor usually causes spinal bone destruction, ruptured intervertebral disks, spinal canal and spinal cord compression which typically produce progressive pain and disability. The thoracic and lumbar spines are the most frequent sites for spinal tumors. Primary and secondary spinal tumors often extend into adjacent vertebrae which are different from long bone tumors that do not normally cross joint spaces. Additionally, there is no relation between the degree of spinal bone destruction from radiograph and the degree of neurologic deficit in animal.

Myelography may be used to indicate a location of the definite lesion of the spine but the cell type cannot be identified. In cases of unclear spinal tumors, computed tomographic examination can be performed to investigate small areas of bone destruction or bone deposition.



**Figure 3** Severe bone destruction in spinal column (white arrows)

### **References**

Farrow, C.S. 2003. Spinal tumors (vertebral tumors) and tumor-like lesions. In: *Veterinary Diagnosis Imaging the Dog and Cat*. St. Louis, Missouri: Mosby. 310-318.