

# The Thai Journal of Veterinary Medicine

---

Volume 40  
Issue 4 December, 2010

Article 15

---

12-1-2010

## Ophthalmology Snapshot

Nalinee Tuntivanich

Follow this and additional works at: <https://digital.car.chula.ac.th/tjvm>



Part of the [Veterinary Medicine Commons](#)

---

### Recommended Citation

Tuntivanich, Nalinee (2010) "Ophthalmology Snapshot," *The Thai Journal of Veterinary Medicine*: Vol. 40: Iss. 4, Article 15.

Available at: <https://digital.car.chula.ac.th/tjvm/vol40/iss4/15>

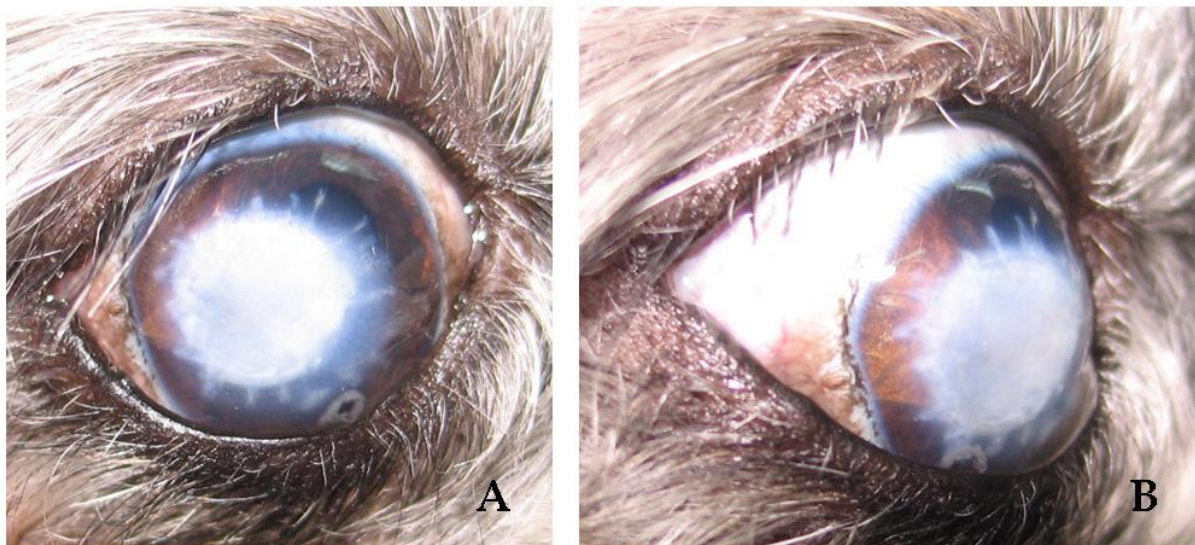
This Other is brought to you for free and open access by the Chulalongkorn Journal Online (CUJO) at Chula Digital Collections. It has been accepted for inclusion in The Thai Journal of Veterinary Medicine by an authorized editor of Chula Digital Collections. For more information, please contact [ChulaDC@car.chula.ac.th](mailto:ChulaDC@car.chula.ac.th).

## Ophthalmology Snapshot

Nalinee Tuntivanich

### *History*

A 10 year-old female Shih Tzu had an anterior staphyloma on the right eye a month ago. The lesion, which was approximately 8 mm in diameter on the center of the cornea, was surgically treated by iridectomy and corneal grafting. Topical antibiotics, cycloplegics and artificial tears were postoperatively prescribed. At 3 weeks after surgery, topical antibiotic was replaced with a combination of antibiotic and corticosteroid. The dog's vision has been positive from start to finish.



**Figure 1** Photographs of the right eye of the Shih Tzu in the (a) front view and (b) oblique view demonstrating cornea lesion following surgery.

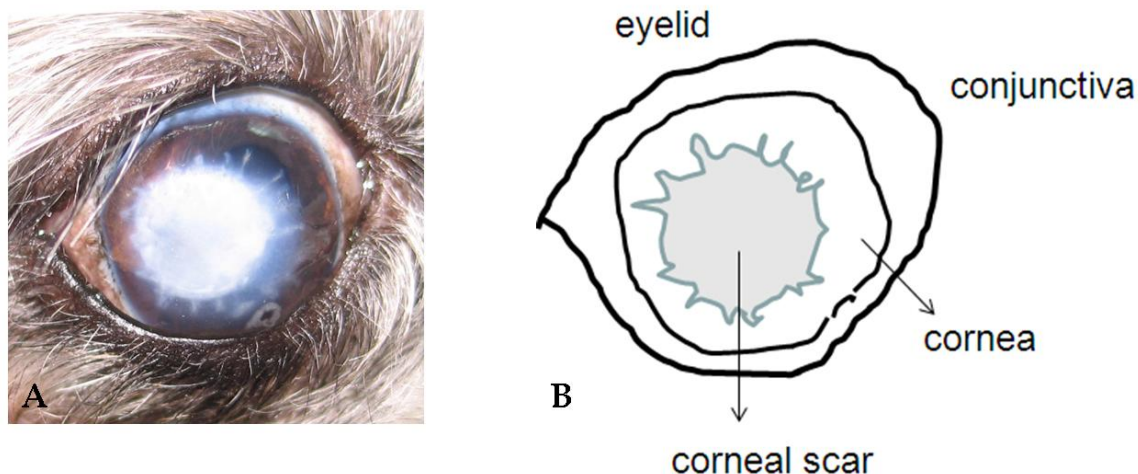
*(For better quality, figures can be viewed in the TJVM website)*

During a visit at one month after surgery, the owner concerned of a solid white lesion on the central cornea.

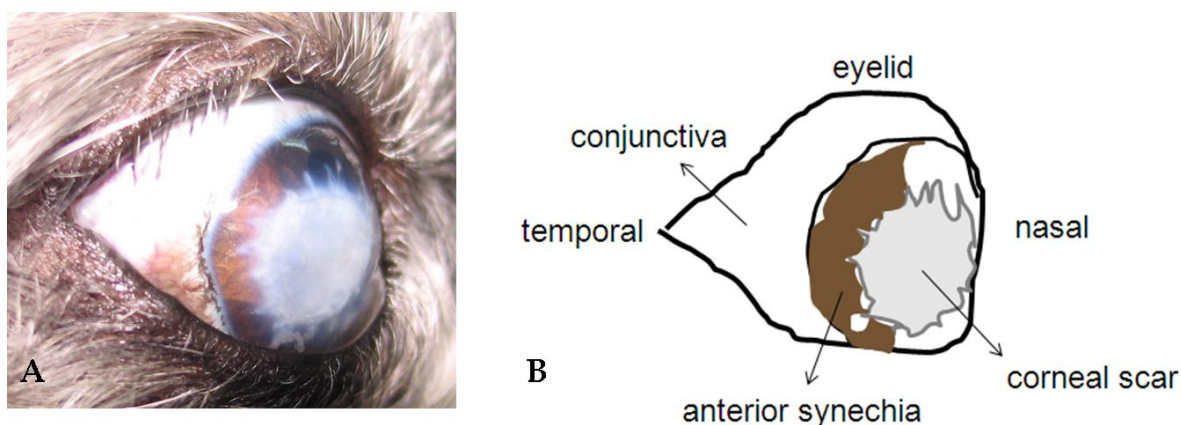
### **Question**

Give the diagnosis of that lesion and an explanation to the owner

Please turn to the next page for answers .....



**Figure 2** Front-viewed image of (a) an actual photograph and (b) a schematic drawing of the right eye, illustrating structures of the eye and corneal lesion.



**Figure 3** Temporal-viewed image of (a) an actual photograph and (b) a schematic drawing of the right eye, illustrating structures of the eye and lesions.

#### Answers

##### Ophthalmic diagnosis:

1. Corneal scarring (ocular surface)
2. Anterior synechia (an adhesion between iris and corneal endothelium)

**Explanation of solid white lesion on the cornea:** Scar formation occurs as a normal repairing mechanism after an injury of the corneal stroma. The deeper the corneal wound is, the more opaque the scar is. To improve transparency, topical corticosteroid can be used. However, corticosteroid has an effect to some extent.

##### Comments

The cornea is transparent because of its lattice organization of collagen fibrils. Deep corneal

defect involves several healing mechanisms including stromal edema, leukocytic migration, cell mitosis, fibroblast formation and stromal remodeling. Because new collagen fibrils are formed in a disorganized manner, it results in corneal opacification or scar. When fluorescein staining test is negatively confirmed (after surgical correction of the anterior staphyloma), topical corticosteroid could be administered to limit fibroblast formation, decrease corneal inflammation and finally improve corneal transparency.

##### References

Slatter, D. 2001. Cornea and Sclera. In: Fundamentals of Veterinary Ophthalmology. 3<sup>rd</sup> ed. Philadelphia: W.B. Saunders. 272.