

9-1-2010

## What is Your Diagnosis?

Pranee Tuntivanich

Suwicha Chuthateph

Follow this and additional works at: <https://digital.car.chula.ac.th/tjvm>



Part of the [Veterinary Medicine Commons](#)

---

### Recommended Citation

Tuntivanich, Pranee and Chuthateph, Suwicha (2010) "What is Your Diagnosis?," *The Thai Journal of Veterinary Medicine*: Vol. 40: Iss. 3, Article 19.

Available at: <https://digital.car.chula.ac.th/tjvm/vol40/iss3/19>

This Other is brought to you for free and open access by the Chulalongkorn Journal Online (CUJO) at Chula Digital Collections. It has been accepted for inclusion in The Thai Journal of Veterinary Medicine by an authorized editor of Chula Digital Collections. For more information, please contact [ChulaDC@car.chula.ac.th](mailto:ChulaDC@car.chula.ac.th).

## WHAT IS YOUR DIAGNOSIS

Pranee Tuntivanich Suwicha Chuthateph

### *Signalment*

A 10-year-old spayed female Domestic Short Hair cat.

### *History*

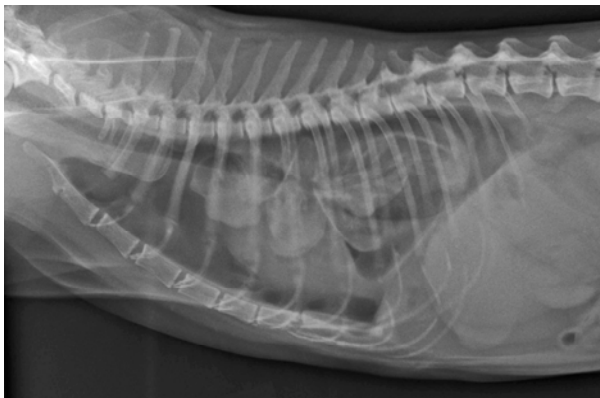The cat was presented with severe panting and abdominal breathing. Pleural effusion was revealed from survey radiographs and thoracocentesis was then performed (120 ml of mucopurulent exudates with large amount of debris cell content). Three weeks later, the cat showed an increased respiratory distress and 2<sup>nd</sup> thoracocentesis was performed (200 ml of mucopurulent exudate with small amount of blood content).

### *Clinical Examination*

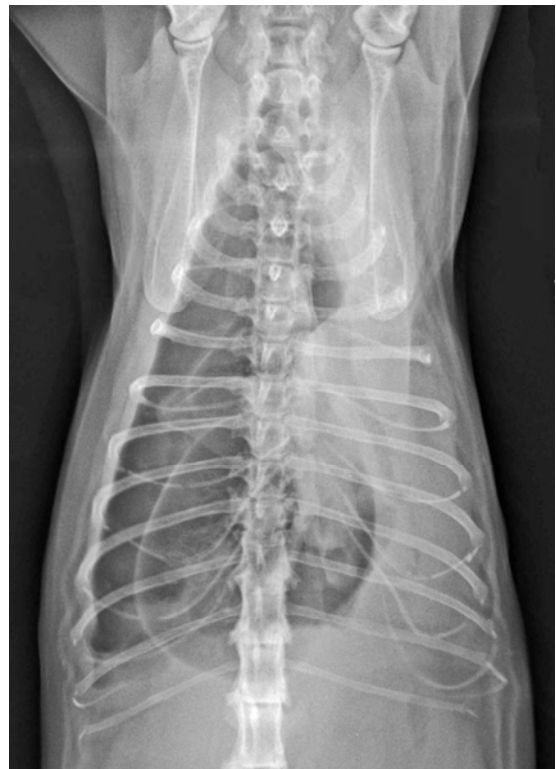The complete blood count showed a marked leukocytosis and thrombocytopenia. Numerous neutrophils and some macrophages were cytologically found from pleural fluid. Feline infectious peritonitis was the most suggestion from the pathology unit.

### *Radiographic Examination*

Plain right lateral and ventrodorsal thoracic radiographs were taken after 2<sup>nd</sup> thoracocentesis was performed to evaluate the remained pleural fluid and the other thoracic abnormalities.



**Figure 1** Right lateral thoracic radiograph

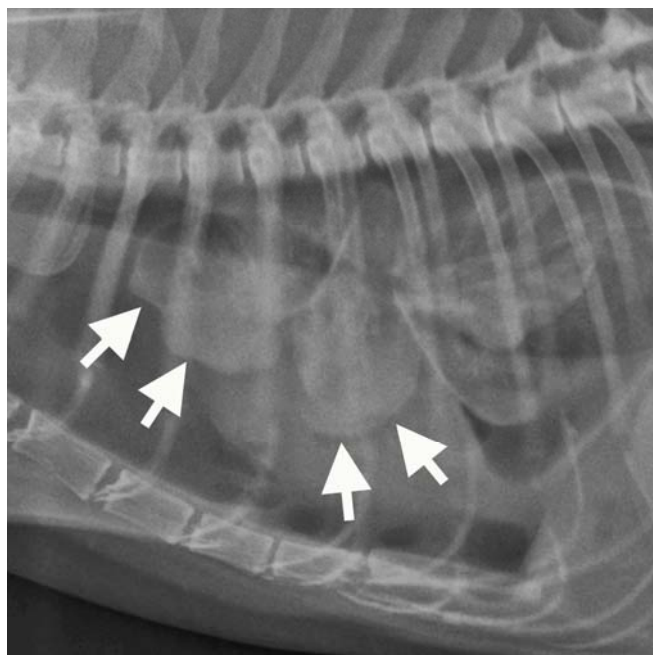


**Figure 2** Ventrodorsal thoracic radiograph

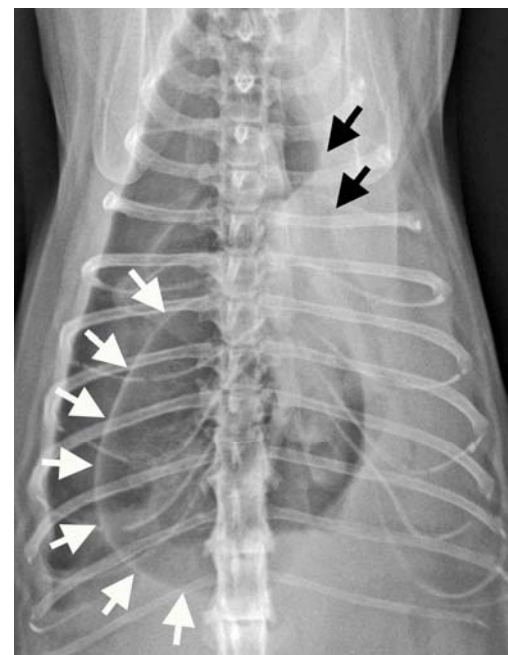
Give your diagnosis and turn to the next page.

### Radiographic findings

Right lateral thoracic radiograph (Figure 1) reveals a flat diaphragm appearance due to an expanded thoracic cage. Margins of the collapsed lungs are bumpy and round (Figure 3, white arrows). Ventrodorsal thoracic radiograph (Figure 2) shows an atelectasis of the left lung which represents the left shift of trachea and hilus (Figure 4, black arrows). On the left hemithorax, there is a large single air bronchogram surrounded by homogenous opaque atelectasis lung. The right hemithorax is filled with gas lucency (bronchovascular markings cannot be detected). There is a large oval-shaped structure in the caudodorsal thorax which appears to have a thin wall and is filled with gas, lung bulla (Figure 4, white arrows). Both radiographs reveal a border effacement of the cardiac silhouette and several poorly defined regions of soft tissue opacity considered to be mild to moderate pleural effusion.



**Figure 3** Bumpy and round- shaped collapsed lung lobes (arrows)



**Figure 4** Left shifted trachea/hilus and a bulla appearance (black arrows) and a lung bulla (white arrows)

### Radiographic diagnosis

Severe pulmonary emphysema with bulla formation and severe atelectasis of the lungs, mild pleural effusion and pneumothorax

### Discussion

This case is a chronic pulmonary disease that has restrictive lung atelectasis due to thickened pleura (pleuritis). So the aspirated fluid is replaced by air on the right side, pneumothorax. The air may leak in around the needle or diffuse from perforated lung due to a vacuum in the pleural space after fluid aspiration. The rounded right lung lobes could be affected by the chronic pleural effusion. Chronic atelectatic left lung with air bronchogram and mediastinal shift to the left may result from an adhesion of the left lung pleuritis with the left thoracic wall. For more certain of the diagnosis, both lateral projections and horizontal beam projections with the cat in right and left lateral recumbency (decubitus view) may be used to evaluate emphysema, free pleural gas, or pleural fluid.

### References

Farrow C.S. 1993. Disorders of the pleura and pleural cavity. The Thorax. In: Radiology of the Cat. St. Louis, Missouri: Mosby. 60- 69.