

The Thai Journal of Veterinary Medicine

Volume 40
Issue 3 September, 2010

Article 17

9-1-2010

Ophthalmology Snapshot

Nalinee Tuntivanich

Follow this and additional works at: <https://digital.car.chula.ac.th/tjvm>



Part of the [Veterinary Medicine Commons](#)

Recommended Citation

Tuntivanich, Nalinee (2010) "Ophthalmology Snapshot," *The Thai Journal of Veterinary Medicine*: Vol. 40: Iss. 3, Article 17.

Available at: <https://digital.car.chula.ac.th/tjvm/vol40/iss3/17>

This Other is brought to you for free and open access by the Chulalongkorn Journal Online (CUJO) at Chula Digital Collections. It has been accepted for inclusion in The Thai Journal of Veterinary Medicine by an authorized editor of Chula Digital Collections. For more information, please contact ChulaDC@car.chula.ac.th.

Ophthalmology Snapshot

Nalinee Tuntivanich

History

A 5 year-old female Pug was brought in by the owner to the Small Animal Teaching Hospital, Chulalongkorn University with a chief complaint of problematic eyesight in the past month. The dog is reluctant to walk during night time around the house particularly in dim light area. In addition the dog seems scared to step down stairs. The owner has noticed that the dog rubs in her face more often lately. Otherwise she is healthy without other physical complaints.

Summation of ophthalmic examinations:

Title	Right eye	Left eye
Menace response	+ mild	+ mild
STT	7	8
Ocular discharge	mucopurulent	mucopurulent
Cornea	lusterless, dark in color	lusterless, dark in color

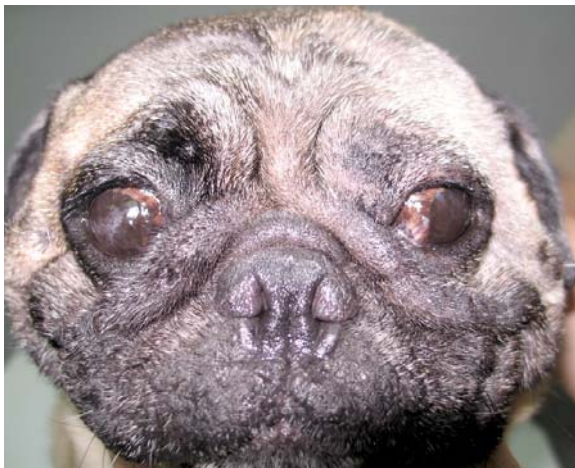

Figure 1. Photograph of this female Pug. (front view).

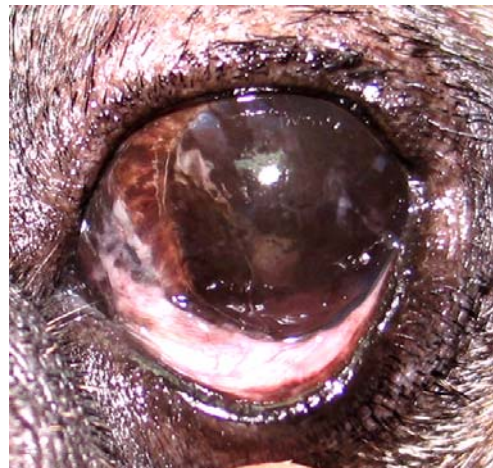

Figure 2. Photograph of the left eye of the same Pug from close ophthalmic examination.

(For better quality, figures can be viewed in the TJVM website)

Question

Give the diagnosis and possible treatments

Please turn to the next page for answers

Ophthalmology Clinic, Department of Surgery, Faculty of Veterinary Science, Chulalongkorn University, Bangkok 10330, Thailand

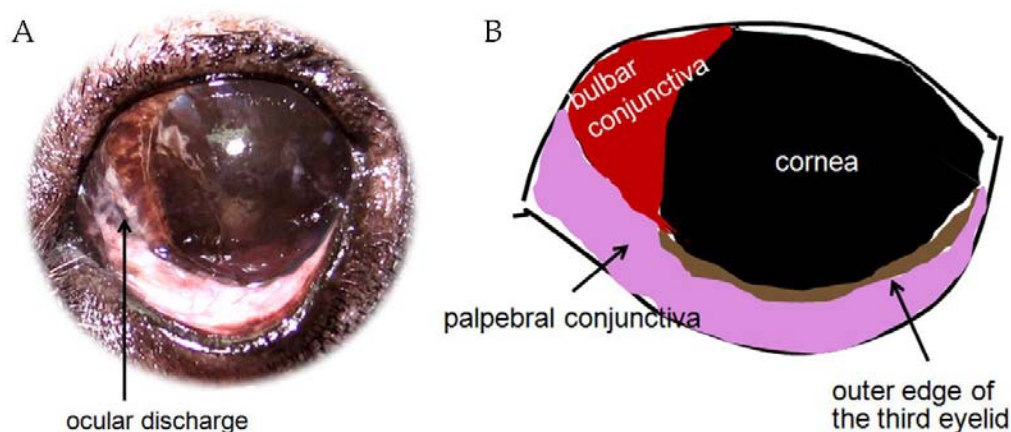


Figure 3. Photograph (A) and schematic diagram (B) of the left eye illustrating pigment covering an entire cornea and adjacent bulbar conjunctiva, slight palpebral conjunctivitis and mucopurulent ocular discharge near nasal canthus.

Answers

Ophthalmic diagnosis:

pigmentary keratitis, keratoconjunctivitis sicca, mild degree of nasal entropion

(Skin disorder on the face especially around the eyes and above the nose must be diagnosed and treated concurrently)

Possible treatments

- (1) Cause elimination: treatment of nasal entropion and skin disorder, control of immune-mediated response, avoidance of excessive eye exposure
- (2) Management of tear: tear stimulation, tear replacement
- (3) Control ocular surface infection: topical antimicrobial agents
- (4) Reduction of inflammation: anti-inflammatory drug
- (5) General management: eye cleansing, E. collar, avoidance of animal in dim light condition
- (6) Surgical removal of pigmentary keratitis

Comments

Chronic irritation is a common cause of pigmentary keratitis in dogs. Brachycephalic breeds such as Pug, French bulldog, Shih Tzu and Pekingese are prone to chronic corneal irritation due to

macropalpebral fissure. Other ocular abnormalities; eyelid position abnormality, abnormal hair growth and keratoconjunctivitis sicca (KCS) may also be associated with pigmentary keratitis. Treatment goal of pigmentary keratitis is to limit progression of pigmentation and correct underlying cause. In this case, SIT I readings are interpreted as moderate or mild KCS, tear secretion and tear supplementation should as well be promoted. In addition, topical corticosteroid in combination with broad spectrum antibiotics could be applied in order to control secondary bacterial infection causing inflammation on the ocular surface. Since heavy pigmentation on the cornea can obscure vision, surgical removal of pigment by lamellar keratectomy could be performed. However recurrence of pigment and corneal scar formation following keratectomy should bring into consideration.

References

- Gilger, B.C. 2007. Disease and surgery of the canine cornea and sclera. In: Veterinary Ophthalmology. 4th ed. K.N. Gelatt (ed.). Iowa: Blackwell Publishing. 721-722.