

8-1-1984

## The second case of Hymenolepis diminutain Thailand

Kasin Chanthachume

Medhi Kulkamthorn

Follow this and additional works at: <https://digital.car.chula.ac.th/clmjjournal>



Part of the [Medicine and Health Sciences Commons](#)

---

### Recommended Citation

Chanthachume, Kasin and Kulkamthorn, Medhi (1984) "The second case of Hymenolepis diminutain Thailand," *Chulalongkorn Medical Journal*: Vol. 28: Iss. 8, Article 9.

Available at: <https://digital.car.chula.ac.th/clmjjournal/vol28/iss8/9>

This Case Report is brought to you for free and open access by the Chulalongkorn Journal Online (CUJO) at Chula Digital Collections. It has been accepted for inclusion in Chulalongkorn Medical Journal by an authorized editor of Chula Digital Collections. For more information, please contact [ChulaDC@car.chula.ac.th](mailto:ChulaDC@car.chula.ac.th).

## The second case of *Hymenolepis diminuta* in Thailand

Kasin Chanthachume\*  
Medhi Kulkamthorn\*

เกสิน จันทชุม, เมธี กุลกำธร. รายงานผู้ป่วยโรคพยาธิ *Hymenolepis diminuta* รายที่สองของเมืองไทย. จุฬาลงกรณ์เวชสาร 2527 สิงหาคม; 28(8): 915-918

รายงานผลการตรวจอุจจาระผู้ป่วยเด็กหญิง อายุ 7 ปี จากจังหวัดศรีสะเกษ 1 ราย พบว่ามีไข่ของ *Hymenolepis diminuta* ซึ่งนับเป็นรายที่สองของเมืองไทย ผู้ป่วยได้รับการรักษาโดยให้ยา Niclosamide และ Magnesium sulphate หลังจากนั้นได้ตรวจพบตัวแก่ของ *Hymenolepis diminuta* ในอุจจาระผู้ป่วย

\* Department of Parasitology, Faculty of Medicine, Chulalongkorn University.

*Hymenolepis diminuta* was first recovered and described by Rudolphi in 1819. This tapeworm is a common and cosmopolitan intestinal parasite of rats and mice. The chief intermediate hosts are fleas, beetles and cockroaches. Man is incidental to continue propagation of the parasite. However, it has rarely been found in man. Human cases have been reported from India, U.S.S.R., Japan, Italy and United States of America (Faust and Russell, 1970).

The first human case in Thailand was a 20-month-old girl which was reported from Pramongkutklao Hospital. Three rat tapeworms (*Hymenolepis diminuta*) were found in the patient's stool six hours after medication (Chit-chang et al., 1978).

#### A case report

A 7 year-old Thai girl from Srisaket Province, was admitted to the Orthopedics ward, Chulalongkorn Hospital, on June 22, 1983, because of an exposure of metal wire at left elbow joint with oozing of purulent discharge.


She had been admitted to this hospital about 3 months earlier with a past history of falling from a tree two years ago, causing a fracture of left elbow joint. She was treated by a layman and resulting in stiffness of the left elbow joint, Diagnosis of old fracture and dislocation with malunion of left elbow joint was made and Osteotomy with realignment by K-wire has been performed. The affected part responded well to medical management and she went home after two months admission.

The physical examination on admission revealed a normal limit of movement of the left elbow joint except for an exposure of a metal wire with pus and inflammatory process. No abnormalities were found on examination of other systems. Laboratory findings showed haemoglobin of 10.6 gm%, white blood cell count 14,300 per c.mm. with 78% neutrophils, 3% eosinophils, 1% basophil and 18% lymphocytes. Urinalysis was negative.

An interesting finding was the presence of *Hymenolepis diminuta*'s eggs on stool examination, both by direct simple smear and concentration technic for 3 consecutive days.

Treatment : The patient was treated by removing K-wire, ampicillin 1 capsule q.i.d. ac. for 12 days. After the parasite's eggs were recovered from stool, she was given 3 tabs. Niclosamide and followed with 10 cc. Magnesium sulphate 2 hours later. The following morning, she passed a loose stool with 2 separated chains of immature, mature and gravid segments of tapeworm. Her condition looked well and discharged soon after clinical improvement and the stool was free of the parasite.

Description of the worm : A rat tapeworm (*Hymenolepis diminuta*) without the scolex was found in the patient's stool after medication. The worm measured 51.7 cm. in length (Fig 1). Immature and mature segments measured 0.3 mm. and 2 mm. in width respectively. The gravid segments measured 0.75 mm. in length by 2.5 in width. The worm was placed in a bottle half filled with normal saline and shook vigorously for 2 to 3 minutes. Then it

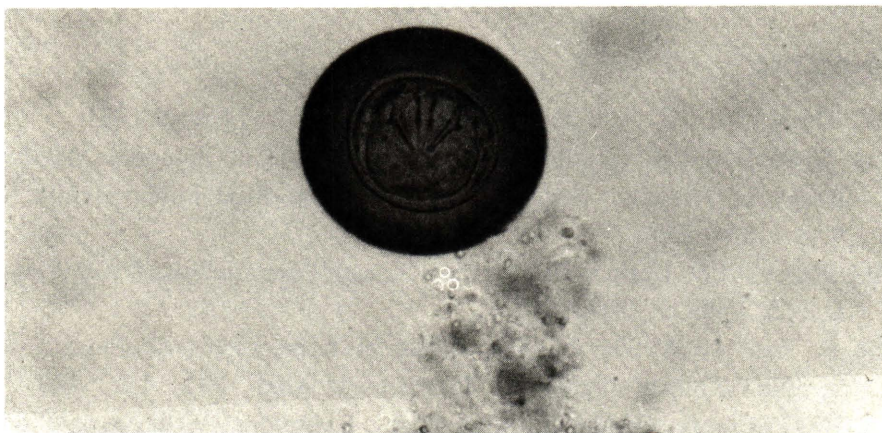

**Fig. 1** Adult worm of *Hymenolepis diminuta* obtained after treatment with niclosamide.

was fixed in 10% formalin. After fixation for 48 hours, mature segments were placed in 50% alcohol for 1 hour followed by 10 minutes in distilled water, and were stained in Semichon's acetic carmine. Gravid segments were washed in tap water and were gently pressed between two slides to flatten them. The gravid segments and mature segments were

examined under a microscope. Each mature segment possessed female and male genitalia with 3 conspicuous ovoidal testes. Gravid segments were found to be filled with a sacliked uterus containing numerous eggs.

The eggs measured about  $65 \times 63$  microns. They were slightly ovoid in shape and brown in color (Fig 2). The



**Fig. 2** Egg of *Hymenolepis diminuta* in stool specimen.

egg shell was relatively thick. In some specimens fine concentric striations were observed in the outer shell. The six lanceolate hooklets of the onchosphere were arranged in a fan-shaped pattern. The onchosphere was enclosed in a membrane which had no polar thickening and filaments.

### Discussion

The parasite *Hymenolepis diminuta* is most prevalent where sanitation is poor. It is occurring commonly in the tropics and subtropics. Human infections are associated chiefly with the contamination of cereals, grains and other foodstuffs by infected-grain beetles (Beck and Davies, 1981). According to McMillan, et al (1971) the worm is especially prevalent in children. As in this case, and the first one reported from Thailand the age of the patients were 7 year and 20 month-old respectively. Both of them lived in rural areas. Infection may due to poor habit of eating and sanitation as suggested by Beck and Davies (1981). The patient in this case had oftenly eaten rats from a paddyfield. Therefore, she might

accidentally get infection by ingesting infected fleas while catching or cooking the rats.

Examining the eggs from the patient's stool, we found that the onchosphere within the egg is surrounded by an inner shell membrane without knobs or polar filaments. These findings agree with the morphology of the eggs of *Hymenolepis diminuta* described by Najarian (1967) and Beck and Davies (1981).

### Summary

A human case of *Hymenolepis diminuta* infection is reported. The patient was a 7 year-old Thai girl from whom the eggs were found in the stool. After treatment with Niclosamide and Magnesium sulphate, 2 separated chains of immature, mature and gravid segments of tapeworm were found in the patient's stool.

### Acknowledgement

The authors wish to thank Dr. Watana Viroonchan for permission to report this case.

### Literatures Cited

- Beck JW, Davies JE. Medical Parasitology, 3 ed. C.V. Mosby, 1981
- Chitchang S, Sooksala N, Radomyos P. A case report of hymenolepos diminuta in Bangkok, Thailand. Southeast Asian J Trop Med Public Health 1978 Dec; 9(4) : 534-535
- Faust EC, Russell PF. Craig and Faust's Clinical Parasitology, 8 ed. Philadelphia : Lea & Febiger, 1970
- McMillan B, Kell A, Walker JC. Prevalence of hymenolepis diminuta infection in the New Guinea highlands. Trop Geogr Med 1971; 13 : 390
- Najarian HH. Textbook of Medical Parasitology. Baltimore: Williams & Wilkings, 1967